SUPERIOR COURT OF NEW JERSEY
BERGEN COUNTY
HON. CHARLES J. WALSH, J.S.C.
MASTER DOCKET NO.: BER-L-13379-04MT
IN RE: DIET DRUG LITIGATION

JANICE F. ADEYEMO v. WYETH, INC.
Docket No. BER-L-1396-04MT

CYNTHIA BARRETT v. WYETH, INC.
Docket No. BER-L-1418-04MT

JACK L. BLY v. WYETH, INC.
Docket No. BER-L-1644-04MT

MADELINE L. BROADWAY v. WYETH, INC.
Docket No. BER-L-1500-04MT

DAVID W. BURNETT v. WYETH, INC.
Docket No. BER-L-1390-04MT

WILLIAM F. BUSCH v. WYETH, INC.
Docket No. BER-L-1490-04MT

KIMBERLY L. CALLISON v. WYETH, INC.
Docket No. BER-L-1553-04MT

PAMELA CHUDYBA v. WYETH, INC.
Docket No. BER-L-2187-04MT

LAURANIA CID-CRUZ v. WYETH, INC.
Docket No. BER-L-1091-04MT

KELLI CRIDER v. WYETH, INC.
Docket No. BER-L-1956-04MT

NATHAN DAVIDSON v. WYETH, INC.
Docket No. BER-L-2454-04MT

CHRISTINE DiDODO v. WYETH, INC.

Docket No. BER-L-2489-04MT

CAROL DUFFEY v. WYETH, INC.
Docket No. BER-L-2437-04MT

NANCY EDER v. WYETH, INC.
Docket No. BER-L-2445-04MT

SHAUN EGBERT v. WYETH, INC.
Docket No. BER-L-2447-04MT

LAURA ESKE v. WYETH, INC.
Docket No. BER-L-2330-04MT

DONNA M. EVANS-BRIGGS v. WYETH, INC.
Docket No. BER-L-1374-04MT

KAREN FARINELLA v. WYETH, INC.
Docket No. BER-L-2463-04MT

CYNTHIA FEDORIK v. WYETH, INC.
Docket No. BER-L-1571-04MT

ROBERTA M. FEWS v. WYETH, INC.
Docket No. BER-L-1377-04MT

MARJORIE E. FILVER v. WYETH, INC.
Docket No. BER-L-1379-04MT

ZELLA FITLEBERG v. WYETH, INC.
Docket No. BER-L-2465-04MT

BERNICE FOLSOM v. WYETH, INC.
Docket No. BER-L-2477-04MT

DIANE FOSNOW v. WYETH, INC.
Docket No. BER-L-1904-04MT

KATHERINE GRAYSON v. WYETH, INC.
Docket No. BER-L-1893-04MT

LEONILDA I. HARRIOTT v. WYETH, INC.
Docket No. BER-L-1378-04MT

MARYLOU HATLEY v. WYETH, INC.
Docket No. BER-L-1532-04MT

LORETTA J. HAYES v. WYETH, INC.

Docket No. BER-L-1423-04MT

SHIRLEY A. HESS v. WYETH, INC.
Docket No. BER-L-1563-04MT

ROSIE HICKS v. WYETH, INC.
Docket No. BER-L-1887-04MT

BARBARA HINES v. WYETH, INC.
Docket No. BER-L-1632-04MT

RITA HOFEDITZ v. WYETH, INC.
Docket No. BER-L-1533-04MT

DALE KANE v. WYETH, INC.
Docket No. BER-L-1726-04MT

PATRICK B. KANE v. WYETH, INC.
Docket No. BER-L-1617-04MT

JOAN KENASTON v. WYETH, INC.
Docket No. BER-L-1425-04MT

DENNIS M. KILGALLON v. WYETH, INC.
Docket No. BER-L-1651-04MT

DORIS KING v. WYETH, INC.
Docket No. BER-L-1430-04MT

BOBBI JO C. LAPEE v. WYETH, INC.
Docket No. BER-L-1628-04MT

ELAINE E. LEE v. WYETH, INC.
Docket No. BER-L-1633-04MT

MICHAEL P. LOMBARDI v. WYETH, INC.
Docket No. BER-L-1569-04MT

REGINA K. McGOVERN v. WYETH, INC.
Docket No. BER-L-1570-04MT

KATHLEEN E. McLAUGHLIN v. WYETH, INC.
Docket No. BER-L-1682-04MT

UNICE McREYNOLDS v. WYETH, INC.
Docket No. BER-L-1681-04MT

AUDREY D. MELVIN v. WYETH, INC.
Docket No. BER-L-1382-04MT

DEBRA MESSER v. WYETH, INC.
Docket No. BER-L-1426-04MT

ADRIANNE A. ORNELAS v. WYETH, INC.
Docket No. BER-L-1443-04MT

DOROTHY ORTIZ-GWITT v. WYETH, INC.
Docket No. BER-L-1444-04MT

REBECCA OWENS v. WYETH, INC.
Docket No. BER-L-1446-04MT

KENNETH D. PATRICK v. WYETH, INC.
Docket No. BER-L-1416-04MT

MICHELE R. PINTO v. WYETH, INC.
Docket No. BER-L-1748-04MT

SHEILA J. POLLOCK v. WYETH, INC.
Docket No. BER-L-1424-04MT

ASIA PURVIS v. WYETH, INC.
Docket No. BER-L-1461-04MT

MAUREEN J. REAGAN v. WYETH, INC.
Docket No. BER-L-1457-04MT

MILDRED RIVERA v. WYETH, INC.
Docket No. BER-L-1384-04MT

ANGELA RIVERS v. WYETH, INC.
Docket No. BER-L-1388-04MT

SHEILA L. ROUFF v. WYETH, INC.
Docket No. BER-L-1097-04MT

KATHY E. RYAN v. WYETH, INC.
Docket No. BER-L-1411-04MT

THOMAS SCORSONE v. WYETH, INC.
Docket No. BER-L-1389-04MT

NATHAN SHAMOSH v. WYETH, INC.
Docket No. BER-L-1391-04MT

MICHAEL J. SHEEHY v. WYETH, INC.
Docket No. BER-L-1745-04MT

FRANCES SHEPHERD v. WYETH, INC.
Docket No. BER-L-2311-04MT

CAMILLE B. SNOKE v. WYETH, INC.
Docket No. BER-L-2298-04MT

FRANCES SULSER v. WYTH, INC.
Docket No. BER-L-2294-04MT

JESSICA M. TALBOT-JAKUBOWSKI v. WYETH, INC.
Docket No. BER-L-1542-04MT

ANDREA TURNER v. WYETH, INC.
Docket No. BER-L-1493-04MT

JANET E. VAVRA v. WYETH, INC.
Docket No. BER-L-1555-04MT

BARBARA A. WALTERS v. WYETH, INC.
Docket No. BER-L-1734-04MT

ZANDRA M. WATLEY v. WYETH, INC.
Docket No. BER-L-1090-04MT

TERI M. WEAVER-KENNEDY v. WYETH, INC.
Docket No. BER-L-1551-04MT

PAULA K. WILLIAMS v. WYETH, INC.
Docket No. BER-L-2299-04MT

DAWN M. YOUNG v. WYETH, INC.
Docket No. BER-L-1479-04MT

APPLICATIONS CHALLENGING ELIGIBILITY TO EXERCISE OPT-OUTS FROM NATIONWIDE CLASS ACTION SETTLEMENT

MOVANT: WYETH CORPORATION

MOVANT'S ATTORNEYS: PORZIO, BROMBERG & NEWMAN (ANITA HOTCHKISS, ESQ. AND DANIEL K. WINTERS, ESQ. APPEARING), ARNOLD & PORTER (ANAND AGNESHWAR, ESQ. AND CARA PETERSON, ESQ. APPEARING), MITCHELL, McNUTT & SAMS (JOHN G. WHEELER, ESQ. APPEARING), GHOLSON & ORR (ROBERT D. GHOLSON, ESQ. APPEARING), RAMSEY & HAMMOND (J. ROBERT RAMSAY, ESQ APPEARING).

OPPONENTS: JANICE F. ADEYEMO, CYNTHIA BARRETT, JACK L. BLY, MADELINE L. BROADWAY, DAVID W. BURNETT, WILLIAM F. BUSCH, KIMBERLY L. CALLISON, PAMELA CHUDYBA, LAURANIA CID-CRUZ, KELLI CRIDER, NATHAN DAVIDSON, CHRISTINE DiDODO, CAROL DUFFEY, NANCY EDER, SHAUN EGBERT, LAURA ESKE, DONNA M. EVANS-BRIGGS, KAREN FARINELLA, CYNTHIA FEDORIK, ROBERTA M. FEWS, MARJORIE E. FILVER, ZELLA FITLEBERG, BERNICE FOLSOM, DIANE FOSNOW, KATHERINE GRAYSON, LEONILDA I. HARRIOTT, MARYLOU HATLEY, LORETTA J. HAYES, SHIRLEY A. HESS, ROSIE HICKS, BARBARA HINES, RITA HOFEDITZ, DALE KANE, PATRICK B. KANE, JOAN KENASTON, DENNIS M. KILGALLON, DORIS KING, BOBBI JO C. LAPEE, ELAINE E. LEE, MICHAEL P. LOMBARDI, REGINA K. McGOVERN, KATHLEEN E. McLAUGHLIN, UNICE McREYNOLDS, AUDREY D. MELVIN, DEBRA MESSER, ADRIANNE A. ORNELAS, DOROTHY ORTIZ-GWITT, REBECCA OWENS, KENNETH D. PATRICK, MICHELE R. PINTO, SHEILA J. POLLOCK, ASIA PURVIS, MAUREEN J. REAGAN, MILDRED RIVERA, ANGELA RIVERS, SHEILA L. ROUFF, KATHY E. RYAN, THOMAS SCORSONE, NATHAN SHAMOSH, MICHAEL J. SHEEHY, FRANCES SHEPHERD, CAMILLE B. SNOKE, FRANCES SULSER, JESSICA M. TALBOT-JAKUBOWSKI, ANDREA TURNER, JANET E. VAVRA, BARBARA A. WALTERS, ZANDRA M. WATLEY, TERI M. WEAVER-KENNEDY, PAULA K. WILLIAMS, DAWN M. YOUNG.

OPPONENTS' ATTORNEYS: NAPOLI, KAISER, BERN & ASSOC. (PAUL NAPOLI, ESQ. AND CHRIS LoPALO, ESQ. APPEARING), HARITON & D'ANGELO (MARIO D'ANGELO, ESQ. APPEARING), WILLIAMS BAILEY

LAW FIRM (AVRAM J. BLAIR, ESQ. APPEARING), BLIZZARD, McCARTHY & NABERS, LLP (J. SCOTT NABERS, ESQ. APPEARING).

HEARINGS: YES

LETTER OPINION: FEBRUARY 24, 2005

This matter is before the Court on applications by Wyeth Corporation, as the successor to American Home Products Corporation ("AHP") and each of its former subsidiaries, affiliates and divisions (collectively "Wyeth" or "defendants") challenging the eligibility of seventy-one (71) plaintiffs to exercise opt-outs from the Nationwide Class Action Settlement ("CAS"). These plaintiffs are: Janice F. Adeyemo ("Adeyemo"); Cynthia Barrett ("Barrett"); Jack L. Bly ("Bly"); Madeline L. Broadway ("Broadway"); David W. Burnett ("Burnett"); William F. Busch ("Busch"); Kimberly L. Callison ("Callison"); Pamela Chudyba ("Chudyba"); Laurania M. Cid-Cruz ("Cid-Cruz"); Kelli Crider ("Crider"); Nathan Davidson ("Davidson"); Christine DiDodo ("DiDodo"); Carol Duffey ("Duffey"); Nancy Eder ("Eder"); Shaun Egbert ("Egbert"); Laura Eske ("Eske"); Donna M. Evans-Briggs ("Evans-Briggs"); Karen Farinella ("Farinella"); Cynthia Fedorik ("Fedorik"); Roberta M. Fews ("Fews"); Marjorie E. Filver ("Filver"); Zella Fitleberg ("Fitleberg"); Bernice Folsom ("Folsom"); Diane Fosnow ("Fosnow"); Katherine Grayson ("Grayson"); Leonilda I. Harriott ("Harriott"); Marylou Hatley ("Hatley"); Loretta J. Hayes ("Hayes"); Shirley A. Hess ("Hess"); Rosie Hicks ("Hicks"); Barbara Hines ("Hines"); Rita Hofeditz ("Hofeditz"); Dale Kane ("D. Kane"); Patrick B. Kane ("P. Kane"); Joan Kenaston ("Kenaston"); Dennis M. Kilgallon ("Kilgallon"); Doris King ("King"); Bobbi Jo C. Lapee ("Lapee"); Elaine E. Lee ("Lee"); Michael P. Lombardi ("Lombardi"); Regina K. McGovern ("McGovern"); Kathleen E. McLaughlin ("McLaughlin"); Unice McReynolds ("McReynolds"); Audrey D. Melvin ("Melvin"); Debra Messer ("Messer"); Adrianne A. Ornelas ("Ornelas"); Dorothy Ortiz-Gwitt ("Ortiz-Gwitt"); Rebecca Owens ("Owens"); Kenneth D. Patrick ("Patrick"); Michele R. Pinto ("Pinto"); Sheila J. Pollock ("Pollock"); Asia Purvis ("Purvis"); Maureen J. Reagan ("Reagan"); Mildred Rivera ("Rivera"); Angela Rivers ("Rivers"); Sheila L. Rouff ("Rouff"); Kathy E. Ryan ("Ryan"); Thomas Scorsone ("Scorsone"); Nathan Shamosh ("Shamosh"); Michael J. Sheehy ("Sheehy"); Frances Shepherd ("Shepherd"); Camille B. Snoke ("Snoke"); Frances Sulser ("Sulser"); Jessica M. Talbot-Jakubowski ("Talbot-Jakubowski"); Andrea Turner ("Turner"); Janet E. Vavra ("Vavra); Barbara A. Walters ("Walters"); Zandra M. Watley ("Watley"); Teri M. Weaver-Kennedy ("Weaver-Kennedy"); Paula K. Williams ("Williams"); and Dawn M. Young ("Young").

The Court conducted its fourth evidentiary hearing on Wyeth's challenges which began on January 31, 2005 and concluded on February 14, 2005. During that period, the Court heard testimony or considered depositions given by: Martin E. Goldman, M.D. ("Dr. Goldman"); Charles Gibbs Vasey, M.D. ("Dr. Vasey"); Sanjiv Kaul, M.D. ("Dr. Kaul"); Jason Lazar, M.D. ("Dr. Lazar"); Muhamed Saric, M.D. PhD ("Dr. Saric"); Mark V. Sherrid, M.D. ("Dr. Sherrid"); Arthur Millman, M.D. ("Dr. Millman"); William F. Lassetter, M.D. ("Dr. Lassetter"); Howard Cohen, M.D. ("Dr. H. Cohen"); Roger A. Billhardt, M.D. ("Dr. Billhardt"); James Colasacco, M.D. ("Dr. Colasacco"); Chunguang Chen, M.D. ("Dr. Chen"); Peter S. Rahko, M.D. ("Dr. Rahko"); Aasha S. Gopal, M.D. ("Dr. Gopal"); Kenneth Ong, M.D. ("Dr. Ong"); Michael Jason, M.D. ("Jason"); Neal Ruggie, M.D. ("Dr. Ruggie"); Bruce Charash, M.D. ("Dr. Charash"); S. Curtis Burnett, M.D. ("Dr. Burnett"); Charles Dahl, M.D. ("Dr. Dahl"); Jeffrey G. Schwartz, M.D. ("Dr. Schwartz"); Nino D. Marino, M.D. ("Dr. Marino"); Shunichi Homma, M.D. ("Dr. Homma"); Michael H. Crawford, M.D. ("Dr. Crawford"); and Louis Evan Teichholz, M.D. ("Dr. Teichholz"); all of whom were cardiologists. The Court also considered the testimony of Frank Miele ("Miele"), an engineer and physicist, given during the first two (2) eligibility hearings. Much of the direct testimony of each of these witnesses was presented through affidavits, certifications or reports which were adopted during the course of the evidentiary hearing. In addition, the Court considered the contents of several treatises which were recognized in the proceedings as reliable under **N.J.R. EVID.** 803 (c)(18), including: Harvey Feigenbaum, **ECHOCARDIOGRAPHY** (5th Ed. 1994) ("Feigenbaum Text"); Arthur Weyman, **PRINCIPLES AND PRACTICES OF ECHOCARDIOGRAPHY** (2nd Ed. 1994) ("Weyman Text"); Novin C. Nanda, **ATLAS OF COLOR DOPPLER ECHOCARDIOGRAPHY** (1989); J.P. Singh, et al., *Prevalence and Clinical Determinants of Mitral, Tricuspid, and Aortic Regurgitation (The Framingham Heart Study),* 83 *Am. J. Cardiology* (1999) ("Singh"); and *The Task Force on Valvular Regurgitation Recommendation for Evaluation of the Severity of Native Valvular Regurgitation with Two-dimensional and Doppler Echocardiography ("ASE Standards"), J. Am. Soc. Echocardiography,* 16: 777 (2003).

The Court previously discussed the standards to be used in assessing these eligibility challenges. *In Re: Diet Drug Litigation*, BER-L-7718-03 (Law Division April 13, 2004) ("*Eligibility Standards Opinion*") (slip op. at 31-36). Each plaintiff seeking to exercise an intermediate opt-out ("IOO") or back end opt-out ("BEOO") is required by the CAS to establish that he or she is FDA Positive by a qualifying echocardiogram. FDA Positive, as defined, contains two (2) standards.

First, the quantitative measurements that constitute FDA Positive heart valve regurgitation are as follows:

> Aortic Valve – Mild or greater regurgitation, defined as regurgitant jet diameter in the parasternal long-axis view (or in the apical long-axis view, if the parasternal long-axis view is unavailable), equal to or greater than ten percent (10%) of the outflow tract diameter (JH/LVOT).
>
> Mitral Valve – Moderate or greater regurgitation, defined as regurgitant jet area in any apical view equal to or greater than twenty percent (20%) of the left atrial area (RJA/LAA).

CAS § I.22.b. The CAS also requires that specific criteria be used in determining whether these levels of valvular regurgitation are present. Singh at 897-98.

Second, the CAS requires the echocardiograms be performed and evaluated by "qualified medical personnel" in accordance with the methodology set forth in two (2) referenced texts – the Feigenbaum Text and the Weyman Text. *Eligibility Standards Opinion* (slip op. at 12-16).

This Court already has determined that "Wyeth [may] disqualify an IOO or BEOO if it establishes that the performance and/or evaluation of the echocardiogram (at issue) was medically unreasonable as a matter of law. Stated another way, Wyeth "[may] . . . disqualify . . . [an] IOO or BEOO if it can show that . . . [an] expert's conclusions respecting the echocardiogram supporting the opt-out could not 'reliably flow from the facts known to the expert and the methodology used.'" *Eligibility Standards Opinion* (slip op. at 31) (citations omitted).

For the reasons which follow, the Court finds that Wyeth has satisfied the Court that the echocardiograms supporting claims of plaintiffs: Janice F. Adeyemo, Cynthia Barrett, Jack L. Bly, Madeline L. Broadway, David W. Burnett, Kimberly L. Callison, Pamela Chudyba, Laurania M. Cid-Cruz, Kelli Crider, Nathan Davidson, Christine DiDodo, Nancy Eder, Shaun Egbert, Donna M. Evans-Briggs, Cynthia Fedorik, Roberta M. Fews, Diane Fosnow, Katherine Grayson, Leonilda I. Harriott, Marylou Hatley, Loretta J. Hayes, Shirley A. Hess, Rosie Hicks, Barbara Hines, Rita Hofeditz, Dale Kane, Patrick B. Kane, Joan Kenaston,

Dennis M. Kilgallon, Doris King, Bobbi Jo C. Lapee, Elaine E. Lee, Michael P. Lombardi, Regina K. McGovern, Kathleen E. McLaughlin, Unice McReynolds, Audrey D. Melvin, Debra Messer, Adrianne A. Ornelas, Dorothy Ortiz-Gwitt, Rebecca Owens, Kenneth D. Patrick, Michele R. Pinto, Asia Purvis, Maureen J. Reagan, Mildred Rivera, Angela Rivers, Sheila L. Rouff, Kathy E. Ryan, Thomas Scorsone, Nathan Shamosh, Michael J. Sheehy, Frances Shepherd, Camille B. Snoke, Frances Sulser, Jessica M. Talbot-Jakubowski, Andrea Turner, Janet E. Vavra, Barbara A. Walters, Zandra M. Watley, Teri M. Weaver-Kennedy, Paula K. Williams, and Dawn M. Young have not been performed and/or interpreted in a medically reasonable manner. Accordingly, the Complaints filed by these plaintiffs are dismissed and those plaintiffs are returned to the Class. The Court, however, finds that Wyeth has failed to support its eligibility challenge as to plaintiffs: William F. Busch, Carol Duffey, Laura Eske, Karen Farinella, Marjorie E. Filver, Zella Fitleberg, Bernice Folsom and Sheila J. Pollock. Accordingly, Wyeth's motion to dismiss will be denied as to them. The findings of fact and conclusions of law supporting these determinations are reported below.

I

A.

In order to determine whether Wyeth's challenges have merit, one has to understand the underlying medical conditions claimed by these plaintiffs and the tools used to detect and treat those conditions. Mild aortic and moderate mitral regurgitation are the two (2) medical conditions that permit either an IOO or BEOO. These conditions involve the backward or reverse flow of blood through defective valves during the heart's pumping cycle.

The heart consists of four (4) chambers: the right atrium, the right ventricle, the left atrium and the left ventricle. The right atrium receives deoxygenated blood from the body and ejects that blood into the right ventricle through the tricuspid valve; the right ventricle then pumps that blood across the lungs through the pulmonic or pulmonary valve for oxygenation. The oxygenated blood, in turn, is received by the left atrium, which ejects blood into the left ventricle through the mitral valve. The left ventricle then pumps that oxygenated blood into the aorta through the aortic valve, and from there to the rest of the body. The heart chambers are connected by valves that open to allow blood to pass through and then close to prevent significant backflow. This process ensures the proper directional flow of blood through the heart.

The chambers of the heart fill and empty in a two-phase cardiac cycle that comprises diastole - - the filling cycle, and systole - - the emptying cycle. For our purposes, we are concerned with the active contraction of the left ventricle and pumping of blood into the aorta through the open aortic valve during systole. Throughout this phase the mitral valve is closed to prevent backward flow or regurgitation from the left ventricle into the left atrium. We are also interested in the other phase of the cardiac cycle -- diastole -- which occurs when blood enters the left ventricle through the open mitral valve. During this phase the aortic valve is closed to prevent leakage or regurgitation from the aorta back into the left ventricle.

Healthy heart valves rarely prevent all regurgitation. When these valves are closed there may be a minimal amount of leakage -- trace regurgitation. Moreover, during routine valve closure, blood caught between the valve leaflets is displaced backward resulting in some blood backflow. This backward displacement of blood is considered part of the closing process, and is not regurgitation. According to Weyman, "true" mitral regurgitation "should last throughout most or all of systole." Weyman Text at 429. A brief or non-sustained jet of mitral regurgitation is an indication that the regurgitation is usually less than mild. The same source teaches that "true" aortic regurgitation should continue "throughout diastole." *Id.* at 529. Aortic regurgitation that is brief or non-sustained is usually less than mild.

Normally blood flows at a uniform velocity in a forward direction. This normal blood flow is laminar. Regurgitant flow, on the other hand, produces a jet of mixed velocities which is turbulent. It is this turbulent flow which is one of the focuses of echocardiography.

According to Singh, the degree of valvular regurgitation or valvular insufficiency is classified as trace, mild, moderate, or severe. Trace aortic regurgitation and trace and mild mitral regurgitation are common in the general population and are considered normal findings. Singh at 900.

B.

Echocardiography is a principal technique used to evaluate the heart, including its function, structure and the flow of blood through it. The underlying principle involved in echocardiography is the use of high frequency sound waves. A transducer is placed on the patient's chest wall which emits sound waves that bounce off of the heart's structures, and that information is translated into moving images of those structures on a screen. There are several different techniques

available in echocardiography. The technique relevant here is Doppler echocardiography. "Doppler echocardiography is based on the change in frequency of a sound wave that occurs when it strikes a moving target – in this case the red blood cells." Weyman Text at 143.

Color flow Doppler is used to display the movement of blood flow through the heart by assigning different colors depending upon the direction and velocity of the blood flow. By convention, laminar blood flowing towards the transducer is depicted in shades of red, and laminar blood flowing away from the transducer is depicted in shades of blue; darker shades indicating slower velocity and lighter shades higher velocity. *See* Feigenbaum Text at 33. Turbulent blood flow is depicted in a "mosaic," multi-colored pattern, thus displaying the different velocities and directions of the blood in the area under study. The absence of blood flow is depicted by black on color flow Doppler. Thus, in Doppler echocardiography blood flow is represented as discrete color areas (jets) in real time, superimposed on two-dimensional images of the heart's structure.

The quality of an echocardiogram depends on a number of factors including: the patient's body; the technical skill of the physician or sonographer performing the study; the equipment used and its settings; and, the physician's interpretation and measurements. The proper performance of an echocardiogram in the cases before this Court must follow the guidelines set forth in the Weyman and Feigenbaum Texts.

Settings on the echocardiographic equipment can have a substantial impact on the quality of the images and the accuracy of the recordings. Two (2) key settings on the equipment are referred to as the Nyquist limit and gain setting. The Nyquist limit establishes the maximum velocity of laminar blood flow that can be detected in a monochromatic fashion (solid color).[1] When the velocity of the blood flow exceeds the pre-set Nyquist limit the color depicting the blood flow "wraps around" so that if the flow is laminar it appears to be flowing in the opposite direction. Turbulent blood flow in such circumstances appears as a "mosaic,"

---

[1] As the Feigenbaum Text at 29 notes:

> The major disadvantages of pulsed Doppler is that the velocity one can measure is limited. The pulsed system inherently has a pulsed repetition frequency or PRF. The PRF determines how high a Doppler frequency the pulse system can detect…. The inability of a pulsed Doppler system to detect high–frequency Doppler shifts is known as "aliasing." The upper limit of frequency that can be detected with a given pulsed system is known as the "Nyquist" limit or number. This limit is defined as one half the pulse repetition frequency or PRF.

See Miele Certification at ¶¶ 16, 17, 31 and 32.

multi-colored pattern. If the Nyquist limit is set too low, the velocity of normal blood flow may exceed a low Nyquist setting and will appear as turbulent regurgitation, even though it is actually normal non-regurgitant flow. Additionally, when the Nyquist limit is set too low it will exaggerate the degree of any regurgitation present by including normal blood flow velocity in the turbulent regurgitant jet area. Virtually all the experts who testified here agree that a higher Nyquist limit generally leads to a more reliable echocardiogram. A recent consensus report by the American Society of Echocardiography stressed the importance of an appropriate Nyquist limit.

> Numerous technical, physiologic and anatomic factors affect the size of the regurgitant area and therefore alter its accuracy as an index of regurgitation severity. Jet size is affected by instrument factors, especially pulse repetition frequency (PRF) and color gain. Standard technique is to use a Nyquist limit (aliasing velocity) of 50/60 cm/sec, and a color gain that just eliminates random color speckle from non-moving regions. Jet area is inversely proportional to PRF, and *substantial error can be introduced with use of higher or lower settings* than the nominal settings to which echocardiographers have become accustomed.

ASE Standards at 777-778 (emphasis added).

A color Doppler gain setting is another important variable in the echocardiographic system. If the gain on echocardiographic equipment is set too high, the image may be artificially increased and may also present "background noise" or "speckling," seriously degrading the quality of the echocardiogram and making it difficult to assess true regurgitation. Weyman Text at 240-241 and 258. As Weyman teaches, the "detection of the Doppler frequency shift is critically dependent on the signal/noise ratio, and every effort must be made to maximize this relationship." Weyman Text at 256. To do so, Weyman suggests that:

> Ideally, as in imaging studies, one begins with a high gain setting to be sure that all of the signal present is appreciated. The gain is then gradually decreased to a point where the signal is optimally displayed and the associated noise and mirroring artifacts … are at a minimum.

Weyman Text at 258.

Two (2) dimensional or 2-D gain settings are also significant. The 2-D gain is important in acquiring and displaying cardiac structures such as the left atrium and ventricle. If the 2-D gain is set too high, these cardiac structures are obscured as the display takes on an appearance of a snow storm. Obviously, this can be quite significant when one must trace the left atrial area in making the area measurements required by the CAS.

Another important technical aspect of echocardiographic acquisition relates to the angle the transducer is placed relative to the heart when images are recorded. If those images are not acquired in the appropriate angle or plane, the amount of regurgitation and the sizes of the chambers of the heart may appear larger or smaller than they really are. Again, Weyman teaches that "doppler frequency shifts are maximal when the sound beam is parallel to the flow vector (*i.e.*, aligned parallel to the path of blood flow in the vessel of interest).… The Doppler beam, therefore, is ideally aligned parallel, rather than perpendicular, to flow because larger frequency shifts are easier to detect and the output is less subject to random fluctuation." Weyman Text at 256.

FDA Positive heart valve regurgitation involving the aortic valve requires that two (2) measurements be made: (1) the height of the jet of aortic regurgitation

("JH"); and (2) the height of the left ventricular outflow tract ("LVOT").[2] The JH measurement is the linear width of the jet of aortic regurgitation as it leaks backward into the left ventricle. Feigenbaum tells us that this measurement must be made as close as possible to the point of origin of that jet on the ventricular side of the aortic valve. Feigenbaum Text at 283. Otherwise, the measurement will be exaggerated by the spray or "nozzle effect" that occurs when high velocity liquid (regurgitant blood) is ejected through a narrow orifice into a lower pressure chamber (the left ventricle in diastole). *Id.* at 283. The LVOT is the region of the left ventricle below the aortic valve. These two (2) measurements are then expressed as a ratio, JH/LVOT. Current technology utilizes digitally calibrated calipers or cursors, which can measure the linear width of the JH and LVOT on a frozen frame or image using a digitally calibrated caliper or cursor, from commercially available software packages.

The definition of FDA Positive mitral regurgitation also requires two (2) measurements to be made: (1) the regurgitant jet area, or "RJA"; and (2) the left atrial area, or "LAA." Unlike the linear width measurements made of the JH and LVOT, the RJA and LAA are area measurements. Again these measurements are expressed as a ratio, RJA/LAA, in assessing the degree of mitral regurgitation. These measurements of the RJA and LAA can be done while the sonographer is

[2] The same diagram illustrating how this measurement is actually made is displayed in the Feigenbaum Text at 285, Fig. 6-101, and the Weyman Text at 534. The illustration as it appears in Weyman is reproduced below.

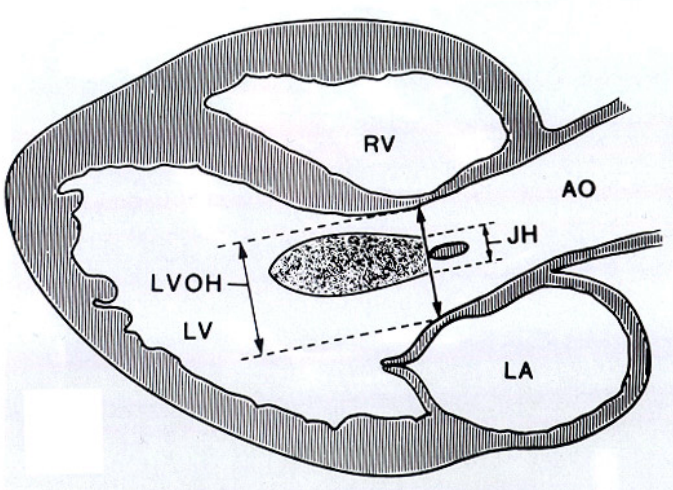

Fig. 19–61. The measurement of regurgitant jet height. Regurgitant jet height (JH) is measured at the aortic valve level in the parasternal long axis view. AO = aorta; LA = left atrium; LV = left ventricle; LVOH = left ventricular outflow tract height; RV = right ventricle. (From Perry GJ, et al.: Evaluation of aortic insufficiency by Doppler color flow mapping. J Am Coll Cardiol 9:952, 1987. Reprinted with permission from the American College of Cardiology.

acquiring the study, or off-line, and are referred to as tracings or planimetry when using the technology just described.

II

A.

The Court considered the qualifications of the experts as required by **N.J.R. EVID.** 702. *Kemp ex rel Wright v. State*, 174 N.J. 412, 427 (2002). Overall, the Court found the experts called by Wyeth and the plaintiffs to be well qualified, or at least qualified, in the areas offered.

The Court finds Drs. Goldman, Kaul, Chen, Teichholz, Vasey, Schwartz, Marino, Homma and Crawford well qualified in the field of echocardiography. Dr. Goldman is a Professor of Medicine at the Mt. Sinai School of Medicine in New York and has taught at that medical school for over twenty (20) years. Dr. Goldman has written extensively in the field of echocardiology and holds positions as a director of the American Society of Echocardiography ("ASE"), one of the bodies seeking to promote advances in the field of echocardiography, as well as several of its committees. He is the immediate past President of the New York Echocardiography Society. Dr. Kaul is currently a Professor of Medicine and Biomedical Engineering at the University of Virginia where he holds an endowed chair. He also is the Director of the Cardiovascular Imaging Center at the same institution. Dr. Kaul has published extensively, has held numerous editorial board positions at leading cardiology journals in the United States and has been a board member of the ASE. Dr. Chen is a Clinical Professor of Medicine at the Mt. Sinai School of Medicine in New York and is the Director of Cardiac Non-Invasive Laboratory at the Newark Beth Israel Medical Center. He has published extensively in the field of echocardiography and is a Level III echocardiographer. Dr. Teichholz is currently the Chief of the Division of Cardiology in the Department of Internal Medicine and the Medical Director of Cardiac Services at the Hackensack University Medical Center. He is presently a Professor of Medicine at the University of Medicine and Dentistry of New Jersey and an adjunct Professor of Medicine at the Mount Sinai School of Medicine. Dr. Teichholz has been active in the field of echocardiography for thirty (30) years, particularly as this science was being developed, and has served on the board of the ASE. Dr. Vasey, too, has strong credentials in the field of echocardiography. He presently serves on the board of the ASE, as well as its operating committees. Dr. Schwartz currently serves as Director of the Echocardiography Laboratory of Morristown Cardiology Associates. He is board certified in internal medicine,

cardiovascular medicine, echocardiography, and nuclear cardiology. He is both a practicing cardiologist and designated teaching service attending at Morristown Memorial Hospital. Dr. Marino is an attending physician at Lenox Hill Hospital in New York City specializing in cardiology, with a subspecialty in echocardiography. He has also maintained a supervisory position in the Echocardiography Laboratory at that hospital for over twenty (20) years and has been Chief of that laboratory for approximately twelve (12) years. Dr. Homma is a board certified cardiologist and Director of Adult Echocardiography Laboratories at Columbia University. He is the Margaret Milliken Hatch Professor of Cardiology and is the Associate Chief of the Division of Cardiology at the College of Physicians & Surgeons of Columbia University. Dr. Homma is current Vice President of the New York Echocardiography Society. Dr. Crawford is a board certified cardiologist. He is currently the Chief of Clinical Cardiology at the University of California San Francisco and a Level III echocardiographer. Copies of the curricula vitae of these nine (9) physicians are part of the hearing record.

The plaintiffs, too, produced qualified witnesses. Dr. Lazar is a board certified cardiologist with Level III echocardiographic training. He is currently an Echocardiography Attending Physician at New York Hospital in Queens and the Director of Non-Invasive Cardiology and Associate Director of Cardiovascular Training at the Medical Center at SUNY-Brooklyn (Downstate Medical Center).[3] Dr. Lassetter is a Level II cardiologist in private practice in Utah. He is board certified in internal medicine, cardiology and interventional cardiology. Dr. Colasacco claims Level III echocardiographic training and is engaged in private practice in Amityville, New York. He is board certified in internal medicine and cardiology. Dr. H. Cohen is in private practice in Chicago, Illinois. He claims Level III training in echocardiography but has not sat for any boards on this subject. Dr. Billhardt is in private practice in Chicago, Illinois. He is board certified in internal medicine and cardiology and claims Level III echocardiographic training. He has not sat for any boards on this subject, however. Dr. Rahko is an Associate Professor of Medicine at the University of Wisconsin Medical School. He has published in the field of echocardiography and serves as a reviewer for several medical journals. Dr. Charash is presently an attending physician at the Columbia Presbyterian Hospital. He was previously an attending physician at Lenox Hill Hospital and Chief of the Cardiac Care Unit at that facility.

[3] Mr. Miele provided general information about the laws of physics governing echocardiography and the equipment used in its practice during the Group I and II hearings. He also provided specific information on Nyquist limits and the effect of transducer angles on color Doppler. As noted later in this Letter Opinion, the Court found Mr. Miele quite knowledgeable in these areas and the Court has referred to his submission in this Letter Opinion. Mr. Miele's resume is part of the record.

Although he does not claim special expertise in the field of echocardiography, he is knowledgeable about its use in clinical medicine. Dr. Ruggie is a board certified cardiologist with Level III training in echocardiography. He is currently an Assistant Professor of Medicine and a Senior Attending Physician in the Department of Internal Medicine at Rush-Presbyterian-St. Luke's Medical Center. Dr. Burnett is a board certified cardiologist and a Fellow of the American College of Cardiology. He has acquired Level III training in echocardiography and maintains a staff position at various hospitals. Dr. Dahl is a board certified cardiologist and a Level II qualified cardiologist licensed to practice clinical cardiology. Dr. Dahl, a Fellow of the American College of Cardiology, has been Co-Director of the Echocardiography Lab at Utah Valley Regional Medical Center since 1996, and is Vice President of Central Utah Medical Clinic. The curricula vitae of these experts also are included as part of the record.

The expert cardiologists appointed by the Court under the terms of the *Eligibility Standards Opinion* also are well qualified. Dr. Saric is presently the Director of the Echocardiography Laboratory at the University of Medicine and Dentistry of New Jersey and has Level III echocardiographic training. In addition to his M.D. degree and board certifications in cardiology and echocardiography, Dr. Saric holds a PhD in medical sciences from New York University. Dr. Sherrid is presently the Director of the Echocardiography Laboratory at St. Luke's Roosevelt Hospital Center and serves as an Associate Professor of Clinical Medicine at the Columbia University College of Physicians and Surgeons. He is the President of the New York Echocardiography Society. Dr. Gopal is the Director of Echocardiography at St. Francis Hospital, Roslyn, New York and is an Associate Professor of Medicine at SUNY (Stonybrook, New York). She is a Level III echocardiographer and has published in the field of echocardiography. Dr. Ong is the Acting Chief of Cardiology and the Director of the Cardiac Non-Invasive Imaging Laboratory at the Brooklyn Hospital Center. He is a Level III echocardiographer and has published in the field of echocardiography. Dr. Millman is the Chief of Cardiology at Trinitas Hospital in Elizabeth, New Jersey. He has had extensive experience in echocardiography and teaches cardiology fellows from the Seton Hall Graduate School of Medical Education. The curricula vitae of these experts also are part of the record.

B.

As in the past, the Court's decisions in these individual eligibility cases are based largely on the quality of the echocardiograms. The initial reports of physicians with respect to virtually all these challenged echocardiograms have

significantly overstated the pathology observed and/or claimed that the echocardiograms were of good diagnostic quality. Accordingly, as in the eligibility hearings on the Group 1, Group 2 and Group 3 plaintiffs (*see Armstrong et al v. Wyeth, Inc.*, (BER-L-7024-03MT); *Comparato v. Wyeth, Inc., et al* (BER-L-332-04); and *Andrade v. Wyeth, Inc.*, (BER-L-1502-04MT) (Letter Opinions dated August 4, 2004, slip op. at 10-12; dated September 22, 2004, slip op. at 14-15; and dated December 9, 2004, slip op. at 16-18), the plaintiffs' experts spent much of their time seeking to excuse and explain these overstatements and/or the poor technical quality of the echocardiograms. In the case of Jack Bly, for example, Dr. Charash admitted that the echocardiogram when read in the parasternal long axis view ("PLAX") did not show any aortic regurgitation. But he excused this by observing that Bly's echocardiogram was "a terrible, poorly resolved film, in which legitimate aortic regurgitation could easily be missed because of the lack of clarity of cardiac structure." Of course, this suggestion is the exact opposite of what should be taking place in these hearings.

Dr. Charash's explanation for his unorthodox approach in reading these echocardiograms is instructive:

> Q. During the diastolic cycle, Dr. Charash, did you see any evidence of aortic regurgitation?
> A. No. But I do want to make a qualification. And that is what I was testifying to.
>
> This is one of the -- on a bell curve of clarity of echo imagery, of seeing the clarity of aortic valve, the aortic route, the left atrium and the mitral valve, and even the left ventricular wall, this is a terrible, poorly-resolved film, in which legitimate aortic regurgitation could easily be missed because of the lack of clarity of cardiac structure.
>
> I believe that the technical -- you are permitted -- and it's not a criticism of the technician. Echos are judged by their technical adequacy in the real world, because different bodies produce different images.
>
> This is a technically difficult study -- either it's a terrible technician or a good technician with a terrible body.
>
> Q. Or it could be that the patient has no regurgitation?

A. I would say that if you were to use this study and say there was no aortic regurgitation, you would be negligently making a decision on inadequate information.

Again, if you decide to turn -- if you want to see if there's a mountain out that window, and you look across the room out a different window and say there are no mountains, you're not making the right call.

You have to look in the right place to see it. This study would not be adequate to exclude aortic regurgitation; it's so terrible.

Q. So, you would say any surface echo, any transthoracic echo, by definition, on an obese patient, you would not be able to rule out valvulopathy; correct?

A. I have not said that by any stretch of the imagination. I said that each echo can be judged for their technical adequacy.

There are some heavy patients with perfect images and thin people with terrible. Having lung disease in a thin person can be worse than having clear lungs in an overweight person.

It doesn't matter about the preclinical descriptor. It matters about the charity [sic] of the echo image. Here, this is a nightmare image.

Q. Let me ask you this, Dr. Charash. Would you then say --

JUDGE WALSH: It doesn't sound like it's a very good image.

THE WITNESS: No. It's a terrible image.

* * * *

JUDGE WALSH: The thing you're referring to here is the freeze frame?

THE WITNESS: Yes, sir.

JUDGE WALSH: All right.

THE WITNESS: There would be enough for me to raise a concern that there's enough regurgitation to justify antibiotics, but not a TE.

JUDGE WALSH: Aren't there several intermediary points? For example, you could change the machine, you could change the transducer --

THE WITNESS: Absolutely.

> JUDGE WALSH: You could do all of those things and obtain a better image?
> THE WITNESS: And again, your Honor, that's the reason why -- and, again, I'm not trying to be difficult -- I'm not thinking legally when I'm here.
>
> But when I'm in a courtroom saying this is the only echo that's used to make a qualification -- in the clinical world I have more than one echo. I can get another echo. But in this court, if we were allowed to get another echo, we could resolve it.
> JUDGE WALSH: Okay. I get your drift.
> THE WITNESS: I'm just trying to make a decision based on this echo. And this echo tells me that I have a reasonable -- more likely than not, there's aortic regurgitation.
> JUDGE WALSH: I think we head back in the area that you were in, I think, very candidly last summer, where you said, Listen, this is what I have. This is -- so, I do the best I can with what I have.
> THE WITNESS: Yes.
> JUDGE WALSH: Is that a fair --
> THE WITNESS: Yes, sir. I would get a different machine; I would try again.

While Wyeth bears the burden of establishing that Bly and the other plaintiffs do not have mild aortic regurgitation, the pathology must be observable in the PLAX, if that view was available. It was available here but no aortic regurgitation could be identified.

Dr. H. Cohen's approach to re-reading the echocardiograms he initially performed for twelve (12) plaintiffs challenged was to "eyeball" the studies. Though he claims to have relied on measurements initially recorded on worksheets by technicians in his practice, these worksheets were discarded prior to these eligibility hearings and were not available to him, the litigants or the Court. Moreover, because the worksheets were destroyed, the locations on the echocardiograms where these measurements were taken is anybody's guess.

> Q. So when you filled out each of these certification forms?
> A. These forms?

Q. Yes, sir. These forms undated but signed by you that have at the top Echocardiogram Review and Assessment.
A. Right.
Q. Are you telling us that what you simply did was to --
A. I relied on the original measurements.
Q. But you didn't have the measurements?
A. No.
Q. At the time?
A. I had the percents, so I relied on the original measurements to get the percents.
Q. No, sir, my question is this: For instance, with regard to Ms. Broadway, if we can turn to her. In your report, it's D 4218, Exhibit 7.

In that report you reflect in answer to Part B, Question 2, the echocardiogram report to diagnose the plaintiff with FDA positive mitral regurgitation, and it actually gave the formula you were to utilize. The regurgitant jet area divided by the left atrial area. And you answered yes, correct?
A. That's correct. Yes.
Q. And on -- in response to -- in filling out this report, you simply reflect multiple measurements and multiple views all greater than 20 percent even in the report the certification that you gave to the Court, did you attempt to specify the specific percent?
A. No. I relied on the original report, original measurements.
Q. And you then reviewed the echo before you completed the certification form?
A. Yes.
Q. And eyeballed the echo?
A. I looked at the echo to see whether it was reasonable to accept those numbers.
Q. And am I to understand that you did not attempt in any manner to re-measure at the time you rendered these certifications?
A. I did not attempt to re-measure it.

Dr. H. Cohen's re-review does mention locations on the echocardiogram that purport to support his original conclusions but as was seen during Dr. H. Cohen's

examination, many of these locations failed to reveal the pathology claimed.[4] Moreover, the quality of these echocardiograms was marginal, to be charitable, with the Court's appointed experts finding 58% of them not to be conducted in a technically adequate manner and 40% of the remainder to be barely interpretable.

---

[4] Emblematic of these errors, Dr. H. Cohen acknowledged that the frames he reported for Ortiz-Gwitt and Reagan were in error.

As to Dorothy Ortiz-Gwitt:

> Q. I'm going to show you the first frame which is 2:41:03 and it will be marked D 4532.
> MR. RAMSAY: and that is OD.1.
> BY MR. RAMSAY:
> Q. Do you have it there, sir?
> A. I have it, but it doesn't show mitral regurgitation, so -- let me see is that a number I put down? Yeah, it is. That's a mistake. It does not show mitral regurgitation.
> Q. It certainly does show significantly high 2D gain, does it not?
> A. It shows high 2D gain but there's no mitral regurgitation on that. That was a mistake.
>
> * * * *
>
> Q. And can one reasonably assess the left atrial area on this particular frame?
> A. Yes.
> Q. You can?
> A. I can.
> Q. Within this particular frame, do you see evidence that the gain is inappropriately high?
> A. Well, the 2D gain is pretty high.
> Q. The color gain?
> A. The color gain is a little bit high.
> Q. Do you see speckling throughout the tissue?
> A. I see some speckling in the bottom part.
> Q. But you do not feel in this frame if the gain was too high, that that would affect the appearance of the area of that which you say on this film demonstrates mitral regurge?
> A. The only area on here that's the mitral regurge is that top area, those bottom ones are probably not, the very bottom one is not.

As to Maureen Reagan:

> Q. You've cited to the Court several frames which you feel were representative of this lady's mitral regurgitation but without measurement, the first one being frame 19:54:26, and that will be D 4506, RMA.1.
> This is the frame to which you referred in your certification to the Court, is it not?
> MR. D'ANGELO: No.
> THE WITNESS: There's no mitral regurgitation on this picture.
> MR. D'ANGELO: For the record, it appears to me that you pulled up 26.
> MR. RAMSAY: Is that not what is on here?
> MR. D'ANGELO: It could be 26.
> BY THE WITNESS:
> A. It says 26 but that's a mistake.

In some instances, the plaintiffs' experts reached their conclusions that plaintiffs had, at least, MMR by reporting LAAs that were highly suspect. For example, Dr. Billhardt reported a LAA measurement for McReynolds of 7.06 cm^2. This is well beyond minus two (2) standard deviations from the mean left atrial area of 14.2 cm^2 reported in the Weyman Text, and well beyond minus three (3) standard deviations from the mean left atrial data of 19 $cm^2 \pm 3$ cm^2 (end systolic area) reported at Echoly Web (http://www.echolyweb.com) which was recognized by Dr. Saric. This is particularly significant because McReynolds was 5'5", 240 pounds at the time of her echocardiogram and Dr. Billhardt's report noted that "[t]he left atrium [was] mildly deviated." Other reported LAAs of 5.4 cm^2 for Vavra are practically impossible in the face of Dr. Billhardt's initial report that Vavra's "left atrium is normal in size."[5]

In other instances, Nyquist limits of 41 cm/sec, well below the Nyquist limits outlined in the *ASE Standards* at 777-778 (50-60 cm/sec) and in the Weyman Text at 245 (60-90 cm/sec), appear in echocardiograms supporting the opt-outs. In the face of such obvious deviations from proper echocardiographic practice, other plaintiffs' experts were left to opine that the clear capacity that this low Nyquist limit to inflate any observed regurgitant jet were overwhelmed by angle effects where views were taken in the PLAX or that the echocardiograms were "technically difficult."

In many instances, the techniques used in acquiring the echocardiographic images fell so far below appropriate practice as to make the data reported and conclusions made by plaintiffs' experts virtually worthless in either diagnosis or treatment. With respect to the seventy-one (71) plaintiffs included in this Letter Opinion, the experts appointed by the Court concluded that with respect to over forty-three percent (43%) of them, the echocardiograms were so technically inadequate that reasonable medical conclusions could not be drawn from them.

Plaintiffs were aware that the qualifying echocardiograms in issue would be used to support the opt-outs sought. As will be seen, however, in the seventy-one (71) cases reviewed here, many of the submitted echocardiograms were of such poor quality or were interpreted in a manner so plainly at odds with good medical practice that they cannot, as a matter of law, support those plaintiffs' claims to qualify as FDA Positive. Overall, the experts appointed by the Court opined in an astounding eighty-eight point seven percent (88.7%) of the cases that the FDA

[5] Dr. Ruggie made similar implausible LAA measurements. In P. Kane's case, a LAA of 6.18 cm^2 was used for calculations when LAAs of 14.73 cm^2 and 13.54 cm^2 were traced in adjacent systolic loops.

Positive mitral or aortic regurgitation determinations made by plaintiffs' experts were not medically reasonable.

The findings with respect to the seventy-one (71) plaintiffs follow in the next section of this Letter Opinion. Where credibility determinations are made, they are reflected in the findings reported below.

III

A. JANICE F. ADEYEMO

Adeyemo relies on a May 28, 2002 echocardiogram performed by Associates in Cardiology Ltd. and a report by Dr. Neal Ruggie. Dr. Ruggie found that Adeyemo had moderate mitral regurgitation ("MMR") using CAS criteria -- RJA/LAA = 27%.

The May 28, 2002 echocardiogram was reviewed by three (3) experts: Dr. Goldman, Dr. Gopal and Dr. Ruggie. Dr. Gopal found the echocardiogram to be technically marginal with the Nyquist limit set at 53 cm/sec.[6] Nevertheless, Dr. Gopal believed the echocardiogram could be interpreted. The other physicians found the echocardiogram to be technically adequate.

Both Drs. Goldman and Gopal found that it was not medically reasonable to diagnose Adeyemo with MMR. Dr. Goldman found that there was "no substantial holosystolic flow." Moreover, according to him, all three (3) of the RJA measurements were significantly overtraced. Dr. Gopal also found that the traced RJA "included low velocity components and broken jets." Dr. Gopal found that the LAA was "grossly undertraced in several of the frames seen." Taking the best frames from Adeyemo's perspective, Dr. Gopal found the RJA/LAA to be 14.3% -- insufficient to support a MMR claim.

Dr. Ruggie reexamined the echocardiogram and concluded that Adeyemo had MMR with RJA/LAA readings between 21% and 27%. Dr. Ruggie disagreed with Dr. Goldman's conclusion that MMR should be holosystolic, observing that in his view mitral regurgitation need not be so. His conclusion that Adeyemo had MMR was based in significant part on a finding that Adeyemo had a representative LAA of 9.5 cm^2.

[6] Dr. Gopal indicated that her practice was to require a Nyquist limit at or above 55 cm/sec. In light of the ASE Standards and testimony of the other experts, the Court believes that a Nyquist limit of 50 cm/sec or above is technically adequate for these proceedings.

The Court finds that Wyeth has established that no reasonable physician could find Adeyemo has MMR based on a review of this echocardiogram. First, mitral regurgitation should be holosystolic. Virtually all the experts agree that MMR should be seen through most or all of systole. Weyman teaches that "[m]itral regurgitant flow typically begins immediately after mitral closure and continues throughout most or all of systole." Here, any jet lasts for only one (1) or two (2) frames during systole. Therefore, the jet is hardly holosystolic.

Moreover, Dr. Ruggie finds that "[t]he left atrium is mildly dilated" with a left atrium dimension by M-mode reported at 4.3 cm (4.7 - 4.2 cm by apical 4 chamber). This measurement is totally inconsistent with a reported LAA of 9.5 cm^2 and indicates that the left atrium was foreshortened by a considerable amount because of the angle of the interrogating beam. Such a LAA finding is also unlikely in Adeyemo who, at the time of this echocardiogram, was 5'5" and weighed 240 pounds. If the more reasonable LAA of 16.7 cm^2 is used, as suggested by Dr. Gopal, the RJA/LAA computes to 15.5% and fails to satisfy the minimum definition for MMR.

B. CYNTHIA BARRETT

Barrett relies on a May 16, 2002 echocardiogram and report by Dr. Linda Crouse. Dr. Crouse found that Barrett had MMR and moderate aortic regurgitation ("MMAR") using CAS criteria -- RJA/LAA = 21% and JH/LVOT = 31%. Only the aortic regurgitation claim is at issue here.

The May 16, 2002 echocardiogram was reviewed by three (3) experts: Dr. Schwartz, Dr. Gopal and Dr. Lazar. All three (3) physicians found the echocardiogram to be technically adequate though Dr. Gopal noted that the videoframes used for the analysis were "unclear" and the gain was excessive, and Dr. Schwartz believed the gain was set too high.

Both Drs. Schwartz and Gopal, nevertheless, concluded that Barrett did not have aortic regurgitation. Dr. Schwartz stated that "[t]here is no holodiastolic aortic regurgitation visualized on this echocardiogram." Dr. Gopal concurred and observed "[t]he videoframes that were analyzed were unclear on the provided study. However, color flow Doppler does not reveal any significant aortic regurgitation. A clear diastolic jet is not visualized."

Dr. Lazar had a different opinion. He believed that two (2) frames in Barrett's echocardiogram demonstrated mild aortic regurgitation ("MAR"): page

10, JH/LVOT = 11%; page 48, JH/LVOT = 21%. Dr. Lazar conceded that "the gain is a little high" but overall he believed the study was a "reasonable" one. "The only major criticism I would have is that it was -- in the views that were demonstrated, it was impossible to either confirm or refute the AI jet to be at holodiastolic. In several frames it appeared at multiple points to occur at various points in diastole. But, you know, a clear demonstration of an entirely holodiastolic jet was not on the study."

The Court finds that Wyeth has established that no medically reasonable conclusion that Barrett has MAR could be based on this echocardiogram. The Court accepts that, though flawed, this is an adequate echocardiogram, at least to exclude MAR. All the physicians agree that the phenomenon observed is not holodiastolic. Moreover, the continuous wave Doppler ("CW") demonstrates that fact. Finally, the measurements made by Dr. Lazar in support of the MAR claim are internally inconsistent and well out of the normal range. A LVOT of 1.33 cm and 1.63, which Dr. Lazar measured, is far from the norm and is highly suspect. The LVOT height in a normal adult is approximately 2 cm with relatively small deviations. In fact, Dr. Lazar found LVOTs on the echocardiogram which measured 1.9 and 2.06 cm and reported this on his initial worksheet.[7]

---

[7] Dr. Lazar's testimony in this regard is instructive.

> Q. Doctor, my point is, on this particular frame that was chosen and these based upon the EKG screen -- and it's not as apparent on the big screen -- it appears, does it not, sir, that it is right at the beginning of diastole?
>
> Do you see the little --
>
> JUDGE WALSH: He does. It's very clear on that.
>
> Q. All right.
>
> A. Yes.
>
> JUDGE WALSH: Do you agree with him?
>
> Q. So, this particular frame, obviously, in and of itself, would not be demonstrative of whether or not whatever we see there is, in fact, holodiastolic; would you agree?
>
> A. Yes.
>
> * * * *
>
> JUDGE WALSH: Plaintiff's 4000?
>
> MR. RAMSAY: Yes, sir.
>
> Q. -- where you made the measurement.
>
> And in that particular frame, still, again, in very early diastole, you measured right at the tip of this thing that you're telling us here today is a regurgitant jet, and you found that it was .15 centimeters; correct?
>
> A. Yes.
>
> Q. All right. Now, when you looked and you made the measurement of the outflow tract and it was only 1.33, didn't that cause you at all some discomfort with regard to the reliability of that measurement as to this lady's outflow tract?
>
> A. It's a little small. But, in general, outflow tracks are roughly proportional to body surface area.
>
> Q. Yes, sir.

Well, in the course of your review, did you attempt to see if there were other frames that would be more representative in making an accurate assessment as to the dimensions of the outflow tract?
A. Yes.
Q. Did you find them?
A. No.

* * * *

Q. Now, sir, I realize that -- by the way, can you see or can you determine for us from this frame, because of the color gain, whether or not there even exists a regurgitant jet?
A. No.
JUDGE WALSH: You say the left ventricular outflow tract is roughly equivalent to body surface?
THE WITNESS: Not equivalent. The larger the person, the larger the anulus. There's a rough relationship.
JUDGE WALSH: Well, this woman is 240 pounds, 5 foot 5.
THE WITNESS: It's more dependant on height than weight.
JUDGE WALSH: Well, you said the surface area, so --
THE WITNESS: Yes. Roughly with surface area, better with height. Height is a better determining point.
JUDGE WALSH: She's 5 foot 5. She's not a small lady, even when you don't consider the inelegant 240 pounds.
So, she's a large woman; fair?
Q. Doctor, as one looks at that -- and my only point is this.
At least as to the measurement of the outflow tract, it appears to have been accurately measured; does it not?
A. I'm not sure. I'm not sure that I could adequately define the outflow tract in this view.
Q. All right, sir --
A. The color obscures the -- the structures.
Q. The gain certainly makes it difficult; doesn't it?
A. The color flow as well as the gain, sure.
Q. We can agree, can we not, that the gain in this particular picture is pretty high?
A. Yes.
Q. Now, in that particular frame, the measurement was 2.06 centimeters; correct?
A. That's what the technician measured it to be, yes.
Q. Yes, sir. And, in fact, when you made your initial screen report, you measured -- you looked at this tape and were the first individual to make an assessment as to what, if anything, the echo demonstrated as to those dimensions of the outflow tract; didn't you?
A. Yes.
Q. And did you or did you not find at least in two frames where, in your judgment, based upon your measurements, the -- just a second. I'm sorry.
(Whereupon, a discussion occurred off the record.)
Q. You found that it was at least 2 centimeters in the frame when you initially reviewed it; did you not?
A. I don't have that. I would have to review it.
Q. I think that's Exhibit 5000.3 -- I'm sorry.
MS. CRAVENS: 5008.3. Defendant's Exhibit 4109.

* * * *

JUDGE WALSH: Sorry. Go ahead. Now we're on the worksheet that Dr. Lazar prepared?
MR. RAMSAY: Yes, sir.

Q. Did I quote the figures accurately, you found at least in one frame where you felt the LVOTH was at least 2 centimeters?
A. Yes.
Q. All right. Now, if I can turn quickly to page 48. That is the second frame you have presented to us that you indicated that you had made a measurement.

And did I understand you correctly that this was more of an oblique view of the parasternal long axis?
A. Yes.
Q. Now, on this particular view, sir, you've told us that you've measured what you deemed to be a frame that demonstrated regurgitant jet flow.

And on this particular one, did you attempt to measure it right at the point where you first were able to see the jet emanating from the orifice?
A. I did. I probably, as discussed before, measured the narrowest portion, which was proximal, and therefore represented flow convergence.
Q. Yes, sir. The reason for my question is this. And I know we're dealing with very minute values.

But in order to come up with a .33 dimension where your regurgitant jet, that was determined by how you placed the horizontal bars on the two crosses in the area of the regurgitant jet; correct?
A. Yeah.

* * * *

Q. Can you show us on this particular frame where you made the measurements and came up with -- I think it was .33 centimeters -- where you, in fact, made those measurements across the jet plane?
A. I'll look carefully. They're depicted in orange. It's a little difficult to make out.
Q. They are vertical bars; are they not? It's a vertical bar?
A. Yes.
Q. So, then, we're clear, does it not appear that your vertical bar starts at the horizontal arm of the cross above this jet, if that's what it is, and extends down to the horizontal bar beneath where the jet is?
JUDGE WALSH: That's the way it usually works. I guess your point is there's some black space there.
MR. RAMSAY: Yes, sir.
Q. My point is simply this, Doctor.

Because we're dealing with such minute figures, does it not appear that you have overestimated the jet height here by a factor of at least 50 percent?
A. No. In fact, I think I probably have grossly underestimated the jet height. And probably the measurement should be closer toward the measurement of the outflow tract. That's if anything.
JUDGE WALSH: I guess what he wants to know, though, is why did you measure it on an oblique like this when you could have measured it perpendicular to the leading edge of the jet, which would have given you -- I think we can all agree -- a very considerably smaller --
THE WITNESS: Well, if I may answer that.

Do you have a pointer?
MR. RAMSAY: I'm sorry. Yes, sir.
THE WITNESS: I've consistently tucked the margins of the jet in tight and have been generous with the chambers I mentioned.

What I did here was -- again, this is an irregular-shaped jet. There's several options here. I mean, one can say that the jet starts -- concludes this red border above the yellow border above the white. It could say maybe this is a zone of convergence and it includes just the yellow.

What I did is I took this jet, placed a horizontal here to separate the measurements. And this top measurement represents the blue. And, if anything, it was a deliberate attempt to underestimate the jet. That's all.
JUDGE WALSH: Maybe I'm confused where exactly these orange things go. Why don't you just trace along, if you could, where the orange line was.
THE WITNESS: The outflow tract is here and here. And 1.6 is a little small, but not -- not two standard deviations.

I basically took this point and this point. If I had to make this measurement again, I probably would measure it from here to here, which would --
JUDGE WALSH: Which would probably be larger; that's what you're saying.
THE WITNESS: Which would probably be larger.
JUDGE WALSH: Right. I mean, you have to give the questioner his point, which is there's a lot of black space between one orange cursor and the other one.

And if you were to draw a straight line in between them, the actual leading edge of the jet would be considerably smaller than --
MR. D'ANGELO: Off the record -- I'm sorry. He controls the record, not me.
JUDGE WALSH: We all participate in it.
MR. D 'ANGELO: I can't really see here --
JUDGE WALSH: Go ahead, Mr. D'Angelo.
MR. D'ANGELO: This is 0.34. I can't tell if he's pointing at the decimal point as the cursor or something else.
JUDGE WALSH: I thought he was.
MR. D'ANGELO: Yeah. That's a decimal point.
JUDGE WALSH: That's true.
MR. D'ANGELO: Looking at the screen --
JUDGE WALSH: I think this all started with, "Show me where you measured it."
MR. D'ANGELO: What he did was here. There appears to be on the other screen, like, a little bit of orange over. And if you look at the measurements, the one that was up here is, like, .45, and his is .33.
JUDGE WALSH: I think what Mr. Ramsay wants to know is, what did you measure?

* * * *

THE WITNESS: Reproduction of this is difficult. But as this discussion has gone on, I think it is much clearer where the actual measurement was made, and I will point that out.
JUDGE WALSH: Okay. Why don't we do that.
THE WITNESS: And if you could stand right here, you'll see it best. Because I'm actually looking -- if you could stand right here.

This is one orange mark. That's a second orange mark. Right on the tip of this -- and you see that line. That's very hard to appreciate from a different angle. So, I apologize.
MR. RAMSAY: So that I can make sure the record is clear --
JUDGE WALSH: You got one orange mark that apparently is at the border of the yellow of this jet, and then you've got another orange mark that apparently is on the other side of the yellow -- of this purported jet, excluding the red border.
MR. RAMSAY: Right, sir.
JUDGE WALSH: And I would say that the anchoring point looks like it's pretty close to the line that connects the left ventricular outflow tract. And the upper cursor looks like it's displaced to the right of the outflow tract line.
Q. Doctor, in light of that last response, let me ask you this question.

Are you telling us that you believe that it's medically reasonable -- are you familiar with what's called nozzle effect when dealing with regurgitation?
A. I've heard the term used.

Q. Is it ever --
A. I'm not sure it's in Weyman.
Q. All right. Is it ever medically reasonable for one, in attempting to determine jet height, to measure distal to the orifice after one can clearly see there has now been spray as one goes more distally from the very commencement of what you here tell us is regurgitant flow?
A. Yes. And I think that if you're asking whether or not this early spraying represents a nozzle effect, the answer is clearly no.

This is the nozzle effect in that downstream more than a centimeter from the valve plane, the jet splays.

Again, the measurement represents -- and I'm not sure whether to include the red in the measurement. For conservatism sake, I did not.

I think that this is a reasonable representation of the outflow tract. And I believe we're close to the valve plane, and the yellow clearly depicts the jet.

And I would just add that, on my computer, it is impossible to see that orange small line.
JUDGE WALSH: Okay. Well, you explained it. I do have one question. And it may be a little off the point, and I apologize if it is.

Would you mind telling me where the two centimeters are in terms of his measurement worksheet? I went to it. I didn't see.
MR. RAMSAY: I'm sorry, Judge. I believe it's right there.
JUDGE WALSH: So it is. You have very good eyes.
MR. RAMSAY: I just knew where it was. I can't see at all.
Q. So then that I'm clear, at least, you're telling this court that this that you see that is to the right generally of this line that you have made to measure the outflow tract, you do not consider to be regurgitant jet?
A. It's a semantic question, because it's probably flow convergence. Does one consider flow convergence to be part of the regurgitant jet?
JUDGE WALSH: You're the expert, so what's the answer?
A. Dealer's choice, the answer is -- the best way to measure it is at -- is as close to the valve plane as possible.
Q. Yes, sir. Are you contending here that the valve is opened or closed?
A. In this freeze-frame, you can't -- one can't state. Although --
JUDGE WALSH: How can you measure a regurgitant jet if the aortic valve isn't closed? I mean, if it's opened, what are you measuring?
THE WITNESS: You wouldn't be measuring the regurgitant jet.
JUDGE WALSH: That's for sure.
Q. And here again, the higher the gain, the more the opportunity for one to see artifact and perhaps conclude it's regurgitant jet when, in fact, it's only artifact; correct?
A. Yes. Which is why I wasn't sure whether to include the red or not. And I did not.
Q. Well, assuming for the moment that, as you've testified, this is a regurgitant jet, and that this portion is part of it, and, in fact, the outflow tract is more to the right than you have showed it, can we at least agree that if this were the measurement being made generally in the area where the crosses are to the right --
JUDGE WALSH: The first set of crosses by the technician.
Q. -- that at the very least the regurgitant jet would probably be no more than .15 centimeters, which is what you had previously reflected you found on the first frame?
A. Is that a question or a statement?
JUDGE WALSH: I think it was a little bit of both.
MR. RAMSAY: I'm sorry.

The Court is satisfied that based on this echocardiogram, no medically reasonable MAR claim can be made. The JH was overtraced and the LVOT seriously underestimated. Finally, the jet is not holodiastolic.

C. JACK L. BLY

Bly relies on a May 17, 2002 echocardiogram performed by Inland Cardiology Associates P.S. and a report by Dr. Susan J. Alexander. Dr. Alexander found Bly had MAR using CAS criteria -- JH/LVOT = 20%.

The May 17, 2002 echocardiogram was reviewed by three (3) experts: Dr. Goldman, Dr. Gopal and Dr. Charash. All three (3) physicians found this echocardiogram to be adequate for review although, as noted, Dr. Charash testified that the quality was "terrible" and Dr. Gopal noted a low Nyquist limit.[8]

JUDGE WALSH: I think what he's driving at is this. You made those measurements in the past. So, why depart from those measurements?

I mean, if those measurements are accurate, it's about 6 percent. It's not an FDA positive situation. That's what he's arguing in the form of a question.

THE WITNESS: Let's go -- even if it's -- even if the outflow tract is -- 90 percent of people have an outflow tract between 1.8 and 2.2 centimeters. In fact, some people say a continuity equation in calculating aortic stenosis, just use 2.0.

But even if one were to use 2.0, .34 over 2.0 is --

JUDGE WALSH: No doubt about it. But 1.15 (sic) [.15] over 2 is not. So, that's what he's -- he's arguing you inflated the JH, and you lowered the LVOT. And by doing that, you calculated a -- an amount that would qualify.

But previously, when you worked up your worksheet, you calculated a matter which wouldn't qualify. I think I got the point.

* * * *

Q. You have presented to the court P-4000, which is a previous frame where you also measured, and in that frame you measured the regurgitant jet or what you contend is a regurgitant jet, as .15; did you not?

A. Yes.

Q. And, here again, if we simply assume an outflow tract of 2 centimeters, that obviously does not arise close to 10 percent; does it?

A. No, it would not.

Q. Now -- and I'll leave for others.

Doctor, on none of this Dicom -- you've reviewed this entire Dicom; haven't you?

A. Presumably. I presume the Dicom that was given to me.

Q. Can you point to this court anywhere on this Dicom that you reviewed where in real-time you could see a regurgitant jet that was holodiastolic?

A. No. That was my statement originally.

[8] Dr. Gopal also indicated that some of the still frames under review had been taken in systole when the left ventricle was expelling blood into the aorta. It is inappropriate to attempt to measure an aortic jet in systole.

Both Drs. Goldman and Gopal found that the MAR claim was unsupported. Dr. Gopal found there was "[n]o consistent diastolic jet … demonstrated on color flow Doppler or spectral Doppler." Dr. Goldman concurred, finding "[t]here is no sustained holodiastolic flow throughout the cardiac cycle." Rather, the purported jet was seen in a single frame with CW indicating the phenomenon to be transient.

Dr. Charash found MAR with JH/LVOT = 17%. He conceded that the jet observed was not holodiastolic but excused the necessity for it to be so since, in his view, it was not required by the CAS. Dr. Charash found the echocardiogram frames "a bit blurry" and could not see any evidence of aortic regurgitation on the frames of the loop he claimed to have traced. As noted earlier in this Letter Opinion, Dr. Charash excused his inability to see aortic regurgitant jets on the quality.

The Court finds that Wyeth has satisfied its burden of showing that no reasonable medical conclusion that Bly had MAR could be supported by this echocardiogram. Spectral and color flow Doppler plainly indicate that any jet present during diastole is not holodiastolic. The Court disagrees with Dr. Charash's view that the CAS does not require an aortic jet to be holodiastolic. The great weight of the expert testimony and the teachings of the medical texts do require that aortic regurgitation be holodiastolic. Weyman teaches:

> [a]lthough the presence of aortic regurgitation may be suspected from the appearance of the valve (i.e., flail aortic valve) or root, demonstration of the abnormal regurgitant jet is achieved by Doppler methods. *Aortic regurgitation is detected by Doppler as a high velocity, turbulent, diastolic flow originating just below the aortic valve … immediately after valve closure and generally continuing throughout diastole.* Although the jet can be recorded using any of the Doppler techniques, color flow mapping, which depicts jet origin, size, and spatial distribution … and continuous wave Doppler … which reports the maximum jet velocities and the timing of flow, provide the primary information.

Weyman at 529 (emphasis added). The Court agrees that a jet may be missed in one or even several frames because of the transducer angle or cardiac movements, but one has to see the jet in more than one (1) frame. And the evidence shows that only one frame is present here.

D. MADELINE L. BROADWAY

Broadway relies on a May 25, 2002 echocardiogram performed by Cardiac Consultants of Chicago, Ltd. and a report by Dr. Richard Levinsky. Dr. Levinsky found that Broadway had MMR using CAS criteria -- RJA/LAA = 20%.

The May 25, 2002 echocardiogram was reviewed by three (3) experts: Dr. Goldman, Dr. Gopal and Dr. H. Cohen. All three (3) physicians found the echocardiogram to be technically adequate, though Dr. Goldman complained about the 2-D gain settings.

Both Drs. Gopal and Goldman concluded that the echocardiogram did not demonstrate that Broadway had MMR. Dr. Gopal noted that "[t]here … [was] no consistent holosystolic jet in the apical view by color flow Doppler or by Spectral Doppler." Dr. Goldman concurred, stating that "[t]here [was] no sustained holosystolic flow throughout the cardiac cycle."

Dr. H. Cohen found evidence of MMR on Broadway's echocardiogram. However, because there are no markings on the echocardiogram where the technician took the measurements supporting the original claims, and the technician's worksheet was discarded, Dr. H. Cohen could not find, let alone analyze, the original data. Instead, Dr. H. Cohen viewed the echocardiogram and eyeballed the data. He then provided locations on the media which he claimed supported the original conclusion. In Broadway's case, one of the frames he reported was not taken in systole as is required but rather in diastole when the mitral valve is open.

The Court has reviewed the echocardiogram as well as the testimony of the other experts. Dr. H. Cohen's conclusion that Broadway has MMR is virtually unsupported by the evidence. It is plainly a net opinion which is entitled to no weight. *See Buckelew v. Grossbard*, 87 N.J. 512 (1982); *Myalak v. Port. Auth. of NY and NJ*, 302 N.J. Super. 1 (App. Div. 1997), *aff'd in part and rev'd in part on other grounds*, 157 N.J. 84 (1999); *Jimenez v. GNOC, Corp.*, 286 N.J. Super. 533 (App. Div. 1996). The Court finds that Wyeth has satisfied its burden to establish that no medically reasonable conclusion that Broadway has MMR could be based on this echocardiogram. There is no consistent holosystolic jet percent. Moreover, what is suggested to be a jet is fleeting and the blood flow is laminar, well below the five (5) to six (6) meter speed one would expect in the presence of true regurgitation.

E. DAVID W. BURNETT

Burnett relies on a July 20, 2002 echocardiogram performed by Cardiac Consultants of Chicago, Ltd. and a report of Dr. Richard Levinsky. Dr. Levinsky found Burnett had MMR using CAS criteria -- RJA/LAA = 24%.

The July 20, 2002 echocardiogram was reviewed by three (3) experts: Dr. Vasey, Dr. Gopal and Dr. H. Cohen. Both Drs. Gopal and Vasey found that the echocardiogram was not conducted in a technically adequate manner so that reliable medical conclusions regarding the presence and severity of valvular regurgitation could be drawn from it. Dr. Gopal found that the echocardiogram had "[p]oor two-dimensional … image quality with very slow frame ratio." Dr. Vasey found that "[t]he image quality was exceedingly poor as well as the color flow mapping. Due to the poor quality study and inadequate color flow mapping, no reliable assessment of the presence or severity of regurgitation can be made…."

Dr. H. Cohen does not mention any technical difficulties with the echocardiogram, noting that "[t]he echocardiogram settings were appropriate and the study was of diagnostic quality." He concludes that Burnett has MMR based on his technician's measurements reported in the initial report by Dr. Levinsky.

The Court finds that Dr. H. Cohen's claim that "[t]he echocardiogram settings were appropriate" is incredible. Review of the echocardiogram makes it clear that no reliable measurements can be made of the LAA because of the 2-D gain. Of course, if the LAA cannot be traced, no claim of MMR can be made. Dr. H. Cohen himself conceded that since no tracings presently exist one cannot even reproduce the claimed LAA, let alone critique it. The entire echocardiogram image on review is filled with white contrast. Despite Dr. H. Cohen's claim, there is no indication that there is any regurgitation or that it is holosystolic. Finally, spectral Doppler confirms no blood flows in excess of one (1) meter, a telltale sign that MMR does not exist.[9] In short, Wyeth has easily satisfied the Court that no

[9] Dr. H. Cohen's testimony on the spectral Doppler and on the inability to replicate any LAA measurements is set forth below.

> Q. Is this, again, where 1 of the line force the probe would be on this picture above the mitral valve and another at the mitral valve?
> A. I must admit, I can't see the lines, but I don't see any that are in the ventricle. So one could be at the valve and one could be at the left atrium.
> Q. As one looks at this color this continuous wave, are you telling this court that this continuous wave confirms or demonstrates the existence of mitral regurgitation?
> A. Well, what this demonstrates is flow from the left ventricle to the left atrium that occurs throughout systole. There is some degree of aliasing in the -- about the first one third.

medically reasonable claim could be made that Burnett has MMR based on this echocardiogram.

F. WILLIAM F. BUSCH

Busch relies on a February 21, 2002 echocardiogram performed by Cardiovascular Associates of the Delaware Valley and a report by Dr. Stephen E. Weinberg. Dr. Weinberg found that Busch had MMAR using CAS criteria --

---

Q. All right. Would you show me where you tell us where it shows the flow from the left ventricle to the left atrium. Where are you talking about?
A. Because the probe – because of where the probe is and because of the direction of the flow during systole.
Q. Can you show me where you reflect -- just lead this --
A. That's where we started at the top.
Q. Well, are you talking about here or are you talking about here?
A. Yeah, that.
Q. Right here?
A. The downward part.
Q. I want to make sure we're clear. You're telling us that this is what you considered to be the flow in --
A. In systole.
Q. In systole?
A. Yes.
Q. And this would be diastole?
A. Yes. That's the E wave. That second.
Q. All right. And as one looks at it, as one looks all the way across, does it appear that the velocity of whatever we see there even reaches one meter?
A. Well, not at this angle. Not at the angle in which this was taken.
Q. This does not demonstrate high velocity flow, does it?
A. You cannot see high velocity here. But you do see aliasing and aliasing does imply that there is at least some high velocity.
Q. Yes, Sir.
A. You're aware of that.
Q. Yes, Sir?
A. Okay.
Q. And even as we sit here today [] there's no way even working backward for you to tell us what you defined as the regurgitant jet area and what you defined as the left ventricle area, correct?
A. You mean left atrial area.
Q. Left atrial area, sorry?
A. As far as the original percents are concerned no.
Q. The original measurement that is yielded the percent?
A. Right.
Q. All right.
A. Because I don't have those measurement[s].
Q. I think they've been entered -- you're telling us on these frames that you reflect in your certification that in the same frame in which the regurgitant jet area would have been -- would have been measured it would have been in the same frame the left atrial area would have been measured?
A. I don't know in which frame the left atrial area or the jet was measured, but I'm saying that they were measured simultaneously.

JH/LVOT. The attached worksheet indicated two (2) measurements, JH/LVOT = 31.5% and 25.6%.

The February 21, 2002 echocardiogram was reviewed by three (3) experts: Dr. Vasey, Dr. Gopal and Dr. Lazar. All three (3) physicians found this echocardiogram to be technically adequate.

Both Drs. Gopal and Lazar found that Busch had MAR. Dr. Gopal observed that

> [t]he findings on both the parasternal long axis and apical views are consistent with trace to mild aortic regurgitation by visual estimation alone. However, the criteria outlined by the court of a jet height/LVOT height of 10% are satisfied even using the [] smallest determined jet height and largest determined LVOT ….

Dr. Lazar, while conceding that the loops from which tracings were taken could not be shown to be holodiastolic, stated that the jets in these loops

> were identified and traced in freeze frame, which did not allow for their demonstration throughout diastole. However, there appears to be the same AI jet at an orthogonal plane in the short axis view beginning at frame count 29:15:22. At this location, the AI jet is seen to begin just after the T Wave and to be present throughout frame count 29:15:28 which is just after the P Wave of the following beat. In addition the beat at 27:35 was excluded because there was a PVC. Frame count 30:53 shows the AI jet in freeze frame in the 3 chamber view.

Dr. Lazar concluded, as did Dr. Gopal, that Busch had MAR with three (3) JH/LVOT measurements between 10% and 19%.

Dr. Vasey disagreed and argued that the tracings had not been taken from truly holodiastolic jets. Moreover, Dr. Vasey believed the jets were overtraced and traced in the wrong locations.[10]

[10] Dr. Vasey also commented on Dr. Gopal's testimony on the measurements. That testimony is related below.

JUDGE WALSH: Before we leave Busch, I want to cover a couple of things. I'd like you to comment on Dr. Gopal's findings.

Some of the trace frames occurred immediately after a ventricular premature complex and could have overestimated jet width.

I assume that's, basically, a rhythm anomaly which causes a higher volume of blood.

THE WITNESS: If you have -- on the tracing, there were a number of premature ventricular contractions. So what happens, essentially, is there's electrical activity outside the normal activation sequence of the heart. So you're beating along, beating along, and all of a sudden, an electrical impulse from the heart muscle itself, and one of the other ventricles causes an early beat. So you're beating and beating and then there's a lurch. And then the next electrical impulse comes down through the conducting system and finds that the heart has just contracted. Electively as a safe-gap measure, it can't repolarize and contract that fast. So that electrical impulse finds that the heart is refractory and so then the heart pauses. That's called a compensatory pause. During that pause, the heart has more time to fill, so the volume is fuller and the muscle is more stretched. And so the vigor of the next contraction is more pronounced and people often experience that as a kick or something in their chest, but basically, it's inappropriate to make any assessment of regurgitation in that context because it can be exaggerated by the apparent conduction.

JUDGE WALSH: She continues, though. She says, [h]owever, some frames that were not associated with rhythm abnormalities showed a jet width of at least 3 millimeters [.3 centimeters]. Even assuming the greatest determined LVOT diameter of 2.61 centimeters, shown on frame and then she gives the frame, the FDA criteria are met.

* * * *

A. My concern about that is what we already talked about, you really don't know where that jet height is in context or in relation to the aortic valve, and you really don't know if the jet has diverged because you're looking at a three-dimensional regurgitation in trying to display the two dimensions, but you really don't, I think, have enough information to say that that's actually accurate. And then I think when you do see, what appears to be more proximal is that little triangular jet that we looked at. If you actually measure, the origin of the jet is really tiny. I think I measured it just using the display that you provided with calipers and got 6 percent. So I, personally, thought that even quantitating it, it was trivial.

JUDGE WALSH: Would it be reasonable, I mean, for Dr. Gopal to make the findings that she made? I mean, knowing that there's some interreader variability --

THE WITNESS: I think this is a very important question clinically because if there's actually mild aortic insufficiency, then you would recommend endocarditis prophylaxis. I think she read it as trace to mild.

JUDGE WALSH: That's what you just said.

THE WITNESS: Which really is less than mild.

JUDGE WALSH: But then she went back and kind of said, you know, we have a test here, and we do, and it's really a binary test. In some ways, it's not -- it's not like clinical practice of medicine. You win. You lose.

So I mean, at that very close margin, then there are questions where somebody says you win. Somebody says you lose. In that situation, is it reasonable for the people to differ?

THE WITNESS: I think if your question is [is] it reasonable to call this mild aortic insufficiency, I think it is unreasonable.

JUDGE WALSH: Okay.

The Court finds that in this instance Wyeth has not satisfied it that no reasonable medical conclusion could be drawn that Busch has at least MAR. It is true that the aortic jets were not shown to be holodiastolic, but they were present in four (4) loops at apparently different periods in the diastolic cycle.

G. KIMBERLY L. CALLISON

Callison relies on a December 11, 2002 echocardiogram and a report by Dr. Lazar. Dr. Lazar found that Callison had MMR and MAR using CAS criteria -- RJA/LAA = 27% and 30%; JH/LVOT = 14%.

The December 11, 2002 echocardiogram was reviewed by three (3) experts: Dr. Schwartz, Dr. Gopal and Dr. Lazar. Both Drs. Gopal and Schwartz found that the echocardiogram was conducted in a technically inadequate manner such that reliable medical conclusions regarding the presence and severity of valvular disease could not be drawn from it. Dr. Gopal found the "[c]olor gain [was] vastly excessive as is suggested by speckled regions outside [the] region of interest." Dr. Schwartz concurred.

Nevertheless, both experts examined the echocardiogram to determine whether any information could be gleaned from its review. As to the mitral regurgitation claim, Dr. Gopal concluded that none existed. She noted that "[n]o consistent holosystolic jet … lasts for more than [one] videoframe. This only represents trivial to mild mitral regurgitation associated with closing volume. Frames 26 and 29 are taken in very early systole, immediately after the R wave and show overtraced jet areas that include low velocity nonaliased components. This together with high color gain overestimate [any] jet area." Dr. Schwartz again concurred with these findings.

As to the aortic regurgitation claims, Dr. Gopal noted that there is "[n]o evidence of a diastolic jet on the parasternal view. The apical view perhaps shows a trivial closing volume jet that does not last for more than [one] videoframe, possibly on a late systolic and not a truly diastolic frame, thereby not qualifying [under the] FDA positive criteria." Dr. Schwartz concurred with Dr. Gopal's findings and added that the LVOT measurements were improper.

THE WITNESS: This is negligible and would never be called mild aortic insufficiency.

Dr. Lazar conceded that this echocardiogram was of poor quality, though he believed it to be of diastolic quality.

> MR. RAMSAY: Page 30, which I think is the second page that is referred to by Dr. Lazar.
> Q. Now, in this particular one, again, you're suggesting to the court that all that we see there outside the confines of the planimetry is not artifact, but, in fact, is what one would expect with a reasonable gain as far as color flow?
> A. Yes.
> Q. And, in fact, is it your contention, sir, that one does not see speckling within tissue itself because the gain is so high?
> A. No. As I indicated earlier, I think there's a little speckling of the septum.
> Q. Here again --
> A. And I think the gain is a little high.
> Q. A little high. All right, sir.
> JUDGE WALSH: This is not a good quality echocardiogram. I mean, would you debate that?
> I mean, you may find it acceptable, but it's certainly not a good quality; is it.
> THE WITNESS: This is not a technically optimal echo. Let me go on the record as saying that.
> Is it technically acceptable or adequate? Yeah. That's a threshold question, and I think it is.

Dr. Lazar believes that Callison has MMR and MAR based on this echocardiogram, but the technical inadequacies of this echocardiogram doom his analysis. Dr. Lazar candidly admitted that in at least some views selected for an LAA measurement he could not determine their accuracy because of the color artifact.

> JUDGE WALSH: Can we have that file marked as a defendant's file as well?
> MS. CRAVENS: 4031.
> JUDGE WALSH: 4031. So, Plaintiff's Exhibit 4006 comes out of Defendant's Exhibit 4031. Okay.
> And this is the planimetry with respect to both the RJA and the LAA; correct?

> THE WITNESS: Yes.
> Q. And can you comment --
> JUDGE WALSH: I'll tell you, I've got a few problems with the way the LAA was done here. This really looks like a very poor frame to trace.
> I mean, how do you know you're not tracing right through tissue?
> THE WITNESS: I think if you look at this frame itself, I would share in that concern. I think if you look at other frames to --
> JUDGE WALSH: I guess we'll get a chance to see that.
> THE WITNESS: -- which open up the left atrium, then --
> JUDGE WALSH: All right. You'd agree that if this frame was looked at in and of itself, there's -- it's certainly difficult for you to make a judgment. The tissue isn't being traced for the LAA.
> THE WITNESS: I think the margins of the LAA are indistinct in this view, yes.

Moreover, neither the alleged mitral nor the aortic regurgitation lasts through most or all of their respective cycles. What are observed here are isolated color phenomena that cannot be meaningfully interpreted.

To the extent that this echocardiogram can be used at all, it can be used to exclude a finding of MMR and/or MAR. The Court finds that this has been accomplished here. First, neither the alleged mitral nor aortic regurgitation last for more than a few frames. The RJA and LAA tracings cannot be reliably made given the serious gain problems and, in any case, are significantly overtraced. The JH tracings cannot be read in any meaningful way because of the potential adverse effect of artifact. In short, the Court finds that Wyeth has established that this echocardiogram is so technically deficient that the only conclusions which can be drawn from it are that no significant mitral and/or aortic regurgitation are present. No reasonable medical opinion could be otherwise.

H. PAMELA CHUDYBA

Chudyba relies on a June 24, 2002 echocardiogram performed by The Women's Cardiovascular Center and a report by Dr. Linda Crouse. Dr. Crouse found Chudyba had MMR and MMAR using CAS criteria -- RJA/LAA = 22%; JH/LVOT = 30%.

The June 24, 2002 echocardiogram was examined by three (3) experts: Dr. Vasey, Dr. Gopal and Dr. Charash. All three (3) physicians found the echocardiogram to be of adequate diagnostic quality, although Dr. Charash commented that the quality was at the low margin.

Both Drs. Gopal and Vasey found Chudyba's MMR claims to be unsupported. Dr. Gopal reported that

> [o]nly trivial mitral regurgitation is present. The jet area in frame 9:03:41 of 3.46 cm^2 has been overtraced and primarily includes low velocity components. The other two frames which were traced but were not used in the calculation of the ratio are probably more accurate. Frame 9:01:47 with jet area 1.45 cm^2 or frame 9:03:02 with jet area 2.38 cm^2 would have been more appropriate. Assuming that the traced left atrial area of 15.72 cm^2 is accurate, jet ratios of 9.2% - 15.1% are obtained. These ratios do not fit FDA criteria as outlined by the court.

Dr. Gopal waivered during her testimony, initially stating that it might be possible for another physician to reasonably conclude that Chudyba had MMR based on this echocardiogram, but quickly recanting that view. Dr. Vasey agreed with Dr. Gopal that there was "no high velocity holosystolic signal visualized on [Chudyba's] echocardiogram." He also supported Dr. Gopal's conclusion that the purported jets were mostly overtraced.

Dr. Charash, on the other hand, believed that Chudyba had MMR and supported the tracings made. While he conceded that the observed jets were not holosystolic, he did not change his opinion.

> Q. You believe that this patient has FDA-positive regurgitation in both valves; correct?
> A. Yes, sir.
> Q. And you, of course, have agreed that this is a non-holosystolic -- what you believe to be mitral jet. But let's look at the actual frame you referenced in your report at time stamp 9:03:38.
>
> * * * *
>
> Q. Do you have that image before you, Dr. Charash?

A. Yes, sir, I do.

* * * *

Q. And, Doctor, as I understand it, you basically adopted the sonographer's measurement of a regurgitant jet area as imaged on this particular frame; correct?
A. Yes.
Q. Wouldn't you agree, Doctor, that the color flow that is planimetered on this particular image is laminar blue, and not evident of turbulent and mosaic signal?
A. I would say on a scale of black and white it has less turbulence than many others. I mean, there's a little bit of a hint of turbulence in the center.

But I agree it's not -- even on the image on the -- if you look at the screen on the right, that little -- that's not coming in. I'm first trying to find the margins here. I would say it's moderately turbulent, but not very.
Q. Wouldn't you agree, Dr. Charash, that because of the pressure differential between the left ventricle and the left atrium in systole, that a true regurgitant jet by convention would be non-laminar, turbulent, high-velocity flow that is imaged in a mosaic signal on a color [D]oppler echo?
A. I believe an ideal jet would be.
Q. This is a non-ideal jet then?
A. Yes.
Q. It is not holosystolic?
A. No, it's not.
Q. But you believe this is evidence of FDA-positive moderate mitral regurgitation?
A. For this study, yes. I look at the quality of the echo, and I think that it has to be put in the backdrop of the image that you're seeing.

* * * *

Q. This is another study, then, that if you had this patient in your clinic practice, you would either redo another surface echo or do another type study in order to make a more specific conclusion; correct?
A. If I needed to have absolute certainty, yes, I would. This study is not enough for absolute certainty. But I would say, more likely than not, it reflects regurgitation.

Both Drs. Gopal and Vasey concluded that Chudyba did not have even MAR based on a review of this echocardiogram. Dr. Gopal noted that the "[a]ortic regurgitant jet is only fleeting and does not last for more than [one] videoframe. The degree of aortic regurgitation is trivial. Jet height is overestimated and left ventricular outflow tract height is underestimated, thereby leading to an overestimation of the area." Nevertheless, Dr. Gopal measured the purported jet and concluded that proper JH/LVOT measurements made the jet 7.5%. During her testimony, however, Dr. Gopal stated that a reasonable physician could find MAR based on interreader variability. Ultimately, however, she concluded that there was no MAR because of the fleeting nature of the phenomenon.

> Q. And this is not something that could reasonably be characterized as aortic regurgitation, correct?
>
> * * * *
>
> A. No, this is trivial aortic regurgitation. It's fleeting. It's closing volume. It's like closing the door, little puff of air escaping, it's that kind of aortic regurgitation.
>
> Q. Would you agree that in light of the fact that it doesn't last for more than one video frame and it's just a puff, that it would not be medically reasonable to diagnose this individual with FDA-positive aortic regurgitation?
>
> A. Right, it doesn't meet criteria. It would not be medically reasonable.

Dr. Vasey agreed with Dr. Gopal that "[t]he purported aortic regurgitation is an intermittent, tiny flicker that is not seen initially at all in the parasternal long axis view. There is no jet of aortic regurgitation present on the echocardiogram."

Dr. Charash, again, disagreed. He acknowledged that the "jet" was seen on only one (1) frame but blamed this on the relatively poor quality echocardiogram.

> Q. Isn't it true that Dr. Gopal concluded that this was not true aortic regurgitation but was closing volume that was only imaged in one video frame?
>
> A. Well, I'm confused then, because the doctor also measured the jet which the doctor says doesn't exist.
>
> Q. We'll let Dr. Gopal speak to that, Dr. Charash.

> But you would not be able to tell this court whether or not this is closing volume or not; would you?
> A. I could. Based on the quality of the study and the shape of the image and its appearance, I think it's more than closing volume. I think, given the technical difficulty of this study, seeing that image, I think more likely than not reflects true regurgitation.
> Q. It lasted one frame; doesn't it, Doctor?
> A. Yes, sir.

He accepted the measurements of the technician conducing the echocardiogram and found MMAR with a JH/LVOT = 30%.

The Court believes that Wyeth has established that no reasonable medical opinion could support either a mitral or aortic regurgitation claim here. Both the mitral and aortic claims are based on fleeting changes of purported jets. Neither last more than a frame. The images are far from the holosystolic or holodiastolic jets one would expect. The Court also finds that the JH of .56 supported by Dr. Charash is medically unreasonable, and accepts the JH of .15 as measured by Dr. Gopal. The Court does not base its ruling here on the closer question of whether a more reasonable JH measurement might have been sustainable based on interreader variability.

I. LAURANIA M. CID-CRUZ

Cid-Cruz relies on a November 21, 2002 echocardiogram report by Dr. James Colasacco. Dr. Colasacco found Cid-Cruz had severe mitral regurgitation ("SMR") using CAS criteria -- RJA/LAA = 49%. Dr. Colasacco found this to be a "[g]ood quality echocardiogram."

The November 21, 2002 echocardiogram was reviewed by three (3) experts: Dr. Vasey, Dr. Gopal and Dr. Colasacco. Both Drs. Gopal and Vasey concluded that this echocardiogram was conducted in a technically inadequate manner and that reliable medical conclusions regarding the presence and severity of valvular regurgitation could not be drawn from it. Dr. Gopal noted that the color gain settings "were too high and coupled with marginal Nyquist limits of 51 cm/sec seriously compromised the value of the echocardiogram." Dr. Vasey was equally blunt finding "[t]he color Doppler gain was vastly excessive…." In Dr. Vasey's view, "the color flow data was uninterpretable." Both physicians nevertheless

attempted to examine the SMR claim, but despite the apparent severity, they found essentially nothing. Dr. Vasey reported that

> [t]he color Doppler gain is far too high, making a reliable assessment of the presence or severity of regurgitation difficult. Additionally, the selected RJA measurements included all non aliased flow. In fact, the purported mitral regurgitation is measured in a single, isolated frame, making it difficult to document whether the signal persists over multiple frames in real time throughout systole or to determine the context of this single frame. Even with the high color Doppler gain, no mitral regurgitation is present on the echocardiogram.

During the hearings, Dr. Colasacco lowered his assessment from SMR to MMR but initially insisted the gain settings were appropriate.

> Q. So Doctor would you say that the echocardiogram is interpretable?
> A. Yes, I do.
> Q. And is the gain [set] within the realm of medical reason for appropriate methodology in diagnosing valvular regurgitation?
> A. I do think it's reasonable.
> Q. And do you think that the methodology employed specifically with regard to the gain was appropriate?
> A. I think it's both appropriate and adequate, yes.

Ultimately, he had to concede the obvious -- the gain setting was high.

> Q. Is it your testimony that there's not high gain reflected in this apical loop?
> A. Oh, no. The testimony is not that they are is -- that the gain is too high. There is an elevated gain. My testimony is that the it -- the study and the gain is sufficient to make a determination.
> Q. But there is high gain in this study?
> A. Correct.

> Q. But you are able to look at this in real-time and determine which is mitral regurgitation and which is artifact?
> A. In real-time loop but slowing it down and going frame by frame.
> Q. My question, Doctor, is whether in real-time you're able to determine where there's mitral regurgitation and where there's artifact.
> A. The answer is yes, I can determine that there's mitral regurgitation.

The Court reviewed this echocardiogram and finds that Wyeth easily sustained its burden to show that this echocardiogram was technically inadequate and no reasonable medical conclusions could be drawn from it. The color gain filled the entire box, making any interpretation impossible. Any attempt at an analysis here is doomed from the start.

J. KELLI CRIDER

Crider relies on an April 18, 2002 echocardiogram performed by The Women's Cardiovascular Center and a report by Dr. Linda Crouse. Dr. Crouse found Crider had MMR and MMAR using CAS criteria -- RJA/LAA = 20%; JH/LVOT = 39%.

The April 18, 2002 echocardiogram was reviewed by three (3) experts: Dr. Vasey, Dr. Gopal and Dr. Charash. All three (3) physicians agree that this echocardiogram is technically adequate.

Both Drs. Gopal and Vasey agreed that the echocardiogram failed to show mitral regurgitation. Dr. Gopal found that

> [t]here was only trivial closing volume mitral regurgitation. The frame that was used for the jet ratio calculation overtraced the jet area and used primarily low velocity non-aliased components of the jet and therefore overestimated jet area. A frame (3:08:58) that was traced resulted in a jet area of 2.79 cm^2. This too was overtraced and included low velocity components. However, if it had been used in the jet ratio calculation, a ratio of 17% would have resulted and not qualified for

> FDA positive criteria. A more appropriate frame to have traced would have been 03:09:58. The jet area in this frame would have been smaller and have not resulted in positive FDA criteria.

Despite the conclusion that the jet was "only trivial closing volume," Dr. Gopal traced a RJA and LAA ratio of 17%. She amplified her calculation observing

> [t]his ratio is arrived at using the values in frame 3:08:58. However, I believe that the jet area is actually less than 2.79 cm^2 since primarily only low velocity components are included. Frame 3:09:58 should have been analyzed instead, but was not. Simple visual inspection indicates that the jet area appears to be significantly less than 2.79 cm^2.

During the hearing, however, Dr. Gopal appeared to support a view that despite her findings a reasonable physician could conclude that Crider had MMR.

> JUDGE WALSH: All right, Kelly Crider, was this echocardiogram conducted in a technically adequate manner so that reliable medical conclusions could be drawn from it.
> THE WITNESS: Yes, this was a technically adequate study.
> JUDGE WALSH: All right. There was a mitral and an aortic regurgitation claim made here. Turning to the mitral regurgitation claim, what were your findings.
> THE WITNESS: Okay, I did not believe this patient met FDA-positive criteria. There's only trivial closing volume mitral regurgitation. The frame that was used for the jet ratio calculation over-traced jet area and primarily used low velocity nonaliased components of the jet, leading to overestimation. A frame that was traced, Frame No. 30858 resulted in a jet area of 2.79 centimeters squared. This, too, was overtraced and included low velocity components. However, if you did use this in the jet ratio calculation, you would have come out with a ratio of 17 percent, so that would not have

> qualified for FDA-positive criteria. I felt that, you know, examining all the video frames, a frame like 30958 should have been traced and the jet area here would have been a lot smaller and would not have qualified.
> JUDGE WALSH: All right. Could a physician acting reasonably with your similar skill and experience have concluded that this individual had moderate mitral regurgitation.
> THE WITNESS: Yes, I think so. I mean, I -- I looked at the jet ratios independently and came out with a jet ratio of 17 percent and so -- that's probably less than 17.
> JUDGE WALSH: Forgive me for interrupting. Wasn't that based on the 2.79 that you said was overtraced.
> THE WITNESS: Right, so I'm sort of -- I'm being as generous as possible as far as the jet ratio, as far as the jet area is concerned. I mean, I accepted the left atrial area measurement of 16.12. I felt that the jet area was again, over-traced. That's why I've written there on Question No. 5 that the jet area is less than 2.79 percent. But even accounting for that, it still works out to less than 17 percent.
> JUDGE WALSH: I know, and the question that I'm asking is this. We know that you found there was less than moderate mitral regurgitation. The question, which is important in these proceedings is whether a physician acting reasonably with the echocardiogram that you evaluated could have found moderate mitral regurgitation.
> THE WITNESS: I think that's probably within the realm of interobserver variability, because again, the ratios were somewhat close.

Toward the close of her examination, Dr. Gopal returned to her view that a diagnosis of MMR based on this echocardiogram would be medically unreasonable.

> Q. And if you look down at Question No. 3, you characterize mitral regurgitation as trivial closing volume?
> A. Correct.

> Q. And would you agree in light of the fact that you characterized it as trivial closing volume, it would not be medically reasonable to diagnose this individual with moderate mitral regurgitation under FDA criteria?
> A. That's correct.

Dr. Vasey was consistent in his view that "there [was] no high velocity, holosystolic signal visualized." He also agreed with Dr. Gopal that the purported mitral jets were significantly overtraced.

Dr. Charash disagreed and found Crider had MMR. Again, Dr. Charash found Crider's echocardiogram badly done, noting that the echocardiographer showed Crider's heart rate at 110 beats/minute and was as well "a poor technical study." Nevertheless, he agreed that the RJA of 3.26 cm^2 might have been overtraced. The Court rejects Dr. Charash's MMR finding and adopts Dr. Vasey's criticisms of that finding as its own.

> Dr. Charash states that FDA Positive mitral regurgitation is seen on the echocardiogram. No mitral regurgitation is visualized in the three-chamber apical long-axis view (3:08:22) or in the apical two-chamber view (3:09:11). I have reviewed the frame relied upon by Dr. Charash at 3:14:40, which is an incomplete spectrum consisting predominantly of low velocity, blue signal that is also markedly overtraced. Dr. Charash's planimetered RJA and LAA measurements are the exact same measurements as the original sonographer traced. Additionally, the original sonographer measured a left atrium of 16.12 cm^2 at 3:17:17 (again, the exact same measurement Dr. Charash found at 3:14:40); however, the tracing is measured early in systole rather than at end-systole when the left atrium would be at its maximal dimension.
>
> Continuous wave Doppler at 3:15:03 through the mitral valve demonstrates that any regurgitant flow into the left atrium stops in early systole, again not indicative of true mitral regurgitation, which should be entirely or nearly entirely holosystolic.

As for the MMAR claim, both Drs. Gopal and Vasey testified that it is unsupported by the echocardiogram. According to Dr. Gopal, "[o]nly trivial aortic regurgitation was noted in [the PLAX] view and the apical view that did not last for more than [one] videoframe. The frame that was traced 3:19:48, grossly overestimated the jet height and included low velocity components and underestimated LVOT height thus overestimating the ratio."

Dr. Vasey concurred and observed that "[t]here is no high velocity, holodiastolic jet of aortic regurgitation on the echocardiogram. The first measurement is a single isolated frame, making it difficult to document whether the signal persists over multiple frames in real time throughout diastole or to determine the context of this single frame. Additionally, the second measurement of purported aortic regurgitation is measured in systole."

While Dr. Charash finds aortic regurgitation is present, the Court rejects his finding because it is evident that no regurgitation persists for more than a single frame.

The Court finds that Wyeth has established that no reasonable medical opinion that Crider has MMR, or at least MAR, could be based on this echocardiogram.

K. NATHAN DAVIDSON

Davidson relies on a December 17, 2002 echo report by Dr. Gary More. Dr. More found that Davidson had MMR using CAS criteria -- RJA/LAA = 22%.

The December 17, 2002 echocardiogram was reviewed by three (3) experts: Dr. Schwartz, Dr. Gopal and Dr. Lassetter. Dr. Gopal found that the echocardiogram was not conducted in a technically adequate manner such that reliable medical conclusions regarding the presence and severity of valvular regurgitation could be drawn from it. Dr. Schwartz concluded that the echocardiogram could be used to exclude MMR but the gain was very high. Dr. Lassetter conceded the gain was high, but believes that it is adequate to make a MMR conclusion.

Both Drs. Gopal and Schwartz exclude a MMR diagnosis here because any "jet" seen is fleeting and likely exaggerated by the high gain. Dr. Gopal noted "[t]he mitral regurgitant jet is very brief and does not last for more than [one] videoframe. This is more consistent with closing volume." Dr. Schwartz

concurred, observing that "[t]he duration of the flow was relatively brief (only [one] frame in early systole), and not holosystolic, most consistent with physiologic backflow, rather than true mitral regurgitation. Additionally, no high velocity, turbulent flow is seen on the echocardiogram."

Dr. Lassetter disagrees and noted mitral regurgitation in parts of several loops. But in view of the high gain and the brief appearance of purported jets at the onset of systole, the Court agrees with Dr. Schwartz's critique of Dr. Lassetter's conclusions.

> In support of his conclusion [that MMR is present], Dr. Lassetter cites a number of pages of the study purportedly showing moderate mitral regurgitation. I have reviewed these pages, pages 36-38, 44, 49, 53, 74-76, 43, 48, 51 and 86, and none of them demonstrate mitral regurgitation. None of these pages demonstrate more than a flash of mosaic flow in early systole that lasts no more than one to two frames. This flow is likely backflow exaggerated by the high gain on these pages.

The Court finds that Wyeth has satisfied its burden of proof and has shown that the conclusion that Davidson has MMR is medically unreasonable.

L. CHRISTINE DiDODO

DiDodo relies on a November 21, 2002 echocardiogram report by Dr. Stanley S. Schrem. Dr. Schrem found DiDodo had MMR using CAS criteria -- RJA/LAA = 23%. Dr. Schrem found the technical quality of the study to be "fair."

The November 21, 2002 echocardiogram was reviewed by three (3) experts: Dr. Vasey, Dr. Gopal and Dr. Lassetter. Both Drs. Gopal and Vasey found that the echocardiogram was conducted in a technically inadequate manner so that no reliable medical conclusions regarding the presence and severity of valvular regurgitation could be drawn from it. Dr. Gopal indicated that "[c]olor gain was excessive as indicated by a speckled appearance. Nyquist limit settings were somewhat lower (51 cm/s) than desirable. Both can overestimate the severity of mitral regurgitation." Dr. Vasey concurred.

Dr. Lassetter, however, believed that despite the high gain and low Nyquist the echocardiogram was of diagnostic quality. Initially, Dr. Lassetter reported that

"the gain setting was fine…." The Court finds that this answer is not credible in light of his later testimony on this subject when he discussed the gain setting as follows:

> Q. All right. Now, based upon your review and interpretation of this echocardiogram dated November 21st of '02, did you consider it to be of diagnostic quality?
> A. Yes.
> Q. And when we talk about diagnostic quality, what do you look for on an echocardiogram to make that decision on whether or not it is of diagnostic quality.
> A. Multiple factors. Whether you can see the cardiac structures that are intended to be seen in the various views, the clarity of the structures, whether the color gain is appropriate or inappropriate, Nyquist settings, and the evidence that is presented when you interrogate the valves with said modalities.
> Q. And let me ask you, in reading and interpreting this echocardiogram, did you see any level of regurgitation that you felt was FDA positive?
> A. Yes.
> Q. All right. And what -- strike that. Did you see FDA positive mitral regurgitation on this echo?
> A. Yes.
> Q. And what level of mitral regurgitation did you diagnose based off of your interpretation of this echo?
> A. Moderate mitral regurgitation.
> Q. And did you see the evidence of moderate mitral regurgitation in the real time images that you viewed off of this echocardiogram?
> A. Yes.
> Q. Did you also see moderate mitral regurgitation in the apical views as required by the class action settlement?
> A. Yes.
> Q. Now, did you look to see what the Nyquist settings were for this echocardiogram?
> A. Yes.

> Q. And were the Nyquist settings appropriate for diagnostic purposes of diagnosing the MR, mitral regurgitation?
> A. Yes.
> Q. Did you also look to see if the gain settings were appropriate for diagnostic purposes?
> A. Yes.
> Q. All right. And did you feel that the gain settings on this echocardiogram were appropriate for diagnostic purposes?
> A. I thought the gain was a little high, but not such that it would obscure the ability to diagnose.

Drs. Gopal and Vasey do not agree as to whether it is medically reasonable to diagnose DiDodo with MMR based on this echocardiogram. Dr. Gopal noted that

> [t]he left atrial area of 22.2 cm^2 is plausible and is not affected by considerations of color gain or improper Nyquist limit settings. The jet area on the other hand may be overestimated. However, there were several traced jet areas over 5 cm^2 (5.12 cm^2, 5.3 cm^2, 5.7 cm^2) that included only high velocity components. The spectral Doppler tracings show holosystolic mitral regurgitation. Therefore not withstanding the comments related to study quality, the study probably can still be interpreted and criteria for FDA positivity have likely been met.

Dr. Vasey, on the other hand, argued that

> [t]he color Doppler gain is far too high, making a reliable assessment of the presence or severity of regurgitation difficult. Additionally, the duration of the flow was relatively brief, and not holosystolic, most consistent with physiologic backflow, rather than true mitral regurgitation. The purported mitral regurgitation is measured in a single, isolated frame, making it difficult to document whether the signal persists over multiple

> frames in real time throughout systole or to determine the context of this single frame.

Dr. Lassetter concluded that DiDodo had MMR based on review of several loops done in systole.

> Q. Can we turn to page 37. And the time clock is 16:40:24. If we could just slow it down a little bit. Okay. We're on page 37, time clock 16:40:24, and we're on frame 48. Does that look correct to you, Doctor?
> A. That's what I have in front of me, yes.
> Q. And where are we in the cardiac cycle here?
> A. Looks like the end of diastole.
> A. Okay.
> Q. Just fixing to have the QRS and begin systole?
> A. Yes.
> Q. If we move forward one frame, do we see mitral regurgitation in frame 49 of this page 37?
> A. Yes.
> Q. Okay. And can you point your cursor to where you believe the mitral regurgitation is?
> A. I'll try.
> Q. Sure.
> A. It is this blue jet right here.
>
> * * * *
>
> Q. (BY MR. NABERS) How would you characterize this mitral regurgitation?
> A. I'm not real sure I understand your question.
> Q. Okay. Well, is the mitral regurgitation that you see here, is it turbulent flow?
> A. Yes.
> Q. If we advance one frame, do we still see mitral regurgitation?
> A. Not as clear, but yes, it's still there.
> Q. Okay. That's frame 50. Can we advance another frame? Do we still see mitral regurgitation here?
> A. Yes.
> Q. And again, the last three frames that we've looked at are all during systole. Is that correct?
> A. Yes.

Q. All right. And can we advance another frame. Do we still see mitral regurgitation here in frame 52?
A. Yes. You see the tail end of the jet towards the back wall of the left atrium.
Q. All right. So at least with regard to page 37 and the frames that we've looked at, we have seen multiple frames of mitral regurgitation; correct?
A. Yes.
Q. If we could go to page 62. Where are we in the cardiac cycle here, Doctor?
A. It looks like it's in systole, but my time cursor is covered up here.
Q. Okay. Does that help now that he's moved it for us?
A. Yes.
Q. Okay. So if we advance -- we're in systole now, correct?
A. Yes.
Q. All right. So let's back up a frame. Are we still in systole here?
A. The loops.
Q. Yeah, it did. It jumped.
A. It flipped over there. We're at frame 120 now.
Q. Okay. Let's go ahead and advance forward. Do you see that bump? That's the QRS. Keep going. Right there.
A. Yes.
Q. Now are we on top of the QRS here?
A. Just after it, yes.
Q. Okay. So are we in systole?
A. Yes.
Q. All right. And -- okay, there we go. And we're looking at frame 124, time clock 16:45:22. Is that correct?
A. That is correct.
Q. And we're on page 62. Do we see mitral regurgitation there?
A. Yes.
Q. And can you kind of circle it with the cursor for us?
A. I can try again. I'm having a little technical difficulties with my thumb here, but this is the beginning

of the regurgitant jet here. Again, this portion here being above the valve.
Q. All right. Do we see PISA above the valve in this image?
A. Yes. That's where I've placed the cursor.
Q. And below the cursor is the actual mitral regurgitant jet?
A. Down here, yes.
Q. All right. And is this color consistent with a mitral regurgitant jet?
A. Yes. The majority of it is blue, but it indicates turbulent flow with multiple eddies where the flow actually reverses on itself. So you'll see multiple colors of the jet.
Q. Can we advance one frame? Do we see mitral regurgitation in this frame, which is 125 of page 62?
A. Yes.
Q. Okay. Can we advance another frame. Do we also see mitral regurgitation here on frame 126 of page 62?
A. Yes.
Q. All right. So again, are we seeing mitral regurgitation in multiple frames on this page 62 of the echocardiogram?
A. Yes.
Q. Can we turn to page 71. Can we go back one frame. Okay, forward one frame. One more. Okay.
Now, Doctor, we are at page 71, time clock 16:47:30, and we're looking at frame 56. Is that correct?
A. Yes.
Q. And where are we in the cardiac cycle?
A. At the beginning of systole or within systole.
Q. All right. Do we see mitral regurgitation depicted here?
A. Yes.
Q. Again, can you circle what you believe to be the mitral regurgitant jet?
A. This is PISA above the valve, and this -- I'm sorry. I'm having my technical thumb difficulties here. This is the regurgitant jet down here below the valve. This is the valve level here.

Q. All right. And again, is that color that we see there representative of mitral regurgitation?
A. Yes.
Q. Is that mitral regurgitation going that close to the left atrial wall?
A. It's going towards the back wall of the left atrium, yes.
Q. Okay. And again, I think you indicated we saw PISA above the valve?
A. Yes.
Q. All right. Can we advance one frame. We're now on frame 57 of page 71. Do we still see mitral regurgitation?
A. Yes.
Q. Are we still in systole?
A. Yes.
Q. Is the color still appropriate for mitral regurgitation?
A. Yes.
Q. Could we advance one frame. Do we still see mitral regurgitation in frame 58 of page 71?
A. Yes.
Q. Is the color still appropriate for mitral regurgitation?
A. Yes.
Q. Are we still in systole?
A. Yes.
Q. Can we advance one frame. Where are we in the cardiac cycle?
A. Towards the end of systole.
Q. And we're looking at page -- we're looking at frame 59 of page 71, correct?
A. Yes.
Q. Do we still see a little mitral regurgitation here?
A. I think you're just seeing the very tail end of it.
Q. Okay. Again, so throughout page 71, did we see multiple frames of mitral regurgitation that occurred during systole?
A. Yes.

Dr. Vasey criticized Dr. Lassetter's opinion.

> Dr. Lassetter states that FDA positive mitral regurgitation is seen in the apical 4 and 2 chamber views and "seen best on pages 37 and 62." In my opinion, due to the excessive color Doppler gain setting, a reliable assessment of the presence or severity of regurgitation is difficult on this echocardiogram. Even with the high color Doppler gain setting, the duration of flow was relatively brief, and not holosystolic, most consistent with physiologic backflow, and not true mitral regurgitation.
>
> Dr. Lassetter relies on the echocardiogram images on pages 37 and 62 to best show the purported mitral regurgitation. However, on page 37, even with the excessive color Doppler gain setting, the purported mitral regurgitant "jet" is not holosystolic. Additionally, on page 62, although the color Doppler gain setting is extremely high, there is no high velocity flow within the left atrium that persists throughout the cardiac systolic cycle. The color Doppler gain setting is so excessive on both images that color pixels occur in non-existent flow.
>
> Continuous wave Doppler (images 38-41) through the mitral valve demonstrates that any regurgitant flow into the left atrium stops by mid-systole, again not indicative of true mitral regurgitation which should be entirely or nearly entirely holosystolic.

In the Court's view, this debate revolves around the quality of the echocardiogram. The Court has reviewed the media and finds its quality to be below the standards necessary to assure a technically adequate echocardiogram. If this echocardiogram was technically adequate, the Court would have found that Wyeth's challenge would fail. The Court agrees with Dr. Gopal that the LAA can be adequately visualized[11] and agrees with Dr. Lassetter that there is some

---

[11] As noted, Dr. Gopal believes there is enough evidence to sustain an MMR claim. The Court disagrees because, as Dr. Gopal recognized, the color gain and Nyquist limits work in combination to destroy any confidence in the RJA readings.

The Court has already observed that the technical quality of an echocardiogram is essential to obtaining reliable and reproducible results. *Kemp ex rel Wright v. State*, 174 N.J. 412, 427 (2002); *Oddi v. Ford Motor Co.*, 145 F.3d 136, 145-146 (3rd Cir. 2000); *In re Paoli Railroad Yard PCB Litigation*, 35 F.3d 717 (3rd Cir. 1994). The DiDodo echocardiogram, in the Court's view, fails this gatekeeping test. Dr. Gopal may conclude that in her

evidence that the jets probably are seen in multiple loops and in multiple frames. However, the Court finds that no accurate RJAs may be traced based on the technically inadequate echocardiogram color Doppler settings. Accordingly, the Court finds Wyeth has satisfied its burden of establishing that no reasonable medical conclusion that DiDodo had MMR could be drawn from a review of this echocardiogram.

M. CAROL DUFFEY

Duffey relies on a November 21, 2002 echocardiogram report by Dr. Scott L. Roth. Dr. Roth found Duffey had MMR using CAS criteria -- RJA/LAA = 25%. Dr. Roth reported this to be a "technically adequate" study.

The November 21, 2002 echocardiogram was reviewed by three (3) experts: Dr. Kaul, Dr. Gopal and Dr. Lassetter. Dr. Gopal noted that Duffey's echocardiogram was not conducted in a technically adequate manner because of high color gain. Drs. Kaul and Lassetter, on the other hand, found the study to be technically adequate. Dr. Lassetter, in fact, reported it "to be of diagnostic quality with adequate technical settings."

Both Drs. Gopal and Kaul concluded that Duffey did not have MMR according to her echocardiogram, with Dr. Gopal observing that low nonaliased signals were traced. Nevertheless, she identified the frame (RJA = 3.48 cm^2)

> closest to the values I agree with [and they] are those taken from Frame 58 in which the jet area is 3.48 cm^2. Note that even in this frame, the jet area includes some low velocity signals and is probably overestimated. Regardless, accepting a left atrial area of 19.2 cm^2, the ratio does not exceed 20 cm^2 (sic) [%] thus not meeting the qualifying FDA criteria.

While Dr. Gopal initially reported that it was not medically reasonable to find Duffey had MMR based on this echocardiogram, she testified differently at the hearing.

---

clinical judgment moderate mitral regurgitation exists here but this is her clinical judgment in the face of a technically inadequate echocardiogram.

> JUDGE WALSH: All right. Passing onto Carol Duffey. Was this echocardiogram conducted in a technically adequate manner so that reliable medical conclusions could be drawn from it?
> THE WITNESS: Again, I -- again, I felt that the color gain was too high and so for that reason, I felt that it was not conducted in an [sic] entirely technically adequate manner. The Nyquist limit was 51 so that's -- that's technically adequate by the ASE criteria, but the color gain was not and so that -- that's why I said that it was not conducted in a technically adequate manner.
> JUDGE WALSH: Did you proceed to evaluate the mitral regurgitation claim made here?
> THE WITNESS: Yes, I did.
> JUDGE WALSH: What did you find?
> THE WITNESS: Let's see, I found that the criteria were not met and I used -- I actually examined some of the traced frames. Looking at Frame No. 58 where the jet area was 3.48 centimeters squared, I thought was probably closest to what I agree with and even if these frame -- in this frame some of the low velocity signals were included. Accepting the left atrial area of 19.2, the ratio -- there's a mistake on the thing. I should say that the ratio does not exceed 20 percent.
> JUDGE WALSH: I think we understand that.
> THE WITNESS: Yeah, okay. So the FDA qualifying criteria were not met.
> JUDGE WALSH: Now, Doctor, could a physician with your skill sets, acting reasonably conclude that this patient was FDA-positive with moderate mitral regurgitation by criteria?
> THE WITNESS: I think -- yeah, this I think is within the realm of interobserver variability. People can disagree about the jet areas.

Dr. Kaul found that the claimed mitral jet was not holosystolic and comprised about one-third of systole.

> Q. Let's look at Page 30 Dr. Kaul, around Frame 20 or so?

A. This is 16, 17, 18, 19, 20, so can I go back a bit, one frame, please? Again, okay come forward, one frame, another frame, another frame, okay. So this is where we can start systole and we can go now forward, one, two, three, four, five, six, seven, eight, nine, ten, 11, 12, and again, you saw in the beginning only four of those had the jet so it's -- and these are the ones that he referred to, so these are the ones I'm count erring.
JUDGE WALSH: Dr. Lasseter [sic]?
THE WITNESS: Yes.

* * * *

JUDGE WALSH: By the way, has anyone really defined what holosystolic is? I mean the books tend to say through most or all of systole. I guess four out of 12 isn't most.
THE WITNESS: Four out of 12 is one-third, sir.
JUDGE WALSH: I -- even I got that far, Doctor before they took my slide rule away from me. All right.
THE WITNESS: But the best way to look at holosystolic is with continuous wave Doppler and this frame by frame is fine what we're looking but the resolution is not perfect because you're dividing systole into 12 parts rather than continuous -- with continuous what I have Doppler you can see where it starts and where it ends and there are examples later on where we have continuous wave Doppler tracings which we can use to make our algorithms.
JUDGE WALSH: Good.
Q. Dr. Kaul, in light of that if we just take a look at the CW, and I'll let you try to identify for us from the DICOM page if it's if you could please, sir, if it's there.
A. This is -- it starts from here at systole, and each, it ends here and you can see, if you have a real systolic, this whole thing here should be completely white and dark and you can see only a part of it is -- and it's not even -- so I'll have to show you a real one how it looks like next to it to make a comparison.
JUDGE WALSH: All right. It indicates in some probably a third or so in one of them probably about a

> half where you got some kind of activity. All right. I have the picture.

Dr. Lassetter disagreed with Dr. Kaul's view that the purported jet was not holosystolic and defended the diagnosis of MMR.

> Q. Now, Doctor, we have stopped the echocardiogram at page 28, time clock 14:15:40, and we're looking at frame 1. Is that correct?
> A. Yes, it is.
> Q. And is this a view that you base your diagnose (sic0 [diagnosis] of moderate mitral regurgitation off of?
> A. Not this specific frame, but this view, yes.
> Q. And where are we in the cardiac cycle here?
> A. This is the beginning of systole.
> Q. And what do we see here?
> A. We see -- I'll use the cursor. We see a -- I'm not real sure why we have a sun now.
> Q. We have a little sunshine there.
> MR. GHOLSON: Clock off of it.
> THE WITNESS: There we go. Okay. This is the level of the valve here. This gray structure right here is the valve. So there is PISA above the valve level and then the beginning of a regurgitant turbulent jet just below the valve here.
> Q. (BY MR. NABERS) So where the cursor is now, is that part of the mitral regurgitant jet?
> A. Yes.
> Q. Is that the right color to be mitral regurgitation?
> A. Yes.
> Q. Is it in the right area to be mitral regurgitation?
> A. Yes.
> Q. Are we in systole in the cardiac cycle?
> A. Yes.
> Q. Is the Nyquist limit appropriate?
> A. Yes.
> Q. Is the gain setting appropriate?
> A. Yes.

Q. Okay, let's go forward one frame. Now we're at frame 2 on page 28, time clock 15:40:40. What do we see here?
A. This is further extension of the mitral regurgitant jet, again demonstrating PISA above the valve with now extension of the mitral regurgitant jet further into the left atrium.
Q. With (sic) [were] we still in systole in the cardiac cycle?
A. Yes.
Q. Can you put the cursor where you believe the mitral regurgitation is?
A. That's the middle of the jet.
Q. Okay. Do we see a turbulent flow here?
A. Yes.
Q. And is this the right color to be a high velocity mitral regurgitation?
A. Yes.
Q. Nyquist setting is still appropriate?
A. Yes.
Q. Gain setting is still okay?
A. Yes.
Q. Okay. Can we go advance one frame. Do we still see mitral regurgitation here on page 28, frame 3?
A. Yes.
Q. Are we still in systole?
A. Yes.
Q. Can we go another frame. Do we see mitral regurgitation here on page 28, frame 4?
A. Yes.
Q. Are we still in systole?
A. Yes.
Q. Is the jet still the right color to be mitral regurgitation?
A. Yes.
Q. Does it still indicate high velocity turbulent flow?
A. Multiple velocities are indicated, but yes, traveling well back into the left atrium.
Q. Is there still PISA above the valve?
A. Yes.

Q. Let's go, advance another frame. What do we see here?
A. Still see PISA above the valve and continuation of the mitral regurgitant jet tracking the lateral left atrial wall back towards the back wall of the left atrium.
Q. And we're looking at page 28, frame 5, correct?
A. Correct.
Q. Do we still see PISA above the valve?
A. Yes, I indicated that.
Q. Okay. And again, the upper part of this mitral regurgitant jet is still high velocity; is that correct?
A. Yes.
Q. And the Nyquist setting is still good?
A. Yes.
Q. And the gain is still appropriate?
A. Yes.
Q. And have we now seen this mitral regurgitant jet in multiple frames?
A. I think you'll find that it is in all frames of systole.
Q. And so what would that make this mitral regurgitation?
A. Holosystolic.
Q. And based upon your review of these realtime images, is this holosystolic mitral regurgitation?
A. Yes.

The Court has reviewed this echocardiogram and notes that there was excessive gain. Having reviewed hundreds of echocardiograms, the Court is comfortable that non-aliased flows were traced. Nevertheless, the Court believes there is evidence which supports Dr. Lassetter's claim that at least some of the jets occurred through a good deal of systole. This is a close call based on the evident overtracing and the Court, if it were the ultimate factfinder, might side with Wyeth. However, in this forum Wyeth has not satisfied the Court that a claim that Duffey has MMR based on this echocardiogram is medically unreasonable.

N. NANCY EDER

Eder relies on a November 25, 2002 echocardiogram report by Dr. John E. Lassetter. Dr. Lassetter found Eder had MMR using CAS criteria -- RJA/LAA = 23%.

The echocardiogram was reviewed by three (3) experts: Dr. Kaul, Dr. Gopal and Dr. Lassetter. Dr. Gopal found this echocardiogram was not conducted in a technically adequate manner such that reliable medical conclusions regarding the presence and severity of valvular regurgitation could be drawn. She explained that "[c]olor gain was somewhat high as indicated by the speckling pattern outside the region of interest (right ventricle) on the first few parasternal images. In addition, the Nyquist limit settings are 51 cm/s and at times 41 cm/s, both of which are low. Both factors tend to overestimate regurgitation severity." Dr. Kaul noted these infirmities, but felt the echocardiogram could be used to exclude MMR. Dr. Lassetter found the echocardiogram "to be of diagnostic quality with adequate technical settings."

Both Drs. Gopal and Kaul agreed that there was no mitral regurgitation present, but rather closing volume. Dr. Gopal noted that

> [t]he frame used to determine jet ratio with jet area 3.33 cm^2 appears to be possibly an early diastolic frame and not a systolic frame. The systolic jet is brief and does not last for more than 1 or 2 videoframes during systole, consistent with closing volume mitral regurgitation. The frames that should be used in the calculation of the jet areas are either frame 44 (early systolic frame with jet area 2.55 cm^2) or frame 48 (early systolic frame with jet area 2.46 cm^2). In either case, using a left atrial area of 14.61, the jet ration [sic] is 17.4% or 16.8% respectively, neither of which qualify for FDA positivity.

During her testimony at the hearing, Dr. Gopal indicated that she traced some of these early systolic jets, but was comfortable that they represented closing volume or were taken in the wrong part of the cardiac cycle.

> JUDGE WALSH: Could a physician with your skill sets acting reasonably conclude that there was moderate mitral regurgitation?
> THE WITNESS: No, again, I don't believe so and even though I did look at the jet areas, this was consistent with closing volume mitral regurgitation that lasted one or two video frames and so I don't think this is a question of differences in interobserver variability regarding tracing.

Dr. Kaul concurred and found only closing volume.

> Q. Dr. Kaul, I believe your point was in the primary criticism of the study was that it was not holosystolic, but it was closing volume but can you demonstrate that for the Court, please?
> THE WITNESS: Yes. Your Honor, this is the first systolic frame. This is the first systolic frame and if we go frame by frame; let's go to the second. It's gone. 3rd, 4th, 5th, 6th, 7th, I mean it's only the first frame it was a tiny little jet so it's closing volume.
> JUDGE WALSH: It did appear to be aliased?
> THE WITNESS: Yes, yes.
> MR. WHEELER: Page 37 beginning at Frame 38, the first frame of systole and see if we can demonstrate that one other time in one of the pages referenced by Dr. Lasseter [sic].
> A. Okay, yeah, he used these pages to say there was FDA-positive mitral regurgitation. So where did we start?
> MR. WHEELER: I believe this is page -- one more page, TJ, 38, I believe.
> A. Yeah, this is it, 38. If we go to the next frame, 39, it's gone. So go back. Go back. This is the first frame in systole and you can see, it's a tiny amount. I mean it's just next to the mitral valve. It's aliasing, but you can also see that the -- this is 50, 51, the Nyquist limit, and we have a tiny little jet here which disappears on the second frame.
>
> See, if we go to the next frame, it's gone and so the rest of systole, there's nothing there.
> Q. Dr. Lasseter [sic], your Honor, referenced a couple of other still images that we'll have Dr. Kaul comment on, Page 42, some planimetry. Can you comment on that, Dr. Kaul?
> A. Yes. Your Honor, this is a frame where he has made a measurement and you can see that this measurement extends into the left ventricle. This is the mitral leaflet here, mitral valve here, this is the left atrium, this is the

> left ventricle, and so the real regurgitation quote, unquote is half of it. The other half is in the left ventricle.
> JUDGE WALSH: What are [you] saying, it's artifact?
> THE WITNESS: Yes, it's the same part of the closing volume. It comes back and you can get a little turbulence on this side as well as this side and if you have to measure it, you must measure it below the mitral valve, not above the mitral valve.
> JUDGE WALSH: Well, that certainly makes a lot of sense.
> Q. Dr. Kaul, you said "real regurgitation." Did you find any evidence of real regurgitation in this study?
> A. No, just closing volume.

Dr. Lassetter disagreed and found MMR based on this echocardiogram.

> Mitral regurgitation is demonstrated in numerous frames of this echo on pages 34-37, 63, and 42-48. MR is seen in multiple views as required by the Settlement Agreement protocol including the apical 4, apical long and parasternal long axis views. The mitral regurgitant jet was seen during systole as specified by Singh. The settings were appropriate and the study was of diagnostic quality. The regurgitant mitral flow is both blue and yellow and mosaic in color as allowed by Singh. The mosaic color of the jet indicates its velocity is beyond what could be described as backflow. Given the velocity, location, duration and presence of the regurgitant jet during systole, this cannot be backflow which is defined by Weyman as blood pool immediately behind the valve of short duration and low velocity due to closure of the mitral leaflets (at 431). The timing and duration of regurgitant flow is described in the Singh article as well as the Weyman and Feigenbaum texts. None of these references state regurgitation of either the mitral or aortic valve must be sustained "throughout" systole or diastole, respectively.

Dr. Lassetter's views with respect to this echocardiogram are not medically reasonable. First, it is clear that the color gain is set too high. Second, as noted,

virtually all the experts and the medical texts state that mitral regurgitation should be seen through most or all of systole. Third, whatever "jets" might be observed here are at the onset of systole and disappear after a frame or two. In short, the Court finds that Wyeth has established that no medically reasonable conclusion that Eder has MMR could be made from review of this echocardiogram.

O. SHAUN EGBERT

Egbert relies on a June 6, 2002 echocardiogram report by Dr. Carrie A. Totta. Dr. Totta found that Egbert had MAR but observed that "the aortic insufficiency jet diameter is not measured but appears to be approximately 10% of the [LVOT]."

The echocardiogram was reviewed by three (3) experts: Dr. Schwartz, Dr. Gopal and Dr. Lassetter. Both Drs. Schwartz and Gopal found the echocardiogram was not conducted in a technically adequate manner such that reliable medical conclusions regarding the presence and severity of valvular regurgitation could be drawn from it. The Nyquist limit according to both was 45 cm/sec. The *ASE Standards* make it clear that this is a technically inadequate echocardiogram. Dr. Lassetter finds that this study "is of diagnostic quality with appropriate settings." The Court rejects Dr. Lassetter's testimony in this regard.

The Court finds that the echocardiogram was performed in a medically unreasonable way. The Nyquist limit was far too low. As Weyman teaches, "[i]n the adult, the color flow Nyquist limit is typically between 0.6 and 0.9 cm/sec but can be raised by decreasing the sector depth or using a lower frequency transducer." Weyman Text at 245.

The Court is aware that Miele indicated in his testimony that the angle effects dominate where views are taken in the PLAX. While this may be true as a matter of physics, this does not excuse a departure from appropriate echocardiographic standards.[12] Those standards are set by the medical community

[12] Dr. Kaul indicated in testimony taken in connection with the Group 2 challenges:

> So over years, we have developed our own thing, and I don't agree with him [Miele]. I don't agree with him that a low Nyquist limit -- in fact, a low Nyquist limit makes a study technically uninterruptible for Doppler.
> JUDGE WALSH: Because of the introduction of potential artifact?
> WITNESS: That's correct. Now, if this would have looked like this, one could have said, [w]ell, it's already changing color, but that would have been at 45 centimeters per second. That's very low velocity.
> JUDGE WALSH: 46.

and are apparent in the literature (*see ASE Standards*; Weyman Text at 245). There is no justification for the departure from appropriate practice. In short, the echocardiogram was performed in a medically unreasonable manner.

In any case, both Drs. Gopal and Schwartz found no aortic regurgitation in the PLAX view. Dr. Gopal observed that "[t]he parasternal long axis view did not [reveal] any regurgitation. The apical long axis view showed [one] or [two] frames of trivial aortic regurgitation with a jet height of 1.5 mm and a LVOT height of 24 mm, thus leading to a ratio of 6.3% which does not meet FDA positive criteria despite Nyquist settings being too low and in favor of overestimating jet size." Dr. Schwartz concurred, finding that "[d]ue to the inappropriate Nyquist setting in the parasternal long axis view, a reliable assessment of the presence or severity of regurgitation, if any, is difficult. Additionally, the purported aortic regurgitation was measured in the apical long axis view, even though the parasternal long axis view was available."

Dr. Lassetter disagrees and claims that the jet is present in the apical views but the Court finds the PLAX view is available and shows no aortic regurgitation. Moreover, even in the apical long axis view, the jet is only intermittently available -- a telltale indicator that it is at best trace regurgitation. Dr. Lassetter's difficulty in isolating this transient jet is apparent from his testimony.

> Q. Okay. Well, let's let it play, then.
> A. It's about 16:10. So if you move the cursor, if you just click out here, it will fast forward a bit. It's going to be out near the middle of the time frame here. Click there. And it will jump to it here in just a second.
> All right, now you have to go back a bit because we're at 16:15 there. Right in there. Yeah, right where he's stopped right now, right in the middle of the left ventricular outflow tract is a turquoise-colored turbulent jet of aortic insufficiency.
> Q. So orient us to the valve, aortic valve.
> A. If he movers (sic) [moves] his cursor, there's kind of a diagonal gray line right where his cursor is there. That's the aortic valve. And directly above his cursor is kind of a yellow fleck with a turquoise-colored jet.

WITNESS: 46. That's very low velocity, and so this is what I said you could dial things in and out.

Q. Right there where the end of the arrow is?
A. Right there.
Q. There.
A. That is the jet of aortic insufficiency.
Q. And what view is this?
A. This is the apical long axis, or some people call it apical three-chamber view.
Q. The Nyquist there looks like 51?
A. Correct.
Q. So that would be an appropriate Nyquist?
A. Yes.
Q. Is the gain setting okay here to diagnose aortic regurgitation?
A. Yes.
Q. Does that look to be at least mild aortic regurgitation, based upon your assessment?
A. I'm not going to answer that based on this frame; but this segment, this is right in the middle of a segment that I quoted. But yes, I would say that.
Q. Okay. Was a continuous wave Doppler important to you in confirming the presence of AI, aortic regurgitation on this echo?
A. Yes.
Q. And what did it tell you?
A. It showed that it was present, that it is holodiastolic, and that it had a pressure half time measurement of 450 milliseconds.
Q. And your opinion on this echocardiogram that there's at least mild aortic regurgitation you believe is medically reasonable?
A. Yes.
Q. It's based on your training, education, and experience in echocardiography?
A. Yes.
Q. Based upon your review of the Weyman, Feigenbaum and Singh article?
A. Yes.

The Court finds that Wyeth has established that the echocardiogram under review is so technically inadequate that no reasonable medical conclusion

regarding the presence and severity of valvular regurgitation could be drawn from it. Further, Wyeth has established that even if this echocardiogram could be reviewed it would not demonstrate MAR since it was not observable in the PLAX view. Finally, even if this requirement could be set aside, it is clear from the echocardiogram that any "jets" seen in the apical long axis view are not holodiastolic. Thus, Wyeth has met its burden to establish that no reasonable medical opinion could be drawn that Egbert has MAR based on this echocardiogram.

P. LAURA ESKE

Eske relies on an October 28, 2002 echocardiogram report by Dr. Charles F. Dahle. Dr. Dahle found Eske had MMR based on CAS criteria -- RJA/LAA = 25%.

The echocardiogram was reviewed by three (3) experts: Dr. Kaul, Dr. Ong and Dr. Dahl. All three (3) physicians found the echocardiogram was technically adequate.

Both Drs. Ong and Dahl found that Eske had MMR based on this echocardiogram. Dr. Ong reported that "[t]he mitral regurgitant jet demonstrates the mosaic pattern typically seen with this lesion. Multiple measurements were obtained that appear to be appropriately performed, such as frame 22." Dr. Dahl reiterated his views that Eske has MMR based on this echocardiogram.

> [T]he echocardiogram performed on Laura Eskes [sic] on 10-28-02 was of diagnostic quality and demonstrated moderate mitral regurgitation with a Singh ratio of 28% according to methods of qualifying regurgitation and ranges for various levels of regurgitation as stated in the Singh article. Further it is my opinion that that diagnosis is medically reasonable utilizing the protocols and criteria required in this litigation.
>
> * * * *
>
> The mitral regurgitation on Ms. Eskes' [sic] October 28, 2002 echocardiogram was visualized in the apical four chamber view as required by the Settlement Agreement, but demonstrated also in multiple other views, including the parasternal, short axis and 2 chamber views. MR is

> seen in real time on page 6 (frames 1-7) in the parasternal view, on page 13 (frames 102-106) in the short axis view, page 19 (frames 68-72) in the 4 chamber view, page 30 (frames 207-216) in the 2 chamber view, and page 32 (frames 67-74) in the 2 chamber view. The Nyquist limit was acceptable (range in this study between 61 and 71) as was the gain setting. The regurgitant jet was mosaic in color. The mitral jet was holosystolic, as confirmed on page 23 by spectral Doppler, and laterally directed to within 1½ cm of the posterior wall of the left atrium.

Dr. Kaul disagrees, claiming the observed jets are not holosystolic but even if the jets are considered holosystolic, the RJAs are overtraced and LAA undertraced.

> I disagree with Dr. Dahl's assessment that the study demonstrates moderate mitral regurgitation. In my opinion, as noted previously, a holosystolic jet is not seen consistently throughout the study. (See, for example, page 19, where the "jet" is only seen in a few of the systolic frames.) Moreover, even if you assume that the "jet" is holosystolic, the degree of putative regurgitation does not reach FDA positive levels.
>
> The technician measures the left atrial area (LAA) on page 18 of the study (15.55 cm^2). However, according to the EKG, the LAA was measured in mid-systole instead of end-systole when the LAA is at maximum. [Citation omitted]. Also, the technician undertraced the LAA, especially in the medial portion of the view. Thus, the LAA was underestimated for the purposes of this study.
>
> The technician measured RJA on pages 20 (2.23 cm^2), 21 (4.24 cm^2), and 22 (4.4 cm^2). The ratios amount to 14%, 27% and 28% respectively, assuming a denominator of 15.6. On each of these tracings, there is included in the putative regurgitant jet much laminar, low velocity flow as well as static blood. Additionally, on each one of the measurements, the putative jet is overtraced. With regard to page 20, the "jet" measured

> by the technician is not holosystolic, as seen on page 19, frames 199-205. The same is true of page 21 (page 19, frames 177-182) and page 22 (page 19, frames 156-165).

The Court finds that despite Dr. Kaul's spirited disagreement with his colleagues, Wyeth has failed to carry its burden of establishing that no medically reasonable opinion that Eske has MMR could be supported with reference to this echocardiogram.

Q. DONNA M. EVANS-BRIGGS

Evans-Briggs relies on a May 15, 2002 echocardiogram and a report by Dr. Richard Levinsky. Dr. Levinsky found that Evans-Briggs had MMR using CAS criteria -- RJA/LAA = 22.5%.

The May 15, 2002 echocardiogram was reviewed by three (3) experts: Dr. Marino, Dr. Ong and Dr. H. Cohen.

Dr. Marino found the "black and white gain [to be] somewhat high, making it difficult to accurately trace left atrium [area]." Dr. Ong also commented on the 2-D and color gain, but concluded that the echocardiogram could be adequately assessed.

Both Drs. Ong and Marino found no MMR. Dr. Ong reported

> [t]he actual[] amount of mitral regurgitation is minimal and is mostly due to mitral closure-related flow. The flow described on frames 1:46:46:00, 1:46:54:03, 1:47:12:27 and 1:50:19:18 is due to color artifact from moderately excessive color gain settings. It is discontinuous (not originating from the mitral valve) and does not have the typical turbulent, high-velocity flow associated with true mitral regurgitation.

Dr. Marino concurred: "[t]here is at most trivial mitral regurgitation seen on this echocardiogram, most likely due to the closing volume phenomenon. A flash of signal is seen below the mitral valve, but it only lasts one or two frames. The signals seen on this study are primarily laminar blue, low velocity flow."

Dr. H. Cohen disagreed, but as we have seen, he has virtually no data to support his conclusions. He merely states that at certain time markers there is evidence of MMR.

Dr. Marino demolishes Dr. H. Cohen's conclusion in his reply certification which the Court adopts as its findings.

> As I indicated in my original report, the black and white gain setting is set too high on this echocardiogram, making it impossible to reliably measure the LAA. Thus it is impossible to reliably calculate the RJA/LAA ratio. Therefore, it is not reasonable to assess the level of regurgitation based on this study. Nonetheless, even with the high gain setting, I can say that no true MR is present on this study. As I indicated in my original report, there is at most a bit of closing volume.
>
> Dr. Cohen refers to time markers 1:46:54:04; 1:47:13:09; and 1:50:40:02 as showing moderate mitral regurgitation. There are no measurements on the tape at these time markers. After multiple reviews of this entire section of the study, I see nothing that might constitute FDA Positive mitral regurgitation.
>
> In sum, due to the high 2-D gain setting, this is a technically inadequate study such that the reliable medical conclusions about the RJA/LAA ration [sic] cannot be drawn from it. Nevertheless, even with this technical limitation, no true mitral regurgitation is visualized on this study.

After careful review of this technically marginal echocardiogram, the Court concludes that Wyeth has satisfied its burden and established that no reasonable medical conclusion that Evans-Briggs has MMR could be based on this echocardiogram.

R. KAREN FARINELLA

Farinella relies on an echocardiogram report by Dr. Stanley S. Schrem. Dr. Schrem found Farinella had MMR using CAS criteria -- RJA/LAA = 25%.[13]

This echocardiogram was reviewed by three (3) experts: Dr. Kaul, Dr. Ong and Dr. Lassetter. All three (3) physicians found the echocardiogram was technically adequate, though it was suggested by Wyeth in cross-examination and by Dr. Kaul in his reply certification that the gains were high and the Nyquist was below 50 cm/sec for most of the echocardiogram and that most of the mitral loops were interrogated at a Nyquist below 50 cm/sec. Dr. Lassetter also provided information on the technical adequacy of Farinella's echocardiogram and his analysis of it. He reported that

> I have reviewed the echocardiogram performed on Karen Farinella on 12-31-02 and it is my opinion that this study demonstrated moderate mitral regurgitation according to methods of quantifying regurgitation and ranges for various levels of regurgitation as stated in the Singh article. The study is of diagnostic quality with the gain set at a height level but which still allows diagnostic interpretation. The Nyquist limit is 46 in one view but was 51 in the views in which I made my measurements, on pages 49 and 50, which is within recommended parameters as set by the ASE. The jet is a blue/yellow mosaic jet which occurs during systole.

Dr. Ong initially appeared to disagree with Dr. Lassetter's conclusion that Farinella's echocardiogram demonstrated MMR, but he supported Dr. Lassetter's conclusion in his testimony at the hearing.

> JUDGE WALSH: All right … we pass on to the next individual, Karen Farinella. When you have Ms. Farinella's report there, just let me know, Doctor.
> THE WITNESS: I have it.
>
> * * * *
>
> JUDGE WALSH: Was Ms. Farinella's echocardiogram conducted in a technically adequate manner so that reliable medical conclusions could be drawn from it?
> THE WITNESS: Yes.

[13] The echocardiogram report was dated but was cut off on the copy provided to the Court.

JUDGE WALSH: There's a mitral regurgitation claim here. Could you tell us whether you found moderate mitral regurgitation or not?
THE WITNESS: No, I didn't.
JUDGE WALSH: Why not?
THE WITNESS: The initial claim, I believe it's from the defense, said that the regurgitant jet area also encompassed part of the flow that was in the atrium as opposed to the ventricle. And that being so does not allow itself to be counted toward the mitral jet area. So it wasn't really regurgitant jet.
JUDGE WALSH: All right. And as a result, you didn't make any measurements?
THE WITNESS: That's correct.
JUDGE WALSH: Would a physician with your qualifications reasonably find that this individual had moderate mitral regurgitation?
THE WITNESS: It was impossible for me to perform a regurgitant jet area. There is mitral regurgitation, but I could not determine the severity of it. But there is definitely there.
JUDGE WALSH: My point is a simpler one. Could someone with your qualifications looking at this echocardiogram alone, could that person conclude reasonably that there was moderate mitral regurgitation by FDA criteria?
THE WITNESS: Yes.
JUDGE WALSH: A reasonable person could conclude?
THE WITNESS: I believe so.
JUDGE WALSH: All right. So be it. Explain why that is.
THE WITNESS: Well, visually I can see that there was a substantial amount of regurgitant jet area within the left atrium, even though the measurements I believe were incorrectly obtained. Visually I believe they exceeded the 20 percent limit.
JUDGE WALSH: Okay.
THE WITNESS: I was not able to perform that measurement.

> JUDGE WALSH: I'm a little puzzled why you said in answer to the question: Is it medically reasonable to diagnose this plaintiff with FDA positive mitral regurgitation in an apical view based on this echocardiogram using the standards set forth in the letter to you? And you answered no.
> THE WITNESS: I answered no because the methodology was incorrect. Maybe I had misread the implication of that letter. So I do not believe that they performed it to prove that it was greater than 20 percent.
> JUDGE WALSH: Okay.
> THE WITNESS: When I looked at it, without doing any measurements, it appeared to be greater than 20 percent.
> JUDGE WALSH: So, in other words, if they had done it correctly, it would have been greater than 20 percent?
> THE WITNESS: That's right.
> JUDGE WALSH: And our criticism is simply with the methodology that they used?
> THE WITNESS: That's correct.
> JUDGE WALSH: If they had done it correctly, they would have found more than 20 percent?
> THE WITNESS: I believe they would.

Dr. Kaul disagreed, particularly in his reply certification and in his testimony, that this was a technically adequate echocardiogram or that it demonstrated a true holosystolic jet. He noted:

> I disagree with Dr. Lassetter's conclusion that the echocardiogram demonstrates moderate mitral regurgitation. Additionally the study has certain technical limitations in many frames, where the Nyquist limit is set below 50cm per second. This causes blood that is not turbulent to appear as though it is, and further causes the putative regurgitant jet size to be exaggerated. This is compounded by the fact that the gain is set too high on this study. Therefore, the study becomes methodologically unsound, and the degree of regurgitation cannot be reliably interpreted.

Even with this low Nyquist limit, and the abnormally high gain settings (this demonstrated on page 27), one can see from the dynamic loops that the putative regurgitant jet is not holosystolic. For instance, on page 30, the phenomena characterized as a regurgitant jet by Dr. Lassetter is only seen in one frame. Otherwise, what is seen is monochromatic low velocity laminar flow. Additionally, the putative jet is overtraced. Indeed, the technician traced out into the left ventricle and encompassed proximal isovelocity surface area (PISA), which by definition is not mitral regurgitation. The effects of the very high gain settings are seen on frame 11 of page 30. Finally, the snapshot of the putative jet, which was measured by the technician, occurs in very early systole. Given the low Nyquist and high gain, it is difficult to tell whether or not the valve is even closed in this frame.

The fact that the putative jet is not holosystolic is also seen on page 31. Again, the Nyquist is too low (46), and the gain is high. The putative jet that was measured at frame 3 by the technician is not holosystolic; in the dynamic loop, it is gone in the next frame. The same is true of the putative jet measured at page 32.

Dr. Lassetter relies on certain measurements from pages 49 and 50 of the study. A frame-by-frame analysis shows that these "jets" only last a couple of frames and certainly do not last throughout most or all systole as required by Weyman. [Citation omitted]. The same is true of the other measurements taken by the technician at pages 52, 59 and 65.

Because the putative jet as seen in the study is not holosystolic, and due to the technical inadequacies of the study, it would thus be medically unreasonable to diagnose this patient with FDA positive mitral regurgitation.

The Court finds that generally Dr. Kaul defended his opinion during the cross-examination. On the one area of interest to the Court -- whether there was true proximal isovelocity surface area ("PISA"), which is an indicator of mitral regurgitation in the echocardiogram as claimed by Dr. Lassetter and on cross-examination of Dr. Kaul, or a gain artifact -- neither party adequately explored the issue.

On balance the Court believes Dr. Kaul is correct and Farinella does not have MMR. The echocardiogram is of poor quality and the jets are badly traced and they are clearly not holosystolic. However, the record was so badly developed by the parties on these issues that the Court cannot conclude that no reasonable medical opinion that Farinella has MMR could be supported by the echocardiogram.

S. CYNTHIA FEDORIK

Fedorik relies on a May 11, 2002 echocardiogram performed by Associates in Cardiology, Ltd. and a report by Dr. Neal Ruggie dated May 14, 2002. Dr. Ruggie found Fedorik had MMR and severe aortic regurgitation ("SAR") using CAS criteria -- RJA/LAA = 38%; JH/LVOT = 47%. The MMR claim was withdrawn, leaving the SAR claim.

The May 11, 2002 echocardiogram was reviewed by three (3) experts: Dr. Kaul, Dr. Ong and Dr. Lazar. Dr. Ong found that the echocardiogram was technically inadequate such that reliable medical conclusions regarding the presence or severity of valvular regurgitation could not be drawn from it. Dr. Kaul noted the gain but believed the echocardiogram could be interpreted, as did Dr. Lazar.

Both Drs. Ong and Kaul concluded that Fedorik could not be found to have even MAR based on this echocardiogram. Dr. Kaul put it this way: "[t]he aortic regurgitant jet height is overestimated by the sonographer, who measures distal to the site of the jet origin and includes laminar flow in the JH measurement. Only trace aortic regurgitation appears in the PLAX view." Moreover, in his testimony, Dr. Kaul observed that any aortic regurgitation was a transient phenomenon and quite small. He contradicted Dr. Lazar's measurements as well.[14]

---

[14] Dr. Kaul's testimony on this point is set out below.

> JUDGE WALSH: There are three single frames, Doctor, which I think reflect three of his measurements. He made five. He's withdrawn two of them.

Dr. Ong also made measurements which he claimed refuted the aortic regurgitation claim.

> JUDGE WALSH: Okay. There's no aortic regurgitation claim so we'll pass on to the next individual. Cynthia Fedorik.
>
> Was this echocardiogram conducted in a technically adequate manner such that reliable medical conclusions could be drawn from it?
>
> THE WITNESS: No. The color setting was set high creating a lot of artifact.
>
> JUDGE WALSH: A lot of color artifact?
>
> THE WITNESS: Yes.
>
> JUDGE WALSH: All right. Nevertheless, there's a mitral valve regurgitation claim made here. You apparently continued to review the --
>
> MR. WHITTENBURG: Objection. Your Honor, I think it's an aortic valve claim.

THE WITNESS: I'd like to see a loop also.
MR. WHEELER: We're going to look at two loops.
THE WITNESS: Yes.
JUDGE WALSH: Looks to me like you measured at these five matters and said the best he does is 5 percent.
THE WITNESS: I measured the ones he referenced earlier, but now it seems he's changed his reference.

* * * *

MR. WHEELER: First, let's look at that image, Doctor, and have you comment on it and then we'll look at a real-time loop. I'm sorry, TJ. I got you off your mark.
THE WITNESS: If you don't mind, I'd prefer seeing a real-time first. Is that possible?
MR. WHEELER: No, that's absolutely possible, and I apologize. Let's look at Loop 6068. We've marked that as Exhibit 4303 and it encompasses time markers 107:10:09 through 107:15:02.
THE WITNESS: That includes his frames.

* * * *

JUDGE WALSH: Not on Fedorik. What happened was --
MR.. WHEELER: It's the wrong valve, I believe, your Honor.
JUDGE WALSH: What?
MR. WHEELER: I believe Dr. Kaul is of the opinion that it's not an image of the aortic valve, but perhaps of the pulmonic valve.
THE WITNESS: Not perhaps. It is the pulmonic valve.
JUDGE WALSH: Well, Mr. Wheeler was trying to be a little nice.

After counsel saw it, I think he realized -- and I think Dr. Lazar was about to correct him, he withdrew the exhibit. So there's no continuous wave evidence at all in support. And that portion of his affidavit is stricken.

MR. WHEELER: It was.
JUDGE WALSH: There was a mitral valve claim and that's withdrawn?
MR. WHITTENBURG: Yes.
JUDGE WALSH: All right. Excuse me, Doctor. We tried to bring you up to date with the latest, but apparently after counsel looked at this, they're only pressing the aortic regurgitation claim. So let's move to that.

Was the parasternal long axis view available on this echocardiogram in connection with the claim of mild aortic regurgitation made by this claimant?
THE WITNESS: Yes.
JUDGE WALSH: And does the parasternal long axis view show a positive regurgitation, that is a 10 percent JH/LVOT?
THE WITNESS: No, again, because of the color flow settings. They tend to overestimate it and it did not.
JUDGE WALSH: Okay. And you indicate that it's not medically reasonable to diagnose this patient with FDA positive aortic regurgitation. Is that correct?
THE WITNESS: That's correct.
JUDGE WALSH: Can you tell us why not?
THE WITNESS: I performed the measurements in two separate locations using calipers and I did not finds [sic] that it exceeded the 10 percent. I measured it at 9 percent or less.
JUDGE WALSH: All right. Even with the artifact?
THE WITNESS: It was my best guess as to what was truly the aortic regurgitation.

* * * *

Q. Dr. Ong, if you could turn to the plaintiff by the name of Cynthia Fedorik.
A. Okay.
Q. Doctor, I believe you testified earlier that with respect to the aortic regurgitation, you were able to visualize an aortic jet in the PLAX view. Is that correct?
A. Yes.
Q. And I believe that in your echocardiogram review and assessment form, you did planimetry using calipers?

A. It wasn't planimetry. It was a straight measurement.
Q. And that was at location 1:00:54 and 1:058:35?
A. Yes.
Q. And when you got the JH/LVOT ratio, I believe you testified you came to a conclusion of [9] percent?
A. Yes.
Q. Doctor, are you familiar with a term "intervariability"?
A. Yes.
Q. Is it medically reasonable for a doctor with your qualifications to consider a measurement in that frame of 10 percent?
A. If you're asking -- if you're asking if another cardiologist did the same measurement?
Q. Correct.
A. Well, based on that, yes.
Q. And is it possible that that could be a regurgitant jet of 10 percent or greater in other locations on this echocardiogram?
A. No. Those frames that I took were what appeared to be the largest dimensions. So, I don't believe that other frames would enhance that number.

Dr. Lazar testified that Fedorik has MAR not the SAR originally claimed. He testified that three (3) measurements support that claim.

JUDGE WALSH: I think they put in some of this evidence. My records indicate that they put in on Fedorik 4010, 4011 and 4012. And that's it.
MR. RAMSAY: Right.
JUDGE WALSH: So, those are the ones he's relying on, and that's it.
MR. D'ANGELO: That's what I'm relying on.

* * * *

Q. Doctor, with regard to those three frames, and I'll be glad to show them to you, are you suggesting that, based on the color mapping, these frames demonstrate high velocity flow?
A. Yes.
Q. And they demonstrate turbulent flow?

A. High velocity generally goes along with turbulence. There are subtle differences, but generally yes.

* * * *

MR. RAMSAY: I'm bouncing around, Judge. I do want to put that in.

Q. Dr. Lazar, in your direct examination, you indicated to this court in response to questions asked that, in fact, aortic insufficiency was confirmed on continuous wave [D]oppler.

Do you recall that?

A. Yes.

Q. And, in fact, you cited a frame at 1:12:54:01 for the continuous wave [D]oppler as that which you reviewed and relied upon in confirming what you say is aortic insufficiency?

A. I don't believe that frame is correct.

Q. Why not?

A. Because it's a little -- because I would not rely upon this frame.

Q. Why not?

A. Because it is a short axis view with the cursor mostly over the aortic valve but close in proximity to the pulmonic valve.

Q. Yes, sir. Well, if that is the only continuous wave [D]oppler in this study --

JUDGE WALSH: He's not relying on it.

Q. Then you don't believe it's reliable now, notwithstanding your report?

A. Correct.

Q. All right. Can you show us on any loop or the tapes what you contend would be holodiastolic regurgitant flow?

A. Yes. I would have to examine this again, but I could.

* * * *

Q. Doctor, if you would look, and we have a loop, 6086, which is Exhibit 4303, and encompasses a period in which you were making measurements. It starts at 10:07 and continues, I think, for a couple of minutes.

Can you show this court what you contend to be regurgitant flow that lasts through most or all of diastole?

A. Can I see it? It's going to have to be frame by frame.
Q. I'll be glad to do that.

* * * *

JUDGE WALSH: We're on Fedorik. I think the doctor wanted to see the tape. I assume he saw the tape.

So, what points do you need to make, Mr. Ramsay, on that score?

Q. Doctor, I can play the tape, but do you contend that with any frequency, in looking at several cycles, you see what you consider to be aortic regurgitation that lasts through all of or most of diastole?
A. Yes.
Q. And how many times did you see that?
A. I stopped after two consecutive ones, from frame 1:07:11:17 to 1:07:11:22. That was the first.
Q. Is that the loop that I initially played? It was not in the loop that we had played for you.
A. No.
Q. Did you see it in that entire loop that consisted of --
A. Not in the loop that you chose.
Q. Yes, sir.
A. But in the -- in reviewing the tape in another loop and in another loop, 1:09:51.24 to 1:09:52:03. It was virtually all diastole.
Q. Simply for the purposes of our examination -- and I appreciate your response -- in loop 6086, which is D-4303, during that entire cycle, those several cycles, you did not see AR that lasted throughout -- or most of diastole?
A. That was the loop that you played?
Q. Yes.
A. No, I did not.

Dr. Kaul reviewed the media which Dr. Lazar relied on for his conclusions. This review demonstrates two things. First, the regurgitant jet is not holodiastolic. Second, the JH measured by Dr. Lazar is significantly overtraced.

JUDGE WALSH: Fedorik is 4303.
MR. WHEELER: For this particular loop your Honor the study itself is 4040 in its entirety.

THE WITNESS: This is very tiny aortic regurgitation. It doesn't last in most of diastole. If you can play it frame by frame, I can show the judge. This is systole your Honor. Keep going, keep going. Frame by frame. Okay that's diastole. Go back a couple of frames. One more. Yeah, go forward, forward, there's diastole, one, two, next, three, gone. Okay. Keep going. Systole, systole, one, two, two frames. Tiny little aortic regurgitation so at least here, I mean it's minuscule. Can you play it again. The color is in systole and then there's a little diastole and not every frame, every systole so it's like one cardiac cycle, not in the other and then in the third cardiac cycle a little bit.

Q. It's my understanding that Dr. Lazar also made reference yesterday in his testimony to images at earmark ear that we have captured and want you to comment on?

A. Okay.

Q. It's a time marker one:07:11:17 through 107:11:22 we've not marked it as an exhibit, I don't believe or have we?

THE WITNESS: This is a loop again.

MR. WHEELER: It's 61 hundred and we'll have an exhibit number for it in a minute your Honor. And we actually backed it up a little bit so the doctor can comment on it in real-time it's Exhibit 4543. I'm sorry, Judge.

A. This looks like the last one.

Q. This is inclusive of what Dr. Lazar testified about yesterday in open court, Doctor Kaul, can you comment on this?

A. Yes you can see this is the aortic route, if you go frame by frame I'll show you where the regurgitation is. One, two, keep going, okay systole, keep going, keep going, there. Go back a frame. It starts here, like here, there it is. Go back, go back. Yeah. This is the vena contracta, right this little neck here so if you make this measurement compared to the aortic root there is no way this is going to be more than 5 percent. I mean no matter what calipers you use and so --

MR. WHEELER: Is it holodiastolic.

> A. On the other hand, if you mix it here you'll get what he wants so -- I mean it's so important that you make a measurement at the vena contracta right where it's coming out because that's what we're interested in otherwise it sprays and you can get everything you want.
> Q. Is that regurgitant jet holodiastolic, doctor?
> A. No it's not.
> Q. Can you demonstrate that to the court?
> A. Okay, next, next, gone, next, this is all diastole now. It's gone. Next. Next. Next. Next. Next. Next, and then systole starts again.
> Q. Thanks, Doctor.
> A. So maybe two or three or four frames out of all that, and diastole is longer than systole.
> Q. Dr. Lazar in his certifying affidavit indicated that there was continuous wave support for his position at the time stamp 112:54:01?
> A. This was yesterday.
> Q. In his affidavit, I'm not sure if he testified about this or not. It's FC-1, TJ, and it's defense Exhibit 4297?
> JUDGE WALSH: That was with drawn [sic].
> MR. WHEELER: It was withdrawn.
> JUDGE WALSH: He said he wasn't relying on the continuous wave.
> MR. WHEELER: So we need not comment on that then, your Honor.

In sum, the Court finds that Wyeth has established that no reasonable medical opinion could be drawn from Fedorik's echocardiogram that she has at least MAR.

T. ROBERTA M. FEWS

Fews relies on a July 26, 2002 echocardiogram performed by Associates in Cardiology, Ltd. and a July 29, 2002 report by Dr. Roger A. Billhardt. Dr. Billhardt found that Fews had MMR using CAS criteria -- RJA/LAA = 21%.

The July 26, 2002 echocardiogram was reviewed by three (3) experts: Dr. Kaul, Dr. Ong and Dr. Billhardt. All three (3) physicians found the echocardiogram to be technically adequate though it was noted that the color gain

was high. Both Drs. Ong and Kaul concluded that the echocardiogram fails to document MMR. Dr. Ong observed that "[t]he MR is of brief duration, suggesting that it is due to closing of the valve. Measurements performed in frames 1:07:54 and 1:09:00 included color artifact that overestimated RJA. The actual 'regurgitation' is small." Dr. Kaul concurred.

Dr. Billhardt disagreed that only closing volume was shown. He noted that he does not routinely see closing volume in his practice. Acknowledging that the frames he traced occurred at the very beginning of systole, Dr. Billhardt claimed that mitral regurgitation need not be holosystolic and can occur anytime in the systolic cycle.

> Q. Now, your echocardiograms have also been reviewed by other physicians, and one of the criticisms that have been levied is that what has actually been planimetered was closing volume.
>
> Could you comment on that, please.
>
> A. Well, mitral regurgitation can occur at any time through the cardiac cycle end (sic) [and] systole, and the difficulty with the planimetry of each of these jets is that we have only a certain period of time that we can actually look at the information.
>
> And mitral regurgitation does not have to be holosystolic. It can occur early or in the mid portion of the -- of systole or it can occur late in systole. So a criticism that the regurgitation was occurring only early, I don't think, is one that can be made.
>
> Closing volume is not something that I routinely see in my practice. If there is no mitral regurgitation, we won't see any regurgitant jet, even though the mitral leaflets may slam shut with great force. If there is no regurgitation, there is no regurgitation.
>
> Q. And, in your opinion, with respect to the Fews echocardiograms, do you believe that to have been closing volume?
>
> A. I don't. I think that is true mitral regurgitation.

The Court rejects Dr. Billhardt's testimony as it relates to his claim that mitral regurgitation need not be holosystolic. As has been repeatedly observed, this is a *sine qua non* for an appropriate MMR diagnosis. Review of the

echocardiogram demonstrates that there is no holosystolic jet present and the measurements are done on non-holosystolic flashes. Accordingly, the Court finds that Wyeth has established that no reasonable medical opinion that Fews has MMR could be drawn from this echocardiogram.

U. MARJORIE E. FILVER

Filver relies on a June 25, 2002 echocardiogram performed by Associates in Cardiology, Ltd. and a June 26, 2002 report by Dr. Neal Ruggie. Dr. Ruggie found Filver had MAR using CAS criteria -- JH/LVOT = 19%.

The June 25, 2002 echocardiogram was reviewed by three (3) experts: Dr. Kaul, Dr. Ong and Dr. Lazar. All three (3) physicians found the echocardiogram to be technically adequate. Both Drs. Ong and Lazar found that Filver had MAR. Dr. Ong noted that there was evidence of aortic regurgitation in the PLAX view. Dr. Ong noted the presence of artifact, but nevertheless found MAR at frame 24:00:00 and measured it as 15%. Dr. Lazar also found MAR at two (2) locations in the PLAX view and measured both as 14%.

Dr. Kaul disagreed, finding only trace regurgitation and measuring it at 7%. He believed that Drs. Ong and Lazar improperly traced the observed jets.

The Court finds that Wyeth has failed to satisfy its burden to show that no reasonable medical opinion that Filver has MAR could be made based on this echocardiogram. The Court believes that, at the least, reasonable physicians could differ in their opinions on whether Filver has trace aortic regurgitation or MAR.

V. ZELLA FITLEBERG

Fitleberg relies on a December 12, 2002 echocardiogram report by Dr. Edward S. Katz. Dr. Katz found Fitleberg had MMR using CAS criteria -- RJA/LAA = 30%. Aortic regurgitation is listed as mild though no measurements were given. Ultimately, no aortic regurgitation claim was made. Dr. Katz found the study quality to be "fair."

The echocardiogram was reviewed by three (3) experts: Dr. Kaul, Dr. Ong and Dr. Lassetter. All three (3) physicians noted the high color gain on the study. Dr. Kaul found that the gain was so high that the echocardiogram could not be considered technically adequate. Dr. Lassetter also recognized that the gain was high.

> Q. With regard to the gain settings, did you look to see if they were appropriate for diagnostic purposes of reading and interpreting for moderate mitral regurgitation?
> A. I believe it to be adequate for diagnosis, but on the high end.

Both Drs. Ong and Lassetter believed that despite the technical limitations, the echocardiogram showed that Fitleberg has MMR. Dr. Ong noted that

> [a]lthough there were frames that appeared to have inappropriately high color-flow gain settings, as in 8, 9, and 18 where the color flow exceeded the boundaries of the heart, there was (sic) [were] also frames that depict[] mitral regurgitation with a reliable color-flow jet seen on multiple views as in frame 34. The RJA such as that measured on frame 29 appears to be an accurate representation.

Dr. Lassetter was more emphatic.

> It is my opinion that the echocardiogram demonstrated moderate mitral regurgitation according to methods of quantifying regurgitation and ranges for various levels of regurgitation as stated in the Singh article with a ratio of 30%. The mitral regurgitation on this echocardiogram was visualized in the apical views as required by the Settlement Agreement. It is seen in the apical 4 chamber views on pages 26, 32 and 34 in real time and on pages 27-30 and page 33 in still frames. The jet was blue/yellow mosaic in color. The jet color, location, and timing of this jet is consistent with the criteria for aortic regurgitation as stated in the Singh article. Using my own measurements, an RJA of 6.23 and an LAA of 21.6, the Singh ratio of Ms. Fitleberg's MR was 30%, which falls into the moderate mitral regurgitation range according to Singh criteria.

Dr. Kaul emphatically disagreed.

I disagree with Dr. Lassetter's assessment that Ms. Fitleberg's echocardiogram reflects moderate mitral regurgitation. In my opinion, the study shows only some closing volume and perhaps some early systolic event associated with the patients severe mitral annular calcification.

The calcification on Ms. Fitleberg's mitral annulus is readily seen on the study. Despite this, and despite the fact that the gain is very high on this study, the apical four chamber views consistently show that the putative jet described by Dr. Lassetter is not holosystolic. For instance, see frames 21-23 on page 26; 21-29, 41-45, and 85-95 on pages 31; 22-30 on page 32; 1-9 and 22-30 on page 34. In each of these clips, the closing volume or backflow is seen for only one or two frames and then disappears. This certainly does not continue "throughout most or all of systole," as described in the Weyman text. [Citation omitted]. Additionally, the continuous wave Doppler on page 25 clearly demonstrates that these events are not holosystolic.

There are 5 different measurements of the RJA made by the technician (pages 27, 28, 29. 30, and 33). None of these frames are seen dynamically, so it would be impossible to state that the putative jets are holosystolic. The images are captured in the very beginning of the systolic phase, which is inconsistent with Weyman. [Citation omitted].

Specifically with respect to page 27, which is the measurement Dr. Lassetter relied upon, the EKG indicates that the frame was taken from a very early portion of mechanical systole. The elevated gain settings, together with the severe mitral annulus calcification, creates the impression that the valve may not be closed. If so, then it follows that what is traced is not mitral regurgitation, as this is by definition a systolic occurrence.

> Each one of the five tracings of the putative regurgitant jet is overtraced by a large margin. The tracing include low velocity and laminar flow as well as static blood.
>
> The technician measured the left atrial area on page 36 at 21.61. The measurement was taken at mid-systole rather than late-systole, as directed by Weyman. [Citation omitted]. This would tend to minimize the LAA. Further, it appears that the technician failed to include in the measurement a portion of the left atrium proximal to the mitral calcification.

Dr. Kaul successfully defended these points during the hearing.

The Court agrees with Dr. Kaul that the echocardiogram is technically flawed; the measurements were significantly overtraced; and Fitleberg's valve pathology largely accounts for any truly observable phenomenon on this echocardiogram. Despite this, the Court concludes that Wyeth has failed to carry its burden to establish that no reasonable medical opinion that Fitleberg has MMR could be drawn from this echocardiogram.

W. BERNICE FOLSOM

Folsom relies on a December 7, 2002 echocardiogram report by Dr. Charles F. Dahl. Dr. Dahl found Folsom had MMR and MMAR using CAS criteria -- RJA/LAA = 38%; JH/LVOT = 30%.

The echocardiogram was reviewed by three (3) experts: Dr. Kaul, Dr. Ong and Dr. Dahl. All three (3) physicians concluded that the echocardiogram was technically adequate though Dr. Kaul noted the high gain settings.

Both Drs. Ong and Dahl concluded that Folsom had MMR and MAR. Dr. Ong supported the MMR claim and observed "[t]here were adequate frames of sufficient quality to support this conclusion, such as frame 39 and 56." As to the MAR claim, Dr. Ong found that "[w]hile some measurements did not adhere to accepted methodology by measuring the JH away from the aortic valve (frames 12-16), others demonstrate good technique (frames 17, 19, 20) that allowed a

reasonable conclusion of FDA positive aortic regurgitation." Dr. Dahl, too, found MMR and MAR and made these observations.

> It is my opinion that the echocardiogram performed on Ms. Folsom on 12-7-02 was of diagnostic quality and demonstrated moderate mitral regurgitation with a Singh ratio of 46% and moderate aortic regurgitation with a Singh ratio of 34% according to methods of quantifying regurgitation and ranges for various levels of regurgitation as stated in the Singh article.
>
> * * * *
>
> It is my opinion that the echocardiogram [] demonstrated moderate mitral regurgitation[15] with a Singh ratio of 46% according to methods of quantifying regurgitation and ranges for various levels of regurgitation as stated in the Singh article. Further, it is my opinion that the diagnosis is medically reasonable utilizing the protocols and criteria required in this litigation.
>
> The mitral regurgitation on this echocardiogram was visualized in the apical four chamber view as required by the Settlement Agreement, but demonstrated also in multiple other views, including the parasternal and 2 chamber views. MR is seen in real time on page 41 (frames 1-3), in the 2 chamber view (page 44, frames 1-2), and in the parasternal view on page 8 (frames 1-3). The Nyquist limit was acceptable per ASE recommendations at 51, as was the gain setting. The regurgitant jet was demonstrated in systole and confirmed by spectral Doppler. Utilizing the Singh formula of RJA/LAA, in this case 7.11/15.5 cm^2 (page 36) the mitral regurgitant ratio is (sic) [of] 46% is slightly greater than moderate mitral regurgitation according to Singh. The jet reaches to within one cm of the posterior wall of the left atrium.
>
> * * * *
>
> The aortic regurgitation on Ms. Folsom's December 7, 2002 echocardiogram was visualized in the parasternal

[15] He should have characterized it as SMR based on the Singh criteria.

> view as required by the Settlement Agreement, but demonstrated also in multiple other views, including the 4 chamber and 2 chamber views. AR is seen in real time on page 8 (frames 29-34) in the parasternal view, on page 10 (frames 14-20) in the parasternal view, page 39 (frames 12-17) in the 4 chamber view, and on page 56 (frames 12-18) in the 2 chamber view. The Nyquist limit was acceptable according to ASE recommendations at 51, as was the gain setting. The regurgitant jet was mosaic in color and holodiastolic, as confirmed on page 17 in the parasternal view. Utilizing the Singh formula of JH/LVOT, in this case, .75/2.2 cm^2 (page 12), the aortic regurgitant ratio is 34% which falls into the range of moderate aortic regurgitation according to Singh. The jet fills more than 25% of the LVOT in the parasternal, 2 and 4 chamber views. The color, location, and timing of this jet is consistent with the criteria for aortic regurgitation as stated in the Singh article.

Dr. Kaul disagreed, claiming that Folsom had no more than mild mitral regurgitation and trace aortic regurgitation.

> In my opinion, the echo demonstrates only trace aortic insufficiency. Additionally, the mitral regurgitant "jet" seen on this echocardiogram only lasts for less than half of the systolic cycle and is therefore not holosystolic. Finally, the gain settings on this study are very high. This artificially high setting creates a great deal of color "noise," which introduces "substantial error" into the study. [Citation omitted].
>
> For his assessment of aortic insufficiency, Dr. Dahl relies on pages 8 and 10 in the parasternal long axis view, as well as pages 39 in the apical four chamber view and page 56 of the apical two chamber view. Since the PLAX view is available, Ms. Folsom's aortic regurgitation must be measured in the PLAX and the other views are to be disregarded.

Dr. Dahl relies on the measurement on page 12 for his opinion that the plaintiff has moderate aortic regurgitation: "utilizing the Singh formula of JH/LVOT, in this case .75/2.20 cm² (page 12), the aortic regurgitant ratio is 34%…." Actually, the measurements on page 12 are JH = .75, LVOT = 2.70 cm². This ratio is 28% rather than 34%, even if you assume that the measurements were correct.

* * * *

Focusing on the measurement of the jet height on page 12, is apparent that the measurement is in error. The calipers are placed at a point distal to the regurgitant orifice, which is contrary to the protocols of both Weyman and Feigenbaum. [Citation omitted]. The "nozzle" effect would cause the regurgitant jet to plume, so that any downstream measurement as in this case would be inappropriately high. Moreover, it is plain from the image on page 12 that the calipers are placed outside the margins of the putative jet. Finally, what is measured by the calipers on page 12 is monochromatic, not high velocity, turbulent flow. It is therefore not representative of Ms. Folsom's true level of aortic regurgitation, which I calculated with calipers to be seven per cent [sic] (7%). this is well less than the minimum required to be FDA positive under the settlement agreement. The same is true of the other pages where the JH is measured, pages 13-20. All are measured substantially downstream from the orifice.

Dr. Dahl opines that the plaintiff has FDA positive mitral regurgitation. In his certification, he references page 36 of the study which he reflects a RJA measurement of 7.11 cm². This reference is in error. The actual measurement appears on page 46. The only page of the study where the technician interrogated the mitral valve with color Doppler in the apical four chamber view is on page 41, and there are no measurements of any putative jet in this portion of the study. What is seen in the apical four chamber view is a brief phenomena which lasts less than half of the systolic cycle and is therefore not

> representative of true mitral regurgitation. (See page 41, frames 1-8.)
>
> The technician traced several "jets" on pages 45-48. Each of these frames are significantly overtraced, and include low velocity, laminar flow.
>
> The technician measured the left atrial area (LAA) on pages 33 and 34. The LAA was undertraced in both images.
>
> Based on my review of Ms. Folsom's study, it is my opinion that Ms. Folsom has only trace aortic regurgitation, and some images suggestive of closing volume or backflow from her mitral valve. It would [be] medically unreasonable to assess Ms. Folsom with FDA positive levels of either aortic or mitral regurgitation.

The Court is left in a difficult position here because the three (3) physicians come to wildly different conclusions. Yet the parties agreed that this matter would be heard on the papers. The Court reviewed the echocardiogram and agrees that the purported mitral regurgitation was overtraced. Still, Dr. Dahl, with some support from Dr. Ong, contends that Folsom has serious valve pathology. Accordingly, the Court concludes that Wyeth has failed to establish that no reasonable medical opinion that Folsom has MMR and MAR could be drawn from a review of this echocardiogram.

X. DIANE FOSNOW

Fosnow relies on a June 27, 2002 echocardiogram performed by The Woman's Cardiovascular Center and a report by Dr. Linda Crouse. Dr. Crouse found Fosnow had MMR and MMAR using CAS criteria -- RJA/LAA = 21%; JH/LVOT = 31%.

The June 27, 2002 echocardiogram was reviewed by three (3) experts: Dr. Kaul, Dr. Ong and Dr. Charash. Dr. Ong found that the echocardiogram was conducted in a technically inadequate manner such that reliable medical conclusions regarding the presence and severity of valvular regurgitation could not be drawn from it. Specifically, Dr. Ong found "[t]he color-flow gain setting was

inappropriately high throughout the study, causing the appearance of color artifact."

Dr. Charash, too, believed that this echocardiogram was marginal. His explanation follows:

> Q. Doctor, the court's independent expert said that this echocardiogram was not technically adequate because there was high gain.
>
> Do you believe that there was a high gain setting on this echocardiogram?
>
> A. Yes.
>
> Q. However, you found that this echocardiogram was technically adequate in order for you to come to a conclusion based upon a reasonable degree of medical certainty?
>
> A. It's not one I can answer as a simple yes or no. I believe that the study required a high gain to penetrate and to see the structures.
>
> Again, sometimes you're between a rock and a hard place. Under the acceptable -- under the normal, typical gain settings, sometimes you won't be able to visualize the heart's internal structures adequately. And the only way you can visualize it is to turn up the gain.
>
> Sometimes you can't have both. You can't have the perfect settings and then be able to visualize jets and internal cardiac structures. So, yes, there is a chance that when you turn up the gain you will enhance the jet. And you do run some risk of having an enhancement.
>
> But on the other hand, the likelihood that it would be meaningful enhancement is very low. And if you look at the jet, it looks like a reasonable continuous structure.
>
> But in this case I believe it was a technique [sic] necessity to have any image whatsoever. We're not dealing with perfect studies. We're dealing with the way the real world works and the best you can do under the circumstances.
>
> It is my opinion that it was the only way to visualize this heart. And as a result, you do run the risk

of slight enhancement. But I don't think it was going to be meaningful.

* * * *

JUDGE WALSH: Well, I think what we need here, Doctor, and forgive me for interrupting, has less to do with the legal standard of proof in a negligence or product liability case -- which I know you discussed the last time you were here -- but more with the fact that there comes a point when the technique is so flawed that you can't meaningfully develop information. That's the question that I'm asking.

THE WITNESS: But on that continuum, sir -- and, again, this is where I'm just -- I'm ignorant on what the court is looking for.

There is a specter between a technique being so terrible there is no meaningful information and you're just snowing in Buffalo. There's the level of absolute clarity where you have near clinical certainty, as much as you could have with the best technique.

And then you can have in-between an image that would not reach the level of clinical certainty that you'd operate on that based on it, but from the point of view of whether or not there's probably this abnormality, you can say yes.

It's not useless, it's not perfect, but you can say to a reasonable degree of medical certainty, more likely than not, there is mild aortic regurgitation.

Now, if that statement has any meaning, does that have any room -- I mean, that's what I'm, as an expert, saying.

Some of these studies I would not make clinical decisions on, as I said in the summer, because I want clinical certainty and I can get clinical certainty.

JUDGE WALSH: Would you make a decision on this echocardiogram based on the quality?

THE WITNESS: Well, yes and no. In that, because I'm not saying it's surgical, I would treat a person with antibiotics based on this echo.

Both Drs. Ong and Kaul concluded that Fosnow had neither MMR nor MAR. As to the MMR claim, Dr. Ong found that "[t]he color-flow gain setting was high, causing the appearance of color artifact. Multiple measurements of RJA (as in frames 5:02:12, 5:02:34, 5:04:47) encompassed these artifacts, increasing the resultant area dimension. More accurate frames that showed minimal mitral regurgitation (as in 5:02:40 through 5:02:49) [which] did not get measured." As to the MAR claim, Dr. Ong rejected it, finding "[t]he measurement of the JH as demonstrated in frame 4:55:07 was performed along the length of the AR jet and not the width. The actual width is too narrow to measure accurately and would not exceed a JH/LVOT >10%." Dr. Kaul concurred, finding neither MMR nor MAR.

Dr. Charash disagreed and concluded Fosnow had MMR equal to 20% and MAR equal to 14%. But he acknowledged that even small changes in the RJA he adopted would destroy the MMR diagnosis. As to the MAR claim, Dr. Charash also conceded that if the purpose of the echocardiogram was to make a medically reasonable quantitative diagnosis of the degree of valvular heart disease he would repeat this study.

> Q. If the purpose was to make a medically-reasonable quantitative diagnosis of the degree of valvular heart disease, you would repeat this study; would you not?
> A. With a different technique.

The Court concludes that this echocardiogram was not conducted in a technically adequate manner such that reliable medical conclusions regarding the presence and severity of valvular regurgitation could be drawn from it. Moreover, the Court is satisfied that if the echocardiogram was used at all, no reasonable medical conclusion could be drawn from it that Fosnow has either MMR or MAR.

Y. KATHERINE GRAYSON

Grayson relies on a June 13, 2002 echocardiogram performed by The Women's Cardiovascular Center and a report by Dr. Linda Crouse. Dr. Crouse found Grayson had SAR using CAS criteria -- JH/LVOT = 61%.

The June 13, 2002 echocardiogram was reviewed by three (3) experts: Dr. Homma, Dr. Ong and Dr. Charash. Dr. Ong found the echocardiogram was conducted in a technically inadequate manner such that reliable medical conclusions regarding the presence and severity of valvular regurgitation could not be drawn from it. Dr. Ong found the image quality was poor and the color gain

was set far too high. Dr. Homma found the echocardiogram to be "marginally" adequate due to poor image quality. Dr. Charash in essence agreed. In response to one question, Dr. Charash volunteered the following: "But look at the image here. Look how terrible it is."

The Court concludes that given the limitation of this echocardiogram no reasonable medical conclusions can be drawn as to the presence or severity of any aortic regurgitation. This is apparent from the evidence. Dr. Crouse found a JH/LVOT ratio of 61%. Dr. Charash, who candidly commented on the poor technical quality, found 27%. Such variations are not reasonable in clinical practice and result from the poor quality of the image.

Both Drs. Ong and Homma found trace or less aortic regurgitation. Dr. Ong's comments in this regard are instructive.

> The poor acoustic quality of the study in addition to the high color gain setting renders the measurement unreliable. There was a[n] excessive amount of non-regurgitant color artifact that leads to overestimation of the severity of aortic regurgitation. A very small amount of aortic regurgitation is seen (time-frame 5:50:00 and 5:51:00), but was brief in duration, which suggests a low degree of severity.

Dr. Homma was more emphatic:

> There is no true aortic regurgitant jet seen on this study. Weyman provides that
>
> > [a]ortic regurgitation is detected by Doppler as a high velocity, turbulent, diastolic flow originating just below the aortic valve … immediately after valve closure and generally continuing throughout diastole.
>
> Weyman at 529. There is a brief flash of turbulent flow lasting only a few frames that is restricted to early diastole. There is no consistent regurgitant flow seen throughout diastole.

> Dr. Charash purportedly measures an aortic jet at 5:48:48, but this measurement was taken immediately following a premature ventricular contraction not representative of a normal cardiac cycle. Moreover, the pulse wave and continuous wave signals do not demonstrate the presence of true aortic regurgitation.[16]

The Court accepts Dr. Homma's findings in this regard as its own.

The Court finds that Wyeth has established that the echocardiogram was conducted in a technically inadequate manner such that reliable medical conclusions regarding the presence and severity of valvular regurgitation could not be drawn from it. Moreover, Wyeth has established that the claimed regurgitation is: artifact; the result of premature ventricular contraction; and, in any event, not holodiastolic.

Z. LEONILDA I. HARRIOTT

Harriott relies on an October 24, 2002 echocardiogram report by Dr. James Colasacco. Dr. Colasacco found Harriott had MMR using CAS criteria -- RJA/LAA = 35%.

The October 24, 2002 echocardiogram was reviewed by three (3) experts: Dr. Kaul, Dr. Ong and Dr. Colasacco. Both Drs. Ong and Kaul concluded that the echocardiogram was conducted in a technically inadequate manner such that reliable medical conclusions regarding the presence and severity of valvular regurgitation could not be drawn from it. Dr. Ong reported that "[t]he Nyquist limit is set too low (46 cm/sec) as evidenced by the presence of mosaic artifact…. Because of the low Nyquist limit setting, the still image used to measure mitral regurgitant area includes mosaic artifact, which will artificially increase RJA."

Dr. Kaul concurred, finding "[t]he Nyquist limit is 46 cm/second on this echocardiogram, which is unreasonably low. The color gain is set much too high on this echocardiogram. The combination of a low Nyquist and a high gain setting makes this echocardiogram technically inadequate because low velocity flow appears turbulent and jet size is overestimated." Moreover, according to Dr. Kaul, "[o]nly a trace amount of mitral regurgitation is seen, with a 'jet' that lasts only

[16] Premature ventricular contrast is a result of anomalous electrical activity which results in a larger volume of blood placing unusual stress on the aortic valve which may result in some leakage. It is not proper to measure aortic regurgitation in the cycle following this event.

[one] to [two] frames of the systolic cycle. Thus, it would not be medically reasonable to diagnose Ms. Harriott with FDA positive mitral regurgitation."

While Dr. Colasacco contends that this echocardiogram is of diagnostic quality, the Court disagrees. Wyeth easily has satisfied the Court that this echocardiogram is so technically deficient no meaningful information regarding valvular regurgitation can be gained from it.

AA. MARYLOU HATLEY

Hatley relies on an April 20, 2002 echocardiogram performed by Cardiac Consultants of Chicago, Ltd. and a report by Dr. Howard Cohen. Dr. H. Cohen found Hatley had MMR using CAS criteria -- RJA/LAA = 22%.

The April 20, 2002 echocardiogram was reviewed by three (3) experts: Dr. Kaul, Dr. Saric and Dr. H. Cohen. Dr. Saric found that the study was "suboptimal but readable" because of high color gain settings. Dr. Kaul agreed with Dr. Saric's conclusion, but found the echocardiogram reviewable, at least to exclude MMR.

Both Drs. Saric and Kaul concluded that there was no MMR here. According to Dr. Saric, "there is barely any mitral regurgitant jet[s] seen in either apical or parasternal views." Dr. Kaul reported that "only closing volume and not mitral regurgitation is seen on this echocardiogram." Dr. H. Cohen disagreed and claimed that Hatley had MMR, as he originally found.

The Court has reviewed this echocardiogram, as well as the other evidence, and has adopted Dr. Kaul's findings as its own.

> Dr. Cohen's Review and Assessment Form cites time markers 27:06:21, 26:39:12, 24:24:11 and 24:09:11 as showing mitral regurgitation yielding an RJA/LAA ratio of greater than 20%. He does not provide any specific RJA or LAA measurements. I have reviewed all of the apical views, and have looked particularly at those time markers. None of the frames cited by Dr. Cohen are of mitral regurgitation; rather, they show at most closing volume occurring early in systole.

The Court finds that Wyeth has sustained its burden to show that no reasonable medical opinion that Hatley has MMR could be drawn from this echocardiogram.

BB. LORETTA J. HAYES

Hayes relies on a June 12, 2002 echocardiogram performed by Associates in Cardiology, Ltd. and a June 13, 2002 report by Dr. Roger A. Billhardt. Dr. Billhardt found Hayes had MMR and MAR using CAS criteria -- RJA/LAA = 34%; JH/LVOT = 16%. The claim was withdrawn before the hearing.

The June 12, 2002 echocardiogram was reviewed by three (3) experts: Dr. Kaul, Dr. Saric and Dr. Billhardt. All three (3) physicians found the echocardiogram to be technically adequate.

Both Drs. Saric and Kaul found no true mitral regurgitation. Dr. Saric said "there is no true jet of [mitral regurgitation]." Dr. Kaul thought that only "closing volume" was seen on the echocardiogram. As to the aortic regurgitation claim, Dr. Kaul finds that no more than trace regurgitation is seen in the PLAX view. Dr. Saric goes further and states that "no true jet of [aortic regurgitation is seen] in any view."

While Dr. Billhardt argues that no aortic regurgitation is seen in the PLAX view, he believes that MMR is present here, reiterating his original findings.

The Court has reviewed this echocardiogram and finds no evidence of MMR. Dr. Kaul's critique of Dr. Billhardt's mitral valve findings square with the Court's findings.

> Dr. Billhardt states that Ms. Hayes has a wall jet of mitral regurgitation along the anterior left atrial wall. I see no such jet. In reality, only closing volume is seen on this echocardiogram. While it is improper to planimeter in the first place because only early systolic closing volume is seen, I would also note that the RJA measurements on this echocardiogram improperly include low velocity, laminar blue flow and black no-flow areas.

For these reasons then, the Court finds that no reasonable medical opinion that Hayes has either MMR or MAR is supported by this echocardiogram. Accordingly, Wyeth has carried its burden of proof in this case.

CC. SHIRLEY A. HESS

Hess relies on an August 29, 2002 echocardiogram performed by Inland Cardiology Associates, P.S. and a report by Dr. Susan J. Alexander. Dr. Alexander found that Hess had MMR using CAS criteria -- RJA/LAA = 21%.

The August 29, 2002 echocardiogram was reviewed by four (4) experts: Dr. Kaul, Dr. Saric, Dr. Charash and Dr. Lazar. Both Drs. Saric and Kaul find that the echocardiogram was conducted in a technically inadequate manner such that reliable medical conclusions regarding the presence and severity of valvular regurgitation could not be drawn from it. Both experts find the Nyquist limit of 46 cm/sec technically deficient. Certainly, in the apical view one would expect this setting to exaggerate any amount of color seen in the echocardiogram.

Dr. Charash does not even refer to the Nyquist limit but simply observes that "the echocardiogram settings were appropriate and the study was of diagnostic quality." Dr. Charash concluded that Hess had MMR based on measurements of 20% and 27%.

Dr. Lazar also fails to discuss the Nyquist settings here. He concludes that "the echocardiogram settings were adequate." Dr. Lazar found MMR based on measurements of 20% and 21%.

The Court finds that Wyeth has established that the echocardiogram upon which all the experts' opinions were based was conducted in a technically inadequate manner such that reliable medical conclusions regarding the presence and severity of valvular regurgitation could not be drawn. In light of the technical inadequacies here, the Court finds that Dr. Charash's and Dr. Lazar's conclusions may not be reasonably drawn and rejects them.

DD. ROSIE HICKS

Hicks relies on a December 19, 2002 echocardiogram report by Dr. Thomas I. Knox. Dr. Knox found Hicks had MMR using CAS criteria -- RJA/LAA = 20-30%.

The echocardiogram was reviewed by three (3) experts: Dr. Crawford, Dr. Saric and Dr. Charash. Both Drs. Saric and Crawford concluded that the echocardiogram was not conducted in a technically adequate manner such that reliable medical conclusions regarding the presence and severity of valvular regurgitation could be drawn from it. Dr. Saric noted:

> The study methodology does not conform to the recommendation of the American Society of Echocardiography regarding both the Nyquist limit. ("Standand [sic] technique is to use a Nyquist limit of 50-60 cm/sec, and color gain that just eliminates random color speckle from non-moving regions. p. 778, J Am Soc Echocardiog 2003:16:777-802). Nyquist limit on this study was set at 46 cm/sec.

Dr. Crawford was of the same view.

> [T]he Nyquist limit on this echocardiogram was set too low at 46 cm/sec, making it impossible to reliably assess the degree, if any, of mitral regurgitation. The low Nyquist setting will result in the exaggeration of any regurgitation that may be present.
>
> The *Weyman* text provides that an appropriate Nyquist limit is between 60-90 cm/sec. [Citation omitted]. In addition, the American Society of Echocardiography has established guidelines regarding adequate Nyquist settings. They state:
>
>> The size of the regurgitant jet by color Doppler and its temporal resolution however, are significantly affected by transducer frequency and instrument settings such as gain, output power, Nyquist limit, size and depth of the image section…. Standard technique is to use a Nyquist limit (aliasing velocity) of 50-60 cm/sec…. Jet area is inversely proportional to PRF, and substantial error can be introduced with use of higher or lower settings than the nominal settings to which echocardiographers have become accustomed. [Citation omitted].
>
> Because the Nyquist limit was inappropriately low in this echocardiogram, it is technically inadequate to assess the degree and presence of mitral regurgitation. Any

> measurements taken from the echocardiogram would not accurately reflect the true amount of regurgitation.

While Dr. Charash claims that the echocardiogram settings were appropriate and the study was of diagnostic quality, the Court does not agree. Instead, it finds that Wyeth has satisfied the Court that this is a technically infirm echocardiogram from which no reliable medical opinion on the subject of regurgitation can be made. In any case, the Court also agrees that to the extent the echocardiogram can be used to exclude MMR both Drs. Saric and Crawford find no evidence of mitral regurgitation. After review of the echocardiogram, the Court concurs with these experts.

EE. BARBARA HINES

Hines relies on a December 16, 2002 echocardiogram report by Dr. Jason Lazar. Dr. Lazar found Hines had MAR using CAS criteria -- JH/LVOT = 12%. This finding was apparently based on two (2) measurements -- one showing JH/LVOT = 10%; the other JH/LVOT = 14%.

The echocardiogram was reviewed by three (3) experts: Dr. Kaul, Dr. Saric and Dr. Lazar. Dr. Saric found that the echocardiogram was conducted in a technically inadequate manner such that reasonable medical conclusions concerning the presence and severity of valvular regurgitation could not be drawn from it. The gain settings "were very high."

Both Drs. Saric and Kaul concluded, in any case, that there was no aortic regurgitation. Dr. Saric found that "[n]o [aortic regurgitation] jet is seen in any view even with the color gains set very high." Dr. Kaul dismissed the MAR claim, noting "[n]o aortic regurgitation is seen in the PLAX view. Spurious measurements are made of signals that are not regurgitation."

Dr. Lazar initially found that "[t]he echocardiogram settings were adequate." But, on cross-examination, he conceded that the gain was high.

> MR. RAMSAY: If we can quickly go to Barbara Hines.
> A. Yes.
> Q. Doctor, on this particular claim it is your claim that Ms. Hines has or demonstrates mild AI?
> A. Yes.

> Q. Can we agree that in this particular echocardiogram that you reviewed we have very high gain?
> A. The gain is high.
> Q. And we've already established that gain can either obscure and create an appearance of regurgitation, and in the event there is regurgitation, it can certainly cause gross exaggeration of the degree of regurgitation?
> A. In certain instances it could cause gross, and in some instances it could cause mild overestimation. It depends on how high the gain is.

Dr. Lazar provided one view with his certification that indicates a JH of .32 cm and a LVOT of 2.36 cm. This yields 13.6%. But a view of the purported jet shows that it has a shape uncharacteristic of an aortic jet. In his testimony at the hearing, Dr. Kaul referred to this phenomenon as "the thing."[17]

---

[17] Dr. Kaul testified on this point as follows:

> Q. Dr. Kaul, it is contended that Ms. Hines has FDA-positive regurgitation. Would that be a medically reasonable diagnosis in your opinion?
> A. No. There is no aortic regurgitation.
>
> * * * *
>
> Q. Dr. Kaul, again we're looking at Page 40 as referenced by Dr. Lazar. Can you comment about his planimetry or perhaps his comment upon the technician's tracing?
> A. Yes, your Honor, this is the aortic … the aorta. These are the leaflets right here and the aortic regurgitation if any should start here at the leaflet. I don't see any regurgitation. I don't see any jet. I see some color in the middle of the left ventricle here going down and a measurement made of it. I called it the thing in my report because I don't know what it is.
>
> * * * *
>
> JUDGE WALSH: I guess on the JH we have Dr. Lazar's measurements which are more conservative, whether he measured it correctly or whether he should have measured it at all is obviously something you can comment on.
> THE WITNESS: Yes.
> JUDGE WALSH: What is your point here? Is it that this thing --
> THE WITNESS: This is not a regurgitant jet.
> JUDGE WALSH: And it is not a regurgitant jet why? Because it doesn't behave like a regurgitant jet should dynamically?
> THE WITNESS: It doesn't look, taste, smell. You know what I mean?
> JUDGE WALSH: It doesn't look like a duck or walk like a duck.
> A. Yes. And it's not being measured where it should come out from.
> JUDGE WALSH: Is that because it's like a snub nose?
> THE WITNESS: Yes exactly, and snub happening where it shouldn't be happening. If there has to be a snub it should be at the valve.
> JUDGE WALSH: In other words, it has to be proximate to the valve?
> THE WITNESS: Yeah, at least a centimeter.
> JUDGE WALSH: You say it's at least a centimeter removed?
> THE WITNESS: Yes.
> JUDGE WALSH: All right.

The Court finds that Wyeth has satisfied it that no reliable conclusions can be drawn from this technically marginal echocardiogram. The high gain is known to create artifact. The measurements of the so-called aortic "jets" by Dr. Lazar are not medically reliable because of the potential for artifact; the fact that the "thing" which is measured is fleeting in real time; and because the purported jet was not measured within one (1) centimeter of the correct LVOT location, as is required in the *ASE Standards*.

FF. RITA HOFEDITZ

Hofeditz relies on a May 2, 2002 echocardiogram and report by Dr. Curtis S. Burnett. Dr. Burnett found Hofeditz had mild mitral regurgitation and MAR to MMAR using CAS criteria -- JH/LVOT. No specified ratio was given for the MAR or MMAR. Only the aortic regurgitation claim is pursued here.

The May 2, 2002 echocardiogram was reviewed by three (3) experts: Dr. Kaul, Dr. Saric and Dr. Burnett. All three (3) physicians found the echocardiogram to be technically adequate, though Dr. Burnett stated that the PLAX view was suboptimal.

Both Drs. Saric and Kaul concluded that no MAR was observable in the PLAX view. Dr. Saric traced the jet at 7% and Dr. Kaul traced it at 4%. During the hearing, Dr. Saric amplified his findings.

> JUDGE WALSH: All right then. Let's pass on to Rita Hofeditz.
>
> * * * *
>
> JUDGE WALSH: All right. Ultimately, you came to the conclusion that there was a JH/LVOT ratio of what, Doctor?
> THE WITNESS: Of -- exact ratio was 7 percent, your Honor.
> JUDGE WALSH: All right. With a JH of .14 centimeters and a[] LVOT of 1.86 centimeters.
> THE WITNESS: That -- yes, that's correct, your Honor.

Q. Your Honor, if we might we'll look at one dynamic loop on this study, page 33 of the DICOM?
THE WITNESS: Now you can see that the gain is enormously horrendous. It's everywhere.

JUDGE WALSH: All right. Doctor, would it be reasonable -- would it be medically reasonable to diagnose this plaintiff with FDA-positive aortic regurgitation in the parasternal long axis view?
THE WITNESS: Your Honor, I do not think so, because the ratio is less than 10 percent.
JUDGE WALSH: All right. Well, we've heard of the phenomenon of interreader variability. That's a recognized phenomenon, isn't it?
THE WITNESS: Yes, your Honor.
JUDGE WALSH: Couldn't a person with your skill sets come to a different conclusion and still be in the realm of medical reasonability?
THE WITNESS: 7 percent is close to 10 percent, and I -- possible -- it's possible the reasonable person would say it's a 10 percent or 11 percent or 7 percent.

I stand behind my measurements.

* * * *

JUDGE WALSH: All right. Well, let me ask you this: There were measurements taken by -- in this particular case by Dr. Burnett.
THE WITNESS: Uh-huh.
JUDGE WALSH: In your judgment, were they medically reasonable?

They calculated, essentially, to three measurements, with .33, .35 and .39 on the JH and LVOTs that were all about 1.9. I'll let the numbers speak for themselves. That was -- the measurements that you and Dr. Burnett got on the LVOT were quite similar.
THE WITNESS: Uh-huh.
JUDGE WALSH: And the real difference here, it seems to me, is in the calculation of the JH.
THE WITNESS: Yes, your Honor.
JUDGE WALSH: So, I mean, you'd agree with that characterization; wouldn't you?
THE WITNESS: Yes, your Honor.
JUDGE WALSH: Because I think yours -- your LVOT was 1.86 and Dr. Burnett bracketed that finding by essentially concluding that there were measurements that ran from point -- 1.82, which is lower, to 1.96, which is

> somewhat larger.
> THE WITNESS: Uh-huh.
> JUDGE WALSH: By, I guess about 3 or 4 percent.
> THE WITNESS: That's correct, your Honor.
> JUDGE WALSH: So, are Dr. Burnett's measurements out of the realm of medical reasonability, in your professional judgment?
> THE WITNESS: In my professional judgment, the degree of 18 to 20 percent would be unreasonable.
> JUDGE WALSH: All right. And so the measurements that he took, in your judgment, based on the echocardiogram, in your review of it, were medically unreasonable.
> THE WITNESS: Yes, your Honor.
> JUDGE WALSH: So, I come back to that question again: Would it be medically reasonable for a physician with your skill sets examining this echocardiogram and concluding that there was a JH/LVOT ratio of 10 percent or greater?
> THE WITNESS: I don't -- I stand by my opinion that this is less than a mild aortic regurgitation with a ratio of less than 10 percent.

Dr. Burnett was of the view that Hofeditz has MAR and made three (3) measurements of JH/LVOT (.33/1.82 = 18%; .35/1.96 = 18%; .39/1.93 = 20%). However, during the hearing, Dr. Burnett testified that he had difficulty measuring in the PLAX view although it was available. He also conceded that if he only had the PLAX view available "[y]ou'd have to say I don't have quite enough data to say what the patient had."[18]

---

[18] Dr. Burnett's testimony, in relevant part, is set out below.

> Q. And Doctor, have you had a chance to review the criticisms of Dr. Kaul of the echocardiogram that was conducted?
> A. Yes, I have.
> Q. And you understand Dr. Kaul to be Wyeth's expert in this case?
> A. Yes.
> Q. Okay. And with regard to those criticisms, do you agree or disagree with Dr. Kaul?
> A. With regard to the aorta insufficiency [sic], I do disagree.
> Q. Okay. And do you stand by your original diagnosis of mild to moderate aortic insufficiency [sic]?
> A. No, mild. I would say mild aortic insufficiency.
> Q. And Doctor, with regard to --

JUDGE WALSH: Mitral regurgitation isn't in the case anymore.
MR. D'ANGELO: No, it's not your Honor.
JUDGE WALSH: Okay. Thank you.
Q. With regard to his criticism that only trace is seen in PLAX view do you disagree with Dr. Kaul?
A. I agree that the PLAX view is sub-optimal and that I can understand his criticism.

* * * *

Q. Okay. So, just looking at the aortic valve, Dr. Kaul's criticism is that you overestimated the JH. Would you disagree with him?
A. And we're at Hofeditz. Okay this is the patient that there really wasn't -- there was very -- it was a sub-optimal PLAX for measurement and really picked up the significant A I on the three chamber but the measurements we have that's listed here..33 jet height, the 1.82 LVOT and so forth, is adequate or reasonable to do. We still get over 10 percent on the jet height of the LVOT and that's supported by the three chamber view.
JUDGE WALSH: Well, these were PLAX measurements, right?
THE WITNESS: These were PLAX measurements.
JUDGE WALSH: Okay. They're difficult PLAX measurements.
JUDGE WALSH: All right.
Q. And Doctor, where there's (sic) [the] measurements are difficult would you expect some disagreement among cardiologists --
A. Absolutely, yes.
Q. And disagreement would be reasonable?
A. Yes.
Q. And can there be a disagreement from one level of regurgitation to another say trace to mild, would that be reasonable?
A. Yes, absolutely in that situation.

* * * *

JUDGE WALSH: Okay. And the question we're interested in, Mr. Wheeler asked you was the parasternal long axis view available on this echocardiogram, did you check yes or is your form blank? I.
THE WITNESS: Yell (sic) [Well] I'm sure I did check yes but this form that I have isn't the form that you have it's a different form than you have. This is a different form and my signature is on a different date.
Q. Isn't it in fact your signature on this document Dr. Burnett?
A. Yes, I can authentic that document leafed on the screen, yes and yes, okay I would agree with that (authenticate) I indicated that in November.
Q. You then agree that the parasternal long axis view was available on this study?
A. Yes.
Q. And then you checked below that in the sub-question to number 7 that the PLAX view did in fact in your opinion at least in November of last year purport to show FDA-positive aortic insufficency [sic] correct?
A. Correct.
Q. And as I understand your testimony today it is that the PLAX view is not of sufficient quality in your judgment to demonstrate FDA-positive reg [sic] correct?

* * * *

A. I can't hear all that's going on there, but I have in my notes right here and that's what I'm speaking from after reviewing it again last night was that there was no good place to measure really accurate, but you kind of have what you have and then you try and substantiate that with the other data and if it's not there you can't substantiate it and that's one of the principals of [Weyman] and Feigenbaum that you can't depend on this one -- on this one thing, but ()to that

The Court finds that Wyeth has established that no reasonable medical opinion that Hofeditz had MAR could be based on this echocardiogram. Two reasons motivate this determination. First, review of the echocardiogram convinces the Court that Dr. Burnett improperly overestimated the JH on the observed jet and Drs. Saric and Kaul were correct when they noted that those measurements were medically unreasonable.[19] Second, Dr. Burnett himself expressed doubt as to whether the information available to him in the PLAX view could support his conclusions.

GG. DALE KANE

> point, there was an insufficency [sic] jet that was measured that on review, you know, there are technical difficulties with that measurement after reviewing the whole study and you're going back to that, I would accept that measurement as an appropriate measurement, adequate for the study, but I mean if you're -- if you're a scientist you're not going to be real happy with that. I'm not a scientist to that degree I'm a clinical cardiologist so for me, I I'm really trying to answer the question is this trace mild moderate or severe and hers is mild and to that degree that PLAX measurement however inad -- however sub-optimal it might be supported, was supported by the other data of the echo.
> Q. Dr. Burnett are you aware of the fact that the national class action settlement agreement which governs this litigation requires interpreting cardiologists to diagnose FDA-positive aortic insufficency [sic] in the PLAX view if it is available?
> A. Right. Well, it was available, you know, I think it's fine to argue about the fact that it was sub-optimal. Many of our measurements are. This one was particularly sub-optimal. So, it's more of an issue, but then if you go to the three chamber view, you know, it's clearly mild aortic insufficency [sic].
> Q. Would that three chamber apical view be a short axis view?
> A. No, this was, you know this is an apical view, you can't really get a short axis. If you're asking if this is a parasternal short axis view that I'm talking about, no, it wasn't it was an apical -- it was an apical three chamber view. Go ahead.
> Q. I'm sorry, Doctor, do you agree that if we looked at the PLAX view that was available on this study, one could not reach a medically reasonable conclusion that this patient has FDA-positive aortic insufficiency?
> MR. NAPOLI: Objection.
> JUDGE WALSH: Overruled.
> A. If you had just the PLAX view and you were restricted to the PLAX view, you'd be hard pressed. You'd have to say I don't have quite enough data to say what the patient had.

[19] Dr. Kaul's criticism of Dr. Burnett's measurements is set out below.

> Dr. Burnett cites several time markers that he is relying upon for his opinion that Ms. Hofeditz has FDA Positive aortic regurgitation, and adopts the measurements made by the sonographer at each of those time markers. I disagree with these measurements, as the jet height is overestimated and measured distal of the valve. There is only a tiny pinhole of aortic regurgitation seen, and at no point is the JH/LVOT ratio greater than even 4% in the PLAX view on this echocardiogram.

D. Kane relies on a May 22, 2002 echocardiogram report by Dr. Howard Cohen. Dr. H. Cohen found that Kane had MMR using CAS criteria -- RJA/LAA = 30%.

The echocardiogram was reviewed by three (3) experts: Dr. Kaul, Dr. Saric and Dr. H. Cohen. Dr. Saric found that the echocardiogram was not conducted in a technically adequate manner such that reliable medical conclusions regarding the presence and severity of valvular regurgitation could be drawn from it. He found that the gain including "[c]olor gains were set too high." Dr. Kaul concurred, finding that "[b]oth the B-mode and color gains are high on this echocardiogram." Dr. H. Cohen disagreed, contending that "[t]he echocardiogram settings were appropriate and the study was of diagnostic quality."

Both Drs. Saric and Kaul concluded that this technically deficient echocardiogram could be used to make a diagnosis of exclusion. Both found that D. Kane did not have MMR based on a review of this echocardiogram. Dr. Kaul specifically found that the phenomenon observed was backflow or closing volume.

Dr. H. Cohen disagreed with Drs. Saric and Kaul, but considered that the study quality was poor and the phenomenon he claimed was evidence of MMR occurred in very early systole and was gone after a frame or two.

> Q. I'll show you what -- we won't put it into evidence I'm sure it will be but since it's not one ever frames you cited simply from reviewing the frame I showed that's a high 2D gain, isn't it?
> A. The 2D gain is varied when the echocardiographer takes a picture and he tries to get the best picture he can, it varies the gain, it doesn't just leave it the same for everybody throughout the echo he tries to get the best picture that he can.
> Q. Okay. At least based upon the picture I just showed you, the gain there is pretty high, isn't it?
> A. The gain there gave the best picture that he could get in that view that he was taking at that moment.
> Q. The gain there is pretty high, isn't it?
> A. The gain there is the best picture he could get at that moment.
> Q. Is it high?

A. It's not -- is it high?
Q. The 2D gain on this echo?
A. It's okay. It's not bad.
MS. REED: Which exhibit was that?
MR. RAMSAY: Yeah, I'm not going to put it into evidence. I'm sure -- well, I assume -- what has already been put in.
BY MR. RAMSAY:
Q. Doctor, if in fact it is the determination of the Court that a reasonable -- a medically reasonable assessment of a review of actual realtime loops of this echo do not, in fact, demonstrate that there is regurgitant flow that lasts through most if not all of systole, you would agree that if that in fact is determined to be the fact it would notice (sic) [not] be defined as mitral regurge, isn't that true?
A. Well, it certainly has to last longer than that one moment when the mitral valve closes, which is usually one or two frames when you can get that blue color that may look like a regurgitant flow. It actually is blood going away from the transducer, but it's due to the pressure the left ventricle put on the mitral valve as it closes. That's very, very short. One or two frames.
Q. Okay.
A. So if it lasts significantly longer than that, then it's probably mitral regurgitation.

The Court finds that Wyeth has satisfied it that no reliable medical conclusions could be drawn from this echocardiogram that D. Kane has MMR. The echocardiogram, while poorly done, shows that the phenomenon here was only closing volume.

HH. PATRICK B. KANE

P. Kane relies on a June 24, 2002 echocardiogram performed by Associates in Cardiology, Ltd. and a June 25, 2002 report by Dr. Neal Ruggie. Dr. Ruggie found P. Kane had MMR using CAS criteria -- RJA/LAA = 24%.

The June 24, 2002 echocardiogram was reviewed by three (3) experts: Dr. Schwartz, Dr. Saric and Dr. Ruggie. All three (3) physicians found the echocardiogram to be technically adequate.

Both Drs. Saric and Schwartz disagreed that P. Kane has MMR. Dr. Saric stated that "[t]here is no sustained, high-velocity jet lasting through [the] major part of systole." He further observed that

> [e]ven assuming that the RJA of 1.55 cm² provided by the sonographer at 1:48:36 is accurate (which is not since it represents overtracing of a low velocity flow), and using one of the [two] LAA measurements done several cardiac cycles later (14.73 or 13.54 cm²), RJA/LAA = 11% which is in the range of mild MR. The RJA/LAA ratio of 25% done by the sonographer at 1:48:36 uses unrealistically small LAA (6.18 cm²) due to foreshortening. Normal LAA values: end-systolic area, 19±3 cm²; end-diastolic area 14±4 cm²; see http://www.echobyweb.com/htm_level2_eng/normal_parameters_tt.htm.

Dr. Schwartz concurred, finding the jet was not holosystolic and noting the deficiencies with the study. He found that

> (1) [t]he purported "moderate" mitral regurgitation is present only in the earliest one-third of systole and is therefore not holosystolic. (2) Moreover, two (2) of the three (3) tracings are not of the mitral regurgitant jet at all, but are of high velocity flow in the left atria unrelated to the mitral valve. In particular, the tracings at 1:48:56-l:49:28 and 1:50:15-l:50:40 take place in early diastole, see EKG, and therefore cannot be mitral regurgitation.

Dr. Ruggie disagreed and claimed that the jet need not be holosystolic to satisfy the CAS criteria. The Court disagrees. As noted by Weyman, mitral regurgitation lasts through most or all of systole. The Court also finds that Dr. Ruggie was not acting in a medically reasonable fashion when he traced P. Kane's LAA as 6.177 cm². As noted by Dr. Saric, in other parts of the echocardiogram P. Kane's LAA was measured at 14.73 cm².[20] Studies have shown that the average

[20] Dr. Ruggie, in his cross-examination, practically admits the 6.177 cm² LAA measurement was inappropriate. His testimony is set out below.

> Q. Okay. Let's go to Mr. Kane.

Now, in your initial assessment, Doctor, dated June 25, 2002, which I think is Exhibit D-4156, you assessed Mr. Kane as having a mildly dilated left atrium at 4.5 centimeters, correct?
A. Yes, I did.
Q. Okay. Now, going over to your report, let's look at your RJA/LAA measurement, which I think is at -- hold on. Let me give you the reference number -- KP.S KP.4. That is the tracing of the regurgitant jet at 4.99 centimeters. Is that consistent with your assessment -- I'm sorry -- 1.546 centimeters?
A. Right.
Q. Was that consistent with your assessment in this case?
A. Yes, it was.
Q. Is this, in fact, the image that you relied on to arrive at your assessment?
A. In my re-review of the case, yes, it is.
Q. Is it your testimony that what is contained within the planimetry on this image constitutes high velocity regurgitant flow?
A. Yes, it does.
Q. Okay. Now, within the borders of the planimetry, there is some black represented in there. Do you see that toward the bottom of the image?
A. Yes, I do.
Q. And the black would constitute static blood, wouldn't it, Doctor?
A. It could, yes.
Q. Okay. And, in fact, around the perimeter of the planimetry, there is quite a bit of either black or dark blue; isn't there, Doctor?
A. It depends on your definition of "quite a bit," but there is some there, yes.

* * * *

Q. Doctor, I want to pull up KP.1?
MS. REED: Defense Exhibit 4560.
BY MR. GHOLSON:
Q. Now, this shows a left atrial area of 6.177. Is that consistent with your opinion?
A. Yes, it is.
Q. And is this, in fact, the image that you have relied on to arrive at that opinion?
A. I believe so, yes.
Q. Okay. Now, the cursor shows that this image was acquired in early to mid systole, correct?
A. Correct.
Q. Now, isn't it a fact that the volume -- the point at which the left atrial area is at its greatest would be at end systole, right before the valves open?
A. Say that again.
Q. Well, let me rephrase it.
If one was going to trace the left atrial area to arrive at the maximal area of the left atrium, wouldn't you do that at end systole, when the left atrium was at its greatest volume?
A. End systole. No. You would do that at end diastole. The atrium fills during diastole. It is going to be at its maximum volume at the end of diastole.
Q. The atrium fills during diastole?
A. Yes, it does.
MR. GHOLSON: Okay. Let's look at this -- the next exhibit then. F -- I'm sorry. KP.2. Do you have a number?
MS. REED: Let's call it D4059A.
BY MR. GHOLSON:
Q. Now, this particular tracing --
A. Could I go back to that for a second?

left atrium area is slightly above 14 $cm^2 \pm 3$ cm^2. A LAA of 6.177 cm^2 is well outside the norm and is a clear indication that the 6.177 cm^2 measurement occurred because of foreshortening.

For these reasons, the Court finds that Wyeth has established that it would be medically unreasonable to conclude that P. Kane has MMR based on this echocardiogram.

II. JOAN KENASTON

Kenaston relies on an August 9, 2002 echocardiogram report by Dr. Curtis S. Burnett. Dr. Burnett reported that Kenaston had "mild mitral insufficiency" and "trace to mild aortic insufficiency." While CAS criteria appear to have been used, the worksheet provided to the Court was not readable. The MMR claim was withdrawn.

The echocardiogram was reviewed by three (3) experts: Dr. Chen, Dr. Saric and Dr. Burnett. All three (3) physicians found the echocardiogram to be technically adequate, though Dr. Chen noted "slightly high color Doppler gains" were present and Dr. Saric noted that the study was "[t]echnically suboptimal."

Both Drs. Saric and Chen found there was trace aortic regurgitation. Dr. Chen's remarks are illustrative of both physicians' opinions.

Q. Yes, sir.
A. The atrium fills during diastole while it is pouring into the ventricle. I think the atrial volume will be maximal at the onset of systole, rather than the end of systole, but I have to think about it some more. Okay?
Q. Yes, sir. Feel free to change your testimony on that, if you need to.
A. I certainly would. I'd have to think about it. Okay.
Q. Okay. Looking at the images up here on the screen now, this was acquired at 1:49:39:29, I believe?
A. Okay.
Q. And I believe this is drawn at end systole, according to the cursor. Would you agree with that, Doctor?
A. Probably.
Q. The cursor is right off the end of the T wave?
A. Right off the end of the T wave, right.
Q. Okay. And the left atrial area that is represented here is 14.73, correct?
A. Correct.
Q. Do you have any reason to disagree with this representative tracing?
A. It doesn't look like the way I would have traced it, no.
Q. All right, sir. Would your tracing have been larger or smaller?
A. Larger.

> Tiny aortic regurgitant jet. JH/LVOT ratio is far below 10% by visual assessment. Less than mild aortic regurgitation. The JH and LVOT were measured improperly by the technician. Tiny aortic regurgitant jet was not measured just below the aortic valve. The JH was also beyond jet edges. In addition, LVOT was measured improperly. The LVOT was measured not just below the aortic leaflet insertion, but at the leaflet level by the technician.

Dr. Burnett disagreed and thought that Kenaston had MAR. While his testimony was a bit disjointed, he ultimately based his conclusion on two JH/LVOT readings: .23 cm/1.77 cm and .32 cm/1.84 cm. These compute to 13% and 17.4% respectively.

Dr. Chen reviewed all of Dr. Burnett's measurements and the Court finds that Dr. Chen's criticism is substantiated. The Court accepts Dr. Chen's opinion as its own.

> The measurements of JH on the frame at 1:34:49:11 … and LVOT at 1:35:02:25 … by the technician are improper. Compared to the frame before the measurement at 1:34:43:10 (still frame) or the identical frame at 1:34:38:19 (in real-time), the digital cursor or the center of the digital cross of the measurement is placed too far beyond the anterior and posterior border. The more important error, however, is that the JH was not measured just below the aortic valve. In fact, the proximal part of the jet is missing on the frame the technician selected, even though the tiny, hair-thin AR jet and the parts at and just below the aortic valve can be visualized on the frame immediately before the measured frame (1:34:38:18). Even if one measures the jet height closest to the aortic valve but not the jet height just below the aortic valve (which is missing), the JH is 0.12 cm on this frame (measured on still frame 1:34:43:10….
>
> LVOT was measured at the partially-opened right coronary cusp level, not just below the aortic valve insertion point and is about 1/3 to 1/4 undermeasured, by

my visual assessment. I measured the LVOT on the frame at 1:35:02:25 (same frame as technician's measurement at 1:34:38:18) and obtained a value of LVOT = 2.36 cm…. Thus, JH/LVOT is 5% by my measurement and is not 13% which the technician measured and Dr. Burnett adopted. In real-time images from the cardiac cycle in which the frame was selected by the technician, a tiny, hair thin AR jet was visualized. The AR jet is so tiny that it is visualized only intermittently and appears broken during diastole. Therefore, it is clearly only trace aortic regurgitation which could be used as a classic teaching file of trace aortic regurgitation.

Similarly, the measurements of JH and LVOT at 1:35:39:18 … and 1:35:51:02 … by the technician are not correct either. The technician mistakenly measured the broadest segment of the jet in the middle of the LVOT and did not measure the narrowest height of the jet just below the aortic valve according to Dr. Weyman and Dr. Feigenbaum. The LVOT was measured on a frame that does not show the maximal LVOT. In fact, the maximal LVOT can be visualized at 1:35:43:15, just a few frames before the frame selected by the technician. I normally would not select the frame for measurement since the proximal jet edges are unclear and blurry with excessive color hue, particularly in its proximal part just below the aortic valve. For the sake of comparison between the improper measurement location of JH by the technician in the mid-LVOT, and the correct measurement location of JH just below the aortic valve, I measured JH on the frame selected by the technician and found it to be 0.16 cm…. Note that the still frame is actually selected from real-time images of a cardiac cycle during 1:35:23:18-1:35:24:05 and is at 1:35:23:29 in real-time. As demonstrated in real-time images, there are 5-6 frames in diastole and 2 of them [] have a clearly delineated proximal narrowest part of the AR jet at or just below the aortic valve. Of those frames, JH is tiny

> and hair-thin just below the aortic valve and too tiny to measure (less than 0.1 cm by eyeball).
>
> In summary, there is a tiny, hair-thin, non-continuous (broken) aortic regurgitant jet, unequivocally consistent with only trace aortic regurgitation. There is no FDA positive AR on this study.

For the reasons just stated, the Court finds that Wyeth has satisfied it that no medically reasonable conclusion that Kenaston has MAR could be drawn from review of this echocardiogram.

JJ. DENNIS M. KILGALLON

Kilgallon relies on an April 24, 2002 echocardiogram performed by Cardiac Consultants of Chicago, Ltd. and a report by Dr. Howard Cohen. Dr. H. Cohen found Kilgallon had MMR using CAS criteria -- RJA/LAA = 31%.

The April 24, 2002 echocardiogram was reviewed by three (3) experts: Dr. Chen, Dr. Saric and Dr. H. Cohen. Dr. Saric found this echocardiogram to have been conducted in a technically inadequate manner such that reliable medical opinions regarding the presence and severity of valvular regurgitation could not be drawn from it. He stated that "[c]olor gains (on this Siemens Cyprus system) were very high; this prevents reliable measurement of RJA since high color gains make any jet appear larger than it truly is. In addition, LA[A] border resolution was poor on all apical views preventing accurate LAA determination."

Dr. Chen agreed that the study was only useful as a tool to exclude MMR. He notes "[t]his is a technically limited study with high 2D gain and oblique views. It is nevertheless possible to see that there is no FDA Positive regurgitation."

Dr. H. Cohen disagreed and found that "[t]he echocardiogram settings were appropriate and the study was of diagnostic quality."

The Court has reviewed this study and finds that the echocardiogram settings were not appropriate. The 2-D gain is set so high that any LAA calculation becomes nothing but a guesstimate.

Both Drs. Saric and Chen concluded that despite the study deficiencies, there was no evidence of MMR. Dr. Saric noted that "MR by visual estimate appears

mild" and Dr. Chen agreed. Dr. Chen also provided a detailed review of Dr. H. Cohen's MMR claim, totally demolishing it.

> In real-time and still-frame images, the MR is unequivocally mild, despite the technical limitation of high color Doppler gain, high 2-D gain, and poor study quality, as I mentioned in my prior assessment. Specifically, the color cluster on frame 31:21:02 … is mostly in the left ventricle and is not a mitral regurgitant jet, but probably some kind of artifact. The origin of the peculiar color cluster is uncertain, since there are no corresponding real-time images. In addition, the frames 31:17:29 (actually 3:18:00 in the real-time recording) and 31:33:26 are identical frames, one of which is recorded in real-time and one of which is recorded from a playback cine-loop. I measured the MR jet on frame 3:18:00 and found it to be 1.74 cm^2 … although I normally would not select this frame for measurement, since the jet of this magnitude only appears on that one frame which is in very early systole, and immediately following that frame the jet is tiny. Therefore, flow secondary to mitral valve closure or backflow cannot be excluded, particularly with the high color Doppler gain settings and poor study quality. Even with all the technical limitations and being very generous in actually measuring this, the RJA/LAA ratio is under 10% (using the LAA of 18.09 cm^2 according to my prior measurement) and certainly far less than 20%.
>
> Again, the frames 34:42:23 and 34:44:29 are identical still frames recorded in different times, and are selected from the real-time frame of 34:38:09 during the cardiac cycle of 34:37:27 - 34:38:21. The jet selected is in very early systole, is mixed with artifact, and is followed by a very small jet in the subsequent 2 frames. Therefore, the possibility of a mixture of backflow from mitral valve closure with a real MR jet in these color clusters cannot be excluded. I normally would not have selected such a jet to measure RJA for evaluation of the degree of MR. I have therefore only measured the jet here (at frame

> 34:42:23, an RJA of 1.97 cm² …) for the purpose of demonstrating that even with all the limitations of high color Doppler gain and generous assumptions that the maximal color cluster in the very early systole is truly representative of the maximal MR jet, the MR is clearly mild.

The Court finds Wyeth has satisfied it that this echocardiogram was not conducted in a technically adequate manner such that reliable medical conclusions regarding the presence and severity of valvular regurgitation could be drawn from it. But even if it were to be analyzed, it is apparent that no medically reasonable conclusion that Kilgallon has MMR could be made based on this echocardiogram.

KK. DORIS KING

King relies on an April 5, 2002 echocardiogram performed by Associates in Cardiology, Ltd. and an April 8, 2002 report by Dr. Roger A. Billhardt. Dr. Billhardt found King had SAR by CAS criteria -- JH/LVOT = 50%.

The April 5, 2002 echocardiogram was reviewed by three (3) experts: Dr. Chen, Dr. Saric and Dr. Billhardt. All three (3) physicians found the echocardiogram to be technically adequate.

Both Drs. Saric and Chen found no aortic regurgitation visualized in the PLAX view. This is a startling finding given the fact that Dr. Billhardt initially found King had SAR. Dr. Saric observed that

> [i]t is particularly unreasonable to conclude that the patient has severe AR since such a diagnosis is inconsistent with other aspects of the study. Severe AR comes in [two] varieties: chronic [and] acute. In severe CHRONIC AR, LV is dilated (which is not the case with Ms. King). In severe ACUTE AR, patients are extremely sick requiring intensive care monitoring and are thus unlikely to have come for an elective outpatient echocardiogram as Ms. King apparently did.

Dr. Chen was perhaps more generous, simply observing:

> There is no aortic regurgitant jet visualized in the parasternal long axis view with color Doppler flow mapping. The aortic regurgitant jet measured by the technician was in the apical view and was measured improperly. The jet height was measured not just below the valve and too far into the LV side. The LVOT was measured in the oblique view and was undermeasured. In fact, the proximal part of the aortic regurgitant jet was not visualized in the frame selected and measured by the technician.

Dr. Billhardt admitted that no aortic regurgitation was seen in the PLAX view, begging the question of how this desperately ill woman's medical condition could be completely missed on a standard view only to then show up in another view. Nevertheless, Dr. Billhardt claimed to see SAR in the apical long axis view.

The Court finds that because the PLAX view was available and showed no aortic regurgitation, let alone SAR, that ends the matter. Even if one were to consider the apical view here, the Court rejects Dr. Billhardt's conclusion for the reasons stated in Dr. Chen's rebuttal certification.

> Dr. Billhardt claims that he measured a JH/LVOT ratio of 50% (measuring 0.9 cm/1.8 cm) in the apical 2-chamber view, but does not identify a specific frame or time marker. Therefore, I cannot comment on his specific measurements. However, even if it were appropriate to measure in an apical view, the standard apical 2-chamber view includes the left atrium and left ventricle, with the mitral valve separating them, and certainly the standard 2-chamber view does not include the aortic valve. Therefore, JH/LVOT cannot be measured in the apical 2-chamber view in standard clinical practice.
>
> There are measurements made in another apical view - the apical 3-chamber view - with color Doppler imaging in this study. The technician selected and measured a JH and an LVOT in this 3-chamber view. The technician's measurement is 0.92/1.82 (50%) on a still frame at time marker 1:43:09:13 …, which is close to Dr. Billhardt's

asserted JH/LVOT values, so these may be the measurements on which he relies. However, that frame, and those measurements, cannot be relied upon, primarily because they are taken from a view that is simply not allowed under the Settlement, and secondarily because the measurements themselves were improperly made in several respects. I normally would not consider the amorphous color cluster measured by the technician in the LVOT an "AR" jet since the color cluster represents low velocity flow (no aliasing, with a flow velocity lower than the Nyquist limit of 53 cm/s [sic] according to the real-time images) and does not show a clear connection to the aortic valve, as evidence by a gap between the color cluster and the aortic valve. Therefore it is nota [sic] typical aortic regurgitant jet which would include a high velocity proximal part of a low velocity distal part.

Even if one were to use liberal imagination or generously guess that the color cluster were the distal, low velocity part of the AR jet on the frame selected by the technician, assuming that the proximal part of the jet just below the aortic valve were missing and out of the tomographic plane (view) - and the AR jet were [sic] imaged obliquely - the technician measured the low velocity or distal part of the "AR" jet width which is not the JH that can be used for calculation of JH/LVOT, for assessment the of (sic) [of the] degree of AR according to Dr. Weyman's and Dr. Feigenbaum's textbooks. According to the textbooks, the JH should be measured at or just below the aortic valve on a developed AR jet. A jet that is clinging to the aortic cusp or leaflet, or that is not fully developed cannot be measured for its JH.

The real-time images (1:42:39:03 - 1:42:43:00), the proximal segment of the AR jet is so tiny that it drops out intermittently and is clearly trace at most in the apical view. It is also important to note that the tiny AR "jet" is unsteady and has either a broken (appearing intermittently in 2-3 of 6-7 diastolic frames), missing, or clinging proximal part of the AR jet just below the aortic

> valve in the apical view, so it should not be measured to reflect the degree of aortic regurgitation in this case, even if it were appropriate to measure in an apical view.
>
> Additionally, the LVOT was measured improperly by the technician. It was measured in the apical view, which is an oblique LVOT view and is not the maximal LVOT, such as can be visualized in the PLAX view.

In sum, Wyeth has established that no reasonable medical conclusion that King has MAR, let alone SAR, can be drawn from review of this echocardiogram.

LL. BOBBI JO C. LAPEE

Lapee relies on a December 19, 2002 echocardiogram report by Dr. Jason Lazar. Dr. Lazar found Lapee had MMR and MAR using CAS criteria -- RJA/LAA = 25% (averaged); JH/LVOT = 13%. Only the MMR was pursued in this hearing.

The echocardiogram was reviewed by three (3) experts: Dr. Teichholz, Dr. Saric and Dr. Lazar. Both Drs. Saric and Teichholz[21] found that the echocardiogram was not conducted in a technically adequate manner such that reliable medical conclusions regarding the presence and severity of valvular regurgitation could be drawn from it. Dr. Saric reported that "[c]olor gains on this Siemens Cypress system were so high that the color speckles often fill almost the entire color box. High color gains make any jet appear larger than it truly is." Dr. Teichholz echoed these views, stating that "[t]he color Doppler gain is set improperly high on this echocardiogram, causing visualization of noise and making accurate measurement of regurgitation unreliable and likely exaggerated."

Dr. Lazar insisted that the echocardiogram was technically adequate, but his certification is belied by the echocardiogram which was of extremely poor quality. Ultimately, at the hearing he admitted the gain was "high" but not too high to read.

Both Drs. Saric and Teichholz concluded that even with the high gains, MMR could be excluded. Dr. Saric said there was "only a trivial amount of MR." Dr. Teichholz testified

[21] Dr. Teichholz marked the Echocardiogram Review and Assessment Report "Yes" as to its technical adequacy. He explained in his testimony this was an error. He also reported the technical deficiencies on the Echocardiogram Review and Assessment Report.

> Q. And even with the high gain settings on this echo, do you see any mitral regurgitation on this echo?
> A. I don't see anything on this echo with this gain that I would actually call mitral regurgitation. There may be, if you look very carefully, right behind the valve a teeny bit of early back flow, but I would not call this mitral regurgitation.
> Q. All right. Dr. Lazar does a tracing of page 21. That's attached to his affidavit which is defense Exhibit 4218 and it's page 21 of the Dicom.
>
> Dr. Lazar's tracings are actually slightly different than that displayed on the screen. But [] before we talk about his tracings, can you describe what opinions you have about his decision to trace this jet?
> A. Okay. First, just pointing out, A is a trace of what is purported to be a jet of mitral regurgitation; and B is what is purported to be left atrial size. Number one, if you look at the purported jet, it is laminar blue flow and b[l]ack. There is no turbulent flow in this despite the fact that the Nyquist is at a marginal level of 51 [cm/sec]. I see no turbulent flow. I only see blue flow. The second thing is this does not have the appearance of a jet in terms of its more of a diffuse color.
>
> The third [th]ing is if you look below this jet, the so-called jet, you see a lot of red. And that red is not aliased flow, because it's out in the middle of nowhere. That's just noise. And a lot of what is being traced, if not all of what's being traced, represents noise in the left atrium.
>
> The second thing is where is the left atrium? And I would contend that this is a [foreshortened] view of the left atrium. What is traced here has no relationship in any way, shape or form to any visual boundaries that any competent echocardiographer would attempt to trace.

The Court finds that Wyeth has established that this echocardiogram was not conducted in a technically adequate manner such that reliable medical opinions regarding the presence and severity of valvular regurgitation could be drawn from it. Even if this echocardiogram could be used, the Court rejects Dr. Lazar's

conclusion that Lapee has MMR. The RJA tracing used to support his conclusion is clearly overtraced and includes flow above the mitral valve. Further, the traced RJA is laminar blue. Finally, the LAA tracing has no support since the cardiac structures are not visualized on the frame. Accordingly, the Court further finds that Wyeth has established that no reasonable conclusion that Lapee has MMR can be drawn from review of this echocardiogram.

MM. ELAINE E. LEE

Lee relies on an October 29, 2002 echocardiogram report by Dr. Herbert J. Semler. Dr. Semler found Lee had MAR using CAS criteria -- JH/LVOT = 18%.

The echocardiogram was reviewed by three (3) experts: Dr. Schwartz, Dr. Saric and Dr. Lazar. All three (3) physicians found the echocardiogram to be technically adequate.

Both Drs. Saric and Schwartz found no MAR. Dr. Schwartz found "[t]he purported aortic insufficiency is very brief, lasting [one] or [two] frames at most, and is not holodiastolic. This is clearly trace aortic insufficiency as seen in the parasternal long axis view at 0:17:00 and in the apical 3 at 0:24:45." Dr. Schwartz chose not to measure this trace regurgitation, but Dr. Saric did. Dr. Saric found JH/LVOT = 5.5% at 16:53:02 and JH/LVOT = 5.6% at 16:54:20, both in the PLAX view. In both instances, Dr. Saric found a JH of .11 cm. His LVOT measurements were 1.97 cm and 1.94 cm, respectively.

Dr. Lazar found that Lee had MAR with JH/LVOT ratios of 14%; his LVOT measurements of 1.9 cm and 2.0 cm were quite close to Dr. Saric's but his JH measurements were .27 cm and .29 cm which were quite different. Dr. Lazar conceded that the jet he saw was not holodiastolic. However, in one loop he reported aortic jets present in four (4) to five (5) frames or about 40% of the diastolic cycle. In several others, he could only identify a jet in one (1) or two (2) frames.

The Court believes that Wyeth has established that no reasonable medical opinion that Lee has MAR could be based on this echocardiogram. The jet was not holodiastolic when all the loops on the echocardiogram are considered. But even if one were to consider the phenomenon to be holodiastolic, Dr. Saric's measurements show that the aortic regurgitation was trace. Having reviewed this echocardiogram, the Court believes that Dr. Lazar improperly overtraced the width of the aortic jet and did not measure it at a point proximal to the valve annulus.

NN. MICHAEL P. LOMBARDI

Lombardi relies on a November 22, 2002 echocardiogram report by Dr. James Colasacco. Dr. Colasacco found Lombardi had MMR using CAS criteria -- RJA/LAA = 29%. Dr. Colasacco reported that this was a "[g]ood quality echocardiogram."

The echocardiogram was reviewed by three (3) experts: Dr. Teichholz, Dr. Saric and Dr. Colasacco. Dr. Saric found that the echocardiogram was technically marginal. Dr. Saric found "[t]his study, apparently acquired using the Siemens Cypress system, is barely interpretable since its color gains are very high."

Both Drs. Saric and Teichholz concluded that color Doppler reflected only closing volume and not mitral regurgitation. Dr. Saric noted "[e]ven with the high color gain settings, no su[s]tained aliased jet of MR is identifiable on real-time loops. Instead, a low-velocity laminar flow lasting usually a single frame is seen; it likely represents the closing volume." Dr. Teichholz agreed and reported that "only backflow, and not mitral regurgitation, appears on this echocardiogram. The sonographer traces single, early systolic frames of color as RJA, including laminar blue low velocity flow and black signals. The LAA is also undertraced."

Dr. Colasacco disagreed finding MMR in three (3) measurements of RJA/LAA = 29%, 28% and 28%, respectively. However, review of the media makes it clear that the jet is seen usually only in one (1) frame in very early systole. Dr. Colasacco acknowledged this during his testimony.[22]

---

[22] Dr. Colasacco's testimony on Lombardi appears below.

> Q. [Y] ou believe this is a technically-adequate study too correct?
> A. Correct.
> Q. Let's look at the apical loop in real-time and this is page 17 of 45 of the Dicom which is Defense Exhibit 4067. And the gain is high here, isn't it Doctor?
> A. No, not unreasonably so. Is it mildly high, yes.
> Q. It's mildly high because (sic) [but] you still believe it's interpretable?
> A. Yes.
> Q. And this is an apical view; correct?
> A. That is correct, an apical -- well it looks like an apical four since you can see the right sided chambers.
> Q. And you do see mitral regurgitation here?
> A. That is correct.
> Q. Let's go to frame 1 of this Dicom -- of this slide -- I mean of this page.
> A. Okay right there you see mitral regurgitation.
> Q. I want to go to page 1, I want to go to the very slide of this?

* * * *

Q. I'm seeing 17. This is the very beginning of systole correct?
A. Correct.
Q.
MR. AGNESHWAR: And just hold it right there, TJ.
Q. And the Mosaic pattern that you see or actually the bluish pattern that you see on this screen is what you call mitral regurgitation?
A. I agree with you. In the beginning the Mosaic pattern and the left atrium, I consider mitral regurgitation.
Q. Okay. And if this was holosystolic, we will see it in the next frame; correct?
A. No, that's not true.
Q. You won't see it in the next frame?
A. The diagnosis physiologically of mitral regurgitation is a holosystolic. It does not mean that in a [D]oppler study that you'll see it continuously because of the transducer.
Q. Okay, let's go to the next frame. Is there any mitral regurgitation here in frame 2?
A. No, there is not.
Q. What about frame 3, any mitral regurgitation here?
A. No, there's not.
Q. Frame 4. Any mitral regurgitation here?
A. No, there's not.
Q. In fact there's just no color at all right?
A. Correct so you couldn't make a determination.
Q. Let's go to the next frame. Any mitral regurgitation here?
A. Actually there's no color flow there.
Q. All right so in least this view that I showed you of the apical view in real-time going frame by frame the mitral regurgitation jet that you peered appeared in one frame?
A. There is I [sic] mitral regurgitation in this study correct.
Q. My question was, Doctor, in what I just showed you, the mitral regurgitation jet, the jet that you identified as mitral regurgitation was seen in one frame and was not seen in subsequent frames in systole; correct?
A. It was seen in the frame that shows color [D]oppler. The other slides didn't have color flow, in particularly this slide here.
Q. Is there not blue at the top of this screen?
A. But this particular slide doesn't have adequate [D]oppler for me to make a diagnosis.
Q. Okay let's keep going. Tell me when we're in systole again.
A. Okay go back one frame.
Q. And this is the next cardiac cycle correct?
A. Correct.
Q. And we're now at the onset of systole; correct?
A. Correct.
Q. And you see a little bit of what you'd call Mosaic flow here?
MR. NAPOLI: Objection to a little bit.
A. I see Mosaic flow.
Q. Let's go to the next frame is it there?
A. I don't see it there.
Q. Next frame is it there?
A. No, I do not.
Q. Next frame is it there?
A. No, I do not.
Q. Next frame, is it there?
A. I wouldn't call on that frame because there's not enough color flow there.

The Court finds that Wyeth has established that no reasonable medical opinion that Lombardi has MMR could be drawn from this echocardiogram. First, the technical quality is marginal making the quantification of MMR difficult, if not impossible. Second, the "jet" appears only in the first systolic frame, a telltale sign of closing volume.

OO. REGINA K. McGOVERN

McGovern relies on an October 2, 2002 echocardiogram report by Dr. James Colasacco. Dr. Colasacco found McGovern had MMR using CAS criteria -- RJA/LAA = 30%. Dr. Colasacco reported this echocardiogram was "[g]ood quality."

The echocardiogram was reviewed by three (3) physicians: Dr. Teichholz, Dr Millman and Dr. Colasacco. Both Drs. Millman and Teichholz found the echocardiogram was not conducted in a technically adequate manner such that reliable medical conclusions regarding the presence and severity of valvular regurgitation could be drawn from it. Dr. Millman found that "[t]he color [D]oppler gains were set extremely high so that the preponderant (sic) [predominant] signal was 'noise.' There is no meaningful color Doppler data which can be derived from this study." Dr. Teichholz concurred, "[t]he color [D]oppler gain is set improperly high on this echocardiogram, causing visualization of noise and making accurate measurement of regurgitation unreliable and likely exaggerated."

Dr. Colasacco, as noted, disagreed, finding "[t]he echocardiogram settings were appropriate and the study was of diagnostic quality." During the hearing, he conceded the gain was "high."[23]

Q. But in the prior three frames we don't see any; correct?
A. Correct.
Q. So, in both the loops that I showed you it lasted a single frame?
A. There was mitral regurgitation on those single frames, yes.

[23] Dr. Colasacco's testimony on this point is as follows:

Q. Let's go on to McGovern. And again you believe this was a technically-adequate study. Let's look at the apical view in real-time page 31 of 49 of Defense Exhibit 4070. Doctor, is this an apical view?
A. Yes, it is.
Q. Is the gain high?
A. I would call it high, yes.

Both Drs. Millman and Teichholz looked at this technically inadequate echocardiogram and could not find evidence of mitral regurgitation. Dr. Millman found that the study was

> inadequately performed since no meaningful interpretation is possible with so high a color [D]oppler gain setting. The only mitral regurgitation demonstrated is "physiologic" and occurs when the mitral valve closes at the beginning of systole. No holosystolic signals are demonstrated. In addition, the left atrial area cannot be determined from the views produced, since the left atrium is foreshortened and poorly seen.

Dr. Teichholz made the same finding.

> Only backflow, and not true mitral regurgitation is seen on this echocardiogram. The sonographer measures RJA in a single frame, and the dynamic cardiac cycle from which it was taken does not appear to be on the study. When viewed in motion only a physiologic amount of mitral regurgitation is seen in one or two frames. The left atrial walls are difficult to see in the frames where LAA is measured, and left atrium is measured in a foreshortened plane, making it unlikely that it is an accurate measurement.

The Court finds that Wyeth easily established that the echocardiogram was not conducted in a technically adequate manner such that reliable medical conclusions could be drawn from it. This is a truly horrible echocardiogram. Nevertheless, it is also clear that no mitral regurgitation worth mentioning, let alone MMR, can be seen on it.

PP. KATHLEEN E. McLAUGHLIN

McLaughlin relies on a May 30, 2002 echocardiogram performed by the University of Wisconsin Hospital Adult Echocardiography Laboratory and a report by Dr. Peter S. Rahko. Dr. Rahko found McLaughlin had MAR using CAS criteria -- JH/LVOT = 16%. Dr. Rahko concluded that the study quality was "good."

The May 30, 2002 echocardiogram was reviewed by three (3) experts: Dr. Schwartz, Dr. Millman and Dr. Rahko. All three (3) physicians found the echocardiogram to be technically adequate.

Both Drs. Millman and Schwartz found no aortic regurgitation in the PLAX view. Dr. Millman reported that "[t]here was no aortic regurgitation in the pslax (PLAX) view." Dr. Schwartz concurred, noting that "[t]his parasternal long axis view was available and well-visualized, and there was no aortic regurgitation seen at all in this view."

Dr. Rahko agreed that no regurgitation was seen in the PLAX view, but found aortic regurgitation in the apical long axis view. He could not confirm it with spectral Doppler. He confirmed his position in his testimony during the hearing.

> Q. On this particular echo regarding Ms. McLaughlin, the technical quality of the echo was adequate, was it not?
> A. It was.
> Q. And the parasternal long axis view was available for a significant period of time on that echo, was it not?
> A. That is correct.
> Q. And it did not -- and you didn't see any AI in the PLAX view, did you?
> A. I did not see any AI in that view.
> Q. All right. Doctor, Let us briefly go then to --
> JUDGE WALSH: No, before we go, Doctor, do you understand that under the class action settlement agreement that the PLAX view if available is only permissible view.
> THE WITNESS: Well, your Honor, I did not understand that and it was unclear to me this entire time and even on this revised form, if I didn't see anything in that view and it was technically adequate, if we were then done, that was fine.
>
> My understanding was if it wasn't anything there, that then you'd go interrogate the other view. If that's not the case, then, you know, the view is there, the insufficiency jet is not seen and that's it.
> JUDGE WALSH: Okay.

> Q. Doctor, if we can --
> A. I mean -- go ahead.
> JUDGE WALSH: Go ahead. Finish your point, Doctor.
> A. Well, I mean, I'm just used to reading echocardiograms using information from multiple views.
> JUDGE WALSH: I understand what you're saying, Doctor. This is -- has certain artificiality to it, but there are these criteria. Let me ask you this: In your most recent submission, you said the parasternal view was technically poor. I think previously, if I understood, and just now you said it was adequate. What is it?
> A. Well, the two dimensional view is good. The color Doppler isn't quite so good, but it's still technically adequate.

The Court finds that Wyeth has established that no reasonable medical conclusion could be drawn from the PLAX view of McLaughlin's echocardiogram that she has MAR.

QQ. UNICE McREYNOLDS

McReynolds relies on a July 13, 2002 echocardiogram performed by Associates in Cardiology, Ltd. and a July 16, 2002 report by Dr. Roger A. Billhardt. Dr. Billhardt found that McReynolds had MMR using CAS criteria - RJA/LAA = 24%.

The July 13, 2002 echocardiogram was reviewed by three (3) experts: Dr. Schwartz, Dr. Millman and Dr. Billhardt. All three (3) physicians found the echocardiogram to be technically adequate.

Both Drs. Millman and Schwartz failed to find MMR. Dr. Millman observed:

> The only mitral regurgitant signal seen in any view was only a few frames in duration, and represents the "closing puff" of physiologic "mitral regurgitation," a normal finding. True mitral regurgitation would be holosystolic in nature, a finding clearly not present here. The only exceptions would be eccentric mitral regurgitation from a structural abnormality such as flail [sic] mitral leaflet, rheumatic heart disease or ischaemic heart disease.

Dr. Schwartz concurred, finding "[t]he purported mitral regurgitation … [to be] brief and not holosystolic."

Dr. Billhardt disagreed. He measured the RJA/LVOT = 28% but his measurement of the LAA as 7.06 cm² is highly suspect. Dr. Billhardt is suggesting that this 5'5" 250 pound female has a left atrial area smaller than over 95% of adults.[24] Dr. Billhardt conceded that the jets observed here were in early systole

---

[24] Dr. Billhardt's testimony on this score appears below.

> Q. Okay. We can go to McReynolds, please.
>
> Now, I believe you -- your opinion was that Ms. McReynolds had moderate mitral regurgitation, based on your assessment, right?
>
> A. That's correct.
>
> Q. And I want to go back to your original screener's report --
>
> A. Uh-huh.
>
> Q. -- which was dated 7/13/02 and I think is in evidence as D4168.
>
> Do you have that in front of you, Doctor?
>
> A. I do.
>
> Q. Now, on that study, you calculated a left atrial dimension on the M-mode at 4.3 centimeters, correct?
>
> A. Yes.
>
> Q. And based on that measurement, which was in excess of 4 centimeters -- which I understand is the upper limit of normal for that, right?
>
> A. Yes.
>
> Q. You said that she had a mildly dilated left atrium, correct?
>
> A. That's correct.
>
> * * * *
>
> BY MR. GHOLSON:
>
> Q. Okay. Now, Doctor, this is an image that appears at 1:21:20:05 on the study and purports to show a measurement of 1.952 centimeters for regurgitant jet area and 7.057 centimeters for the left atrial area.
>
> Are those consistent with your opinions?
>
> A. Those are the ones that I had down on my re-review.
>
> Q. Okay.
>
> A. Now, since there is a 28 percent regurgitant jet to left atrial area on my re-review and a 24 percent on the initial review, there may have been another one that I looked at initially or else I used the calculator incorrectly.
>
> Q. Well, for the purpose of this certification, is this the image that you relied on to arrive at your opinions?
>
> A. This is the image that I relied on to make my amended report or my second report.
>
> Q. All right, sir. Now, you came up with a left atrial area of 7.057 centimeters squared?
>
> A. Correct.
>
> Q. In your opinion, does that represent a small left atrial area for an average adult?
>
> A. Yes. For a patient -- the patient's size, 250 pounds, 5'5", that would be not a large left atrium.

and were not holosystolic. Although he claims that mitral regurgitation need not occur during most or all of systole,[25] the Court disagrees. As repeatedly noted, most experts and texts require this condition to be met.

The Court finds that Wyeth has established that no reasonable medical conclusion that McReynolds has MMR may be drawn from review of this echocardiogram. Wyeth has shown the alleged regurgitation was not holosystolic and that Dr. Billhardt's LAA measurement was at least unlikely and probably incredible.

RR. AUDREY D. MELVIN

Melvin relies on a September 27, 2002 echocardiogram report by Dr. James Colasacco. Dr. Colasacco found that Melvin had MMR using CAS criteria -- RJA/LAA = 39%. Dr. Colasacco found the study to be "[g]ood quality."

The echocardiogram was reviewed by three (3) experts: Dr. Teichholz, Dr. Millman and Dr. Colasacco. Both Drs. Millman and Teichholz found that the echocardiogram was not conducted in a technically adequate manner such that reliable medical conclusions regarding the presence and severity of valvular

---

> Q. And according to Weyman, Doctor, the mean area for a left atrium would be 14.2 plus or minus 3 centimeters. Would that be consistent with your experience?
> A. Yes.
> Q. All right. And in this case where you have got a left atrial area of 7.05 centimeters, did that raise a suspicion in your mind that the image that was being measured was, perhaps, not accurate?
> A. Well, it raises a suspicion that there could be error in the calculations, but we had to go with what we could actually see. So I think that we traced out what was there in front of us.

[25] Dr. Billhardt's testimony on this score appears below.

> Q. Now, your echocardiograms have also been reviewed by other physicians, and one of the criticisms that have [sic] been levied is that what has actually been planimetered was closing volume.
> Could you comment on that, please?
> A. Well, mitral regurgitation can occur at any time through the cardiac cycle end (sic) [and] systole, and the difficulty with the planimetry of each of these jets is that we have only a certain period of time that we can actually look at the information.
> And mitral regurgitation does not have to be holosystolic. It can occur early or in the mid portion of the -- of systole or it can occur late in systole. So a criticism that the regurgitation was occurring only early, I don't think, is one that can be made.
> Closing volume is not something that I routinely see in my practice. If there is no mitral regurgitation, we won't see any regurgitant jet, even though the mitral leaflets may slam shut with great force. If there is no regurgitation, there is no regurgitation.

regurgitation could be drawn from it. Dr. Millman concluded that "[t]he color [D]oppler gains were set so high that no meaningful data can be retrieved. It is impossible to characterize any regurgitant or stenotic signal on color [D]oppler with this gain setting." Dr. Teichholz agreed: "This is a poor quality study. The color [D]oppler gain is set improperly high on this echocardiogram, causing visualization of noise and making accurate measurement of regurgitation unreliable and likely exaggerated."

Dr. Colasacco disagreed with these conclusions, noting that "[t]he echocardiogram settings were appropriate and the study was of diagnostic quality." During the hearing, Dr. Colasacco conceded that the quality was less than ideal.[26]

---

[26] Dr. Colasacco's cross-examination testimony is reproduced below.

> Q. Okay. Let's move to Melvin. Let's play -- let's go to Defense Exhibit 4073, which is the Dicom study. And it's page 16 that I want to go to.
> Does this reflect high gain, Doctor?
> A. Yes. The gain is higher than I would like.
> Q. But you believe this is a reasonable gain from which you can quantity (sic) [quantify] mitral regurgitation?
> A. Yes.
> Q. All right. And again if we play this frame by frame, you should be able to identify the mitral regurgitation; correct?
> A. Correct.
> Q. Okay. Let's start with frame 1?
> A. Go back one frame.
> Q. This is the first frame?
> A. I'm just asking to go back one frame. Okay go to the next. On this frame there's a suggestion based on the speckling. Would I call it mitral regurgitation, no.
> Q. Are we in systole?
> A. Based on the telemetry from below, yes.
> Q. Let's go to frame 2. Can you discern any mitral regurgitation here?
> A. Again I see some Mosaic pattern below the mitral valve. I don't think I would make the call of mitral regurgitation from that -- from that frame.
> Q. Okay. Can you tell me what Mosaic pattern you're seeing below the mitral valve that you might call mitral regurgitation?
> A. Again, it would be that yellowish area within the blue. But, again, I would not call it mitral regurgitation.
> Q. You would not call it -- okay. Let's good to frame 3. Would you call it mitral regurgitation here?
> A. No, I don't see a Mosaic pattern below the valve.
> Q. Let's go to frame 4.
> Would you call it mitral regurgitation here?
> A. I would not.
> Q. And we're still in systole, are we not?
> A. You're correct.
> Q. Let's go to frame 4. Do we see any mitral regurgitation here?
> A. I would not from this.
> Q. Okay. Frame 6. Are we in systole still?

Both Drs. Millman and Teichholz found no indication of mitral regurgitation on this echocardiogram. Dr. Millman could not see anything because of the gain. Dr. Teichholz observed that "[a]t most, a trace amount of mitral regurgitation is seen below the mitral valve on only a few frames of this study. The sonographer traces a lot of red signal, which does not make physiologic sense as mitral regurgitation would be moving away from the transducer and thus would present as blue signals."

The Court finds that Wyeth easily met its burden to establish that no reasonable medical conclusion could be drawn from this technically flawed echocardiogram that Melvin has MMR.

SS. DEBRA MESSER

Messer relies on an August 17, 2002 echocardiogram and a report by Dr. Robert Smith. Dr. Smith found Messer had MMR apparently using CAS criteria -- RJA/LAA = 22% to 30%.

The August 17, 2002 echocardiogram was reviewed by three (3) experts: Dr. Teichholz, Dr. Millman and Dr. Charash. Both Drs. Millman and Teichholz concluded that this echocardiogram was not conducted in a technically adequate manner such that reliable medical conclusions regarding the presence and severity of valvular regurgitation could be reliably drawn from it. Dr. Millman found "[t]he Doppler gains were set too high, increasing the background noise to an excessive degree. In addition, the Nyquist limit was set too low at 46 cm/sec, which will further enhance signals not really present." Dr. Teichholz was in accord, noting "[t]he Nyquist limit on Ms. Messer's echocardiogram of 46 cm/sec is abnormally low. Moreover, the gain settings on this study are set much too high. This combination of a low Nyquist limit and a high gain setting can produce artifacts and 'noise' that can then be misinterpreted as regurgitation."

A We're -- we're at the end of systole and there's -- the gain is too high in this particular slide to made (sic) [make] a diagnosis.
Q. All right. So, in this loop, you wouldn't be able to identify mitral regurgitation and in the one frame where you saw stuff you said the gain is too high; correct?
A. Correct.

Dr. Charash found the study technically adequate but made no other comments on the subject, other than to indicate the echocardiogram settings were appropriate -- a conclusion this Court rejects.

Both Drs. Millman and Teichholz failed to find MMR on the echocardiogram, although Dr. Millman believed there was some mitral regurgitation.

> The areas measured are done only under the improper gain and Nyquist levels indicated above. However, there is some mitral regurgitation present. On "page 41" there is an eccentric mitral regurgitant signal which is mild in nature. It is not the typical mitral regurgitation of a diet drug, and its eccentricity suggests an underlying anatomic cause which the current study is too limited to define.

Dr. Teichholz had a similar take.

> The improper Nyquist and gain settings on this echocardiogram makes accurate quanitification of the RJA/LAA ratio problematic. Regardless, the sonographer overtraces RJA to include low velocity laminar blue flow, and traces a "jet" that is not holosystolic. The left atrial walls are difficult to visualize, making it unlikely that the LAA measurement is accurate.

Dr. Charash found MMR with a RJA/LAA = 22% at an identified position on the media. Dr. Teichholz criticized Dr. Charash's measurements in his reply certification, which the Court has reviewed and agrees with.

> Dr. Charash does not specifically address the criticisms I identified in my original review of this echocardiogram. As I previously stated, the Nyquist limit of 46 cm/sec is abnormally low and the gain setting is abnormally high on this echocardiogram, creating artifacts and noise and making this echocardiogram technically inadequate.

> Dr. Charash relies on the sonographer's tracings at time marker 13:24:55 (Page 44), where there are measurements of RJA/LAA = 3.17/14.33 (22%), for his opinion that Ms. Messer has moderate mitral regurgitation. This frame suffers from the technical inadequacies I have identified (Nyquist of 46 cm/sec and high gain), evidenced by large amounts of red color in the left atrial blood pool. Also, the RJA is overtraced including low velocity laminar blue flow. Furthermore, when the motion loop from which this still frame was taken is viewed, it is clear that this "jet" occurs in early systole and is not holosystolic.

The Court finds that Wyeth easily established that this echocardiogram was so technically deficient that no reasonable medical conclusions could be drawn from it. The Nyquist limit of 46 cm/sec is far below standards and the gain setting is unreasonable. No reasonable medical conclusion that Messer has MMR could be drawn from this echocardiogram.

TT. ADRIANNE A. ORNELAS

Ornelas relies on a May 17, 2002 echocardiogram report by Dr. Howard Cohen. Dr. H. Cohen found Ornelas had MMR using CAS criteria -- RJA/LAA = 25%.

The echocardiogram was reviewed by three (3) experts: Dr. Schwartz, Dr. Millman and Dr. H. Cohen. Both Drs. Millman and Schwartz concluded that this echocardiogram was not conducted in a technically adequate manner such that a reliable medical conclusion regarding the presence and severity of valvular regurgitation could be drawn from it. Dr. Millman complained that "[a]lthough the Nyquist limit of 80 cm/sec is appropriate, the color signal and the two dimensional echocardiogram quality was abysmal. No significant regurgitant signals could be extracted from this study." Dr. Schwartz concurred, stating "[t]his echocardiogram is technically inadequate. The 2-D gain and resolution are exceedingly poor, thus obscuring or washing out the color flow." Neither expert could evaluate the MMR claim because of the poor quality of the echocardiogram.

Dr. H. Cohen claims that "[t]he echocardiogram settings were appropriate and the study was of diagnostic quality." The Court has reviewed this echocardiogram and has considered Dr. H. Cohen's testimony. It finds his testimony to be incredible. Given the 2-D gains, one cannot measure the LAA, obviously a necessity for a MMR diagnosis.

The Court finds that Wyeth easily has demonstrated that this echocardiogram was not conducted in a technically adequate manner such that a reasonable medical conclusion regarding the presence and severity of valvular regurgitation could be drawn from it. This echocardiogram was of such poor quality that any measurements taken from it must be regarded as pure fiction.

UU. DOROTHY ORTIZ-GWITT

Ortiz-Gwitt relies on an April 27, 2002 echocardiogram performed by Cardiac Consultants of Chicago, Ltd. and a report by Dr. Richard Levinsky. Dr. Levinsky found Ortiz-Gwitt had MMR using CAS criteria -- RJA/LAA = 30%. Dr. Levinsky commented that this was a "technically difficult study."

The April 27, 2002 echocardiogram was reviewed by three (3) experts: Dr. Schwartz, Dr. Millman and Dr. H. Cohen. Both Drs. Millman and Schwartz found that this echocardiogram was not conducted in a technically adequate manner such that reliable medical conclusions regarding the presence and severity of valvular regurgitation could be drawn from it. Dr. Millman determined that:

> The 2-D gain settings were too high obscuring the left atrium, particularly in the apical views. There was poor color signal and no mitral regurgitation. No meaningful data is extractable from this study regarding aortic or mitral regurgitation.

Dr. Schwartz concurred, finding that "[t]he color Doppler gain was very high and the image quality was too poor, making it difficult to make an accurate assessment of the presence and severity of regurgitation, if any."

Dr. H. Cohen apparently ignored his own colleagues' concern about the quality of the study, pronouncing that "[t]he echocardiogram settings were appropriate and the study was of diagnostic quality." The Court disagrees. This echocardiogram is of such poor quality that it is useless as a diagnostic tool. To the extent that anything can be seen on this echocardiogram, the purported jet

occurs at the onset of systole and is consistent with backwash or closing volume. That is certainly Dr. Schwartz's conclusion, and that conclusion fits the extremely spare data available here.

The Court finds that Wyeth has easily established that this echocardiogram was conducted in a technically inadequate manner and no reasonable medical conclusions regarding the presence and severity of Ortiz-Gwitt's claimed mitral regurgitation can be drawn from it.

VV. REBECCA OWENS

Owens relies on a May 22, 2002 echocardiogram performed by Cardiac Consultants of Chicago, Ltd and a report by Dr. Richard Levinsky. Dr. Levinsky found that Owens had MMR using CAS criteria -- RJA/LAA = 20%.

The May 22, 2002 echocardiogram was reviewed by three (3) experts: Dr. Schwartz, Dr. Millman and Dr. H. Cohen. Both Drs. Millman and Schwartz concluded that this echocardiogram was not conducted in a technically adequate manner such that reliable medical conclusions regarding the presence and severity of valvular regurgitation could be drawn from it. Dr. Millman found that "[t]he study is of extremely poor quality and especially in the apical view, the left atrium is obscured. The color [D]oppler images are dreadful. No regurgitation of any valve can be seen." Dr. Schwartz echoed these findings: "This echocardiogram is technically inadequate. The 2-D grayscale gain is so high that the left atrial is obliterated on apical view, washing out color [D]oppler data."

In any case, neither Dr. Millman nor Dr. Schwartz saw any evidence of mitral regurgitation. Dr. Schwartz best summed up the value of this echocardiogram study: "[T]he image quality is simply horrendous in apical view, making the image uninterpretable. The sonographer traced a brief, single-frame flash of laminar flow in the early stage of systole which clearly represents back flow. There is no true holosystolic mitral regurgitation."

Dr. H. Cohen came to the incredible conclusion that "[t]he echocardiogram settings were appropriate and the study was of diagnostic quality." During the hearing, Dr. H. Cohen conceded that the gain was high and the 20% is right at the borderline of MMR. Since we have no RJA or LAA measurements, one can only guess how Dr. H. Cohen arrived at them.

Q. Now, if we can go to Rebecca Owens. Doctor, in this -- with regard to Rebecca Owens, you have said again as with all multiple views all greater than 20 percent but you cited only two frames.

Do you recall even the initial screening echo what the percentage obtained purportedly from measuring the RJA/LAA in presuming there was in fact a regurgitant jet what that percentage yielded?

A. Do I remember?

Q. Do you not have it there?

A. I don't have it.

Q. I'll tell you it was 20 percent. Can we agree that's right on the cusp?

A. If it says 20 percent then that's [] the number he got when he made the division.

Q. Here again when you rendered your certification report the most you did was simply eyeball the tape?

A. That's correct.

Q. I'm going to point you to the two frame that is you at least one of the frames that you suggested to the Court and that would be and will be introduced as defendant's Exhibit D 4540, and that's OR.1.

All right, sir, as you've looked at that particular frame and that's the frame you cited in your certificate, is it not?

A. 1, 19, 24, 06. Yes.

Q. Can you comment on the level of the 2D gain specifically as it applies to the general area of the atrium?

A. 2D gain is high.

Q. Is there any way on that film to reasonably assess presuming that that is even an appropriate frame for the purposes ever attempting to assess true left atrial area in that it is in early systole, is it not?

A. It's in earlier systole.

Q. Would that be an appropriate frame to try to assess left atrial area based upon just the cycle that it's an early systole?

A. As I've told you before, we measure the left atrial, we did the left atrial planimetry where we saw the mitral regurgitation.

> Q. And so before you saw the mitral regurgitation was in early systole, if that's where you saw it, that's where you would have planimetried the left atrial area?
> A. As I said, I don't know where the planimetry was done, but if you look at the area of the mitral regurgitation here, that's certainly more than 20 percent of what the left atrium could possibly be no matter how increased the 2D is.
> Q. All right.
> A. Because I can see the edge of the left ventricle and the left atrium couldn't possibly be big enough for this to not be 20 percent.
> Q. All right. In your judgment, can one medically, reasonably assess the true left atrial area of this plaintiff, Ms. Owens, based upon this frame?
> A. No, I wouldn't use this frame to planimetry the left atrium.
> What was the percent we gave?
> Q. 20 percent right on the cusp?
> A. Obviously, it wasn't done from this frame.
> Q. Because in your judgment this is excessive 20 percent?
> A. This is more than 20 percent, yeah.

The Court has reviewed the entire cross-examination of Dr. H. Cohen, much of which is set forth above, and finds his testimony is a "net opinion" and thus entitled to little or no weight. *See Buckelew v. Grossbard*, 87 N.J. 512 (1981). In short, Wyeth has easily satisfied its burden and has shown that this echocardiogram is so infirm that no reliable medical opinions can be drawn from it. Accordingly, no reasonable medical conclusion could be drawn that Owens has MMR based on a review of this echocardiogram.

WW. KENNETH D. PATRICK

Patrick relies on a May 29, 2002 echocardiogram performed by Associates in Cardiology, Ltd. and a May 30, 2002 report by Dr. Roger A. Billhardt. Dr. Billhardt found Patrick had MMR using CAS criteria -- RJA/LAA = 23%.

The May 29, 2002 echocardiogram was reviewed by three (3) experts: Dr. Schwartz, Dr. Millman and Dr. Billhardt. All three (3) physicians concluded that

the echocardiogram was technically adequate. In fact, Dr. Schwartz concluded that it was "of very good quality."

Both Drs. Millman and Schwartz concluded that there was no mitral regurgitation demonstrated. Rather, according to Dr. Millman, "[t]he only 'mitral regurgitant' signal demonstrated showed only the closing 'puff' of physiologic mitral retrograde flow from the actual physical closure of the mitral leaflets. This is at the very onset of systole, and is not holosystolic. It is a normal phenomenon." Dr. Schwartz concurred.

Dr. Billhardt disagreed and reported a RJA/LAA of 23% based on a RJA of 2.83 cm² and a LAA of 12.05 cm². Dr. Billhardt conceded that Patrick was a "very large patient," 6'1" - 320 pounds, and had a mildly dilated left atrium. Moreover, the measurement was made in early systole with the cursor right on top of the QRS complex.[27] The phenomenon observed was not holosystolic.

---

[27] Dr. Billhardt's cross-examination is set out below.

> Q. Okay. Let's go to Patrick.
> You assessed Mr. Patrick with moderate mitral regurgitation, based on your assessment, correct?
> A. That's correct.
> MR. GHOLSON: All right. Let's go to PR.1, please.
> MS. REED: That is Defense Exhibit 4362.
> MR. GHOLSON: I'm sorry. That is what I had on my form, so my apologies.
> MS. REED: Sorry.
> MR. D'ANGELO: No. That's okay.
> BY MR. GHOLSON:
> Q. The measurements you came up with were 2.83 and 12.05, Doctor. Is this the image that you relied on to arrive at those measurements?
> A. It appears to be, yes.
> Q. And, once again, this is -- coincidentally, the cursor happens to be right on top of the arrow. By the electrocardiogram, this is very early in systole, is it not?
> A. It was early in systole, yes.
> Q. And, in fact, the cursor is right on top of the QRS complex, isn't it?
> A. It is just at the end of it in the portion of the S wave.
> Q. All right, sir. Now, I want to take the cursor up here and try to indicate, is this the mitral annulus right here that I am showing?
> A. This is not the best of pictures, but I would think that that is the mitral annulus on the aortic side, yes.
> Q. All right, sir. And, likewise, here?
> A. I think it is probably a little superior to that, getting up toward the red.
> Q. All right. Here (indicating)?
> A. Yes.
> Q. Okay. And so is it your testimony that the valve leaflets would follow the planimetry that is indicated on this image?
> A. We don't really see the valve leaflet -- the anterior leaflet very well at all here, but I think the posterior leaflet does follow it. And at least the portion that

The Court finds that Wyeth has established that no medically reasonable conclusion that Patrick has MMR could be drawn from this echocardiogram. The M-mode and apical measurements of Patrick's left atrium show it to be dilated. Thus, one would expect this rather large man to have a left atrial area well above the 14.2 cm^2 mean reported by Weyman. Even if one were to assume that a LAA of 14.2 cm^2 was medically reasonable Patrick's ratio would fall below 20%. Beyond this, the LAA was measured at the earliest frame in systole, which has the effect of making the measurement considerably smaller than in mid to late systole when it should have been measured. Finally, the phenomenon reported by Dr. Billhardt was not holosystolic. This evidence strongly supports Dr. Millman's judgment that backwash or closing volume was what Dr. Billhardt observed.

XX. MICHELE R. PINTO

Pinto relies on a May 11, 2002 echocardiogram performed by Associates in Cardiology, Ltd. and a May 14, 2002 report by Dr. Neal Ruggie. Dr. Ruggie initially found that Pinto had MMR and SAR using CAS criteria -- RJA/LAA = 22%; JH/LVOT = 45%. The MMR claim was withdrawn after Dr. Ruggie reported that "[t]he measurements were in error."

---

is in the middle of the jet planimetered area follows the anterior leaflet. The rest of the leaflet, I am hard pressed to see on this one view.

Q. Doctor, I am indicating with the cursor some white here. Would that be consistent with part of the mitral leaflet?

A. I would have to say, I can't see that white. I see white coming up to where the planimeter line is, and then after that, I think you have to move the cursor for me to be able to see whether there is or there isn't.

There is a little dot of white there with black all around it that could potentially be the anterior leaflet or the anterior leaflet may be farther out toward the left ventricular side.

Q. And you just simply can't say, based on this particular image, can you, Doctor?

A. I can't say, no.

Q. And if this were the leaflet, if it extended across here, then some of this tracing would actually be in the left ventricle, wouldn't it, Doctor?

A. If that were the case, yes, it would be.

Q. In your assessment of this patient -- rather, this plaintiff, also took into account that the left atrium was dilated? And I think your assessment was moderately dilated, correct?

A. By the M-mode measurement, moderately dilated, yes.

Q. All right, sir. And if the left atrium were moderately dilated, would you expect that left atrial area, as reflected on the planimetry, to actually be greater than the norm?

A. Yes.

The May 11, 2002 echocardiogram was reviewed by three (3) experts: Dr. Schwartz, Dr. Millman and Dr. Ruggie. All three (3) physicians found the echocardiogram to be technically adequate.

All three (3) physicians reported that Pinto has no aortic regurgitation, let alone SAR, when the echocardiogram is examined in the PLAX view. Dr. Millman simply states that "[t]here is no regurgitation in the pslax (PLAX) view." Dr. Schwartz reached the same conclusion with these observations:

> There is no significant aortic insufficiency on this echocardiogram. There is absolutely no aortic insufficiency seen in the parasternal long axis view. Any diagnosis of this plaintiff as having severe aortic insufficiency is a gross overestimation and is clearly unreliable.

Dr. Ruggie simply checks "No" to the question: "[D]oes the parasternal long axis view show FDA positive aortic regurgitation (JH/LVOT ≥ 10%) by color flow Doppler?"

Dr. Ruggie does find a borderline MMAR in the apical long axis view (apical 3 chamber view) with a JH/LVOT equal to 25% but it is clear that he is relying on an apical 5 chamber view which is not a permitted view.

Dr. Schwartz addressed this and other issues in his reply certification.

> Mild or greater aortic insufficiency is not seen on this study. Good quality images of the PLAX view are available, and those images reveal no significant aortic insufficiency; on this basis alone, the report of severe aortic insufficiency is absurd. The CAS requires that if the parasternal long-axis view is available, aortic insufficiency must be measured in that view. The PLAX view does not demonstrate mild aortic insufficiency, which Dr. Ruggie concedes.
>
> In his affidavit, Dr. Ruggie refers to 0:41:16 as supporting his diagnosis of aortic insufficiency. Dr. Ruggie contends that this time stamp refers to the apical long axis view, but it instead refers to the apical 5-chamber view. The apical 5-chamber view is not an

> acceptable view to assess the severity of aortic insufficiency due to the inherent tendency to [] overestimate the JH/LVOT ratio.

The Court finds that Wyeth has established that no reasonable medical conclusion that Pinto had MAR, let alone MMAR or SAR, can be drawn from a review of this echocardiogram. With the claimed serious aortic regurgitation and the relatively good quality echocardiogram, it is inconceivable that some indication of aortic regurgitation would not be present in the PLAX view. If the PLAX view is available, it must be used. Obviously, Dr. Ruggie did not rely on it in this case.

YY. SHEILA J. POLLOCK

Pollock relies on an April 30, 2002 echocardiogram and a report by Dr. Curtis S. Burnett. Dr. Burnett found that Pollock had MAR using CAS criteria -- JH/LVOT = 22-25%. The technician's worksheet reveals three (3) JH/LVOT measurements (.41 cm/1.9 cm = 22%; .49 cm/2.18 cm = 22%; .53 cm/2.15 cm = 25%).

The April 30, 2002 echocardiogram was reviewed by three (3) experts: Dr. Schwartz, Dr. Millman and Dr. Charash. All three (3) physicians found the echocardiogram to be technically adequate.

Both Drs. Millman and Charash concluded that Pollock has MAR. Dr. Millman found a JH of .45 cm and a LVOT of 2.2 cm. Dr. Charash measured a JH of .41 cm and a LVOT of 1.9 cm. These measurements, if medically reasonable, plainly support a MAR claim.

Dr. Schwartz makes no measurements in this case. Instead, he concludes that MAR is not present because there is no indication that the phenomenon is holodiastolic. In his reply certification, he states:

> It is not medically reasonable to diagnose the patient with any degree of aortic regurgitation. There is a single frame of subvalvular signal confined in all cases to the end of systole/beginning of diastole (conincident with the end of the T-wave on the EKG tracing). This is consistent with closing volume (a normal phenomenon) and not pathological regurgitant flow. There is no true aortic insufficiency.

On cross-examination, he thought his conclusion that the phenomenon might be closing volume might be in error, but he held to his conclusion that it was not holodiastolic.

Dr. Charash agreed that the echocardiogram did not demonstrate that the phenomenon he characterized as MAR was holodiastolic. The Court has reviewed the echocardiogram and the purported jet does not appear to be holodiastolic; it lasts for only one or two frames.

Nevertheless, the Court concludes that Wyeth has failed to establish that no reasonable medical conclusion that Pollock has MAR could be drawn from this echocardiogram. If this Court was the ultimate factfinder here it might well have found that Pollock does not have MAR. But Dr. Millman made a finding close in line with Dr. Charash, and Dr. Schwartz never challenged the planimetry. Wyeth also never challenged Dr. Millman's conclusions. While it successfully obtained a concession from Dr. Charash that the jet here did not appear to be holodiastolic, Dr. Charash explained that in any individual echocardiogram there might not be an indication on the echocardiogram, even if the jet actually was holodiastolic.

ZZ. ASIA PURVIS

Purvis relies on a May 25, 2002 echocardiogram performed by Cardiac Consultants of Chicago, Ltd. and a report by Dr. Richard Levinsky. Dr. Levinsky found that Purvis had MMR using CAS criteria -- RJA/LAA = 25%.

The May 25, 2002 report was reviewed by three (3) experts: Dr. Marino, Dr. Millman and Dr. H. Cohen. Both Drs. Millman and Marino found that this echocardiogram was not conducted in a technically adequate manner such that reliable medical conclusions regarding the presence and severity of valvular regurgitation could be drawn from it. Dr. Millman determined that:

> The echo gain is set very high precluding adequate visualization of the left atrium. [T]he Nyquist limit of 0.74 cm/sec and the variance map are good, but the very high gain settings of the color [D]oppler preclude any meaningful analysis.

Dr. Marino concurred.

> The study was not technically adequate, and a conclusion that Ms. Purvis is FDA positive can not [sic] be reliably drawn from this echocardiogram. The black and white gain setting was very high so that there was an improper signal to noise ratio. A high black and white gain setting can create significant background noise making it impossible to accurately measure the size of the left atrium. The sonographer did not make RJA/LAA measurements on the study, making it impossible to determine whether the Singh criteria were followed.

Dr. H. Cohen disagreed, claiming that "[t]he echocardiogram settings were appropriate and the study was of diagnostic quality." However, on cross-examination, Dr. H. Cohen conceded that the 2-D gain and color gain were "high."

> Q. Now, with this particular one, do you have any comment on the 2D gain?
> A. Again, the 2D gain is high.
> Q. By the same token, the color gain as well is extremely high as well, is it not?

> A. The color gain is high also.
> Q. And both of those two elements, if too high, create artifact, do they not?
> A. Well, they don't cause blood to flow in the opposite direction, they can cause -- you can see tissue moving away or toward the transducer.

Review of this echocardiogram belies the conclusion "that the echocardiogram settings were appropriate." They plainly were not. This coupled with Dr. H. Cohen's inability to tell us where the measurements satisfying the CAS criteria may be seen and what they are doom Purvis' claim. In this case, Wyeth easily satisfies its burden to show that this echocardiogram is so infirm that no reasonable medical conclusion regarding the presence and severity of valvular regurgitation could be drawn from it.

AAA. MAUREEN J. REAGAN

Reagan relies on a June 19, 2002 echocardiogram performed by Cardiac Consultants of Chicago, Ltd. and a report by Dr. Richard Levinsky. Dr. Levinsky found that Reagan had MMR and trace aortic regurgitation by CAS criteria -- RJA/LAA = 25%; JH/LVOT = 9%. Only the MMR claim is pursued here.

The June 19, 2002 echocardiogram was reviewed by three (3) experts: Dr. Marino, Dr. Millman and Dr. H. Cohen. Both Drs. Millman and Marino concluded that this echocardiogram was not conducted in a technically adequate manner such that reliable medical conclusions regarding the presence and severity of valvular regurgitation could be drawn from it. Dr. Millman found that "[t]he study is of poor quality with high 2-[D] echo gain obscuring the left atrium in the apical views. The color gain is set too high, and no meaningful analysis can demonstrate significant aortic or mitral regurgitation." Dr. Marino concurred, stating:

> The study was technically inadequate, and a conclusion that Ms. Reagan has an FDA Positive condition cannot be reliably drawn from this echocardiogram. The black and white gain was set very high, so that there is an improper signal to noise ratio. A high black and white gain setting can create significant background noise making it impossible to accurately measure the size of the LA. Furthermore, no RJA/LAA measurements were made on the study.

Dr. H. Cohen disagreed, again finding that "[t]he echocardiogram settings were appropriate and the study was of diagnostic quality." The echocardiogram plainly belies that claim.

The Court agrees with Dr. Marino's comments not only with respect to the technical quality, but also with respect to whether a reasonable medical opinion that Reagan has MMR could be premised on this echocardiogram.

> As I stated in my original report, the 2-D gain on this study is set very high, making it impossible to reliably measure the LA. Therefore, it is also impossible to reliably calculate the RJA/LAA ratio. Nevertheless, even with this technical limitation, there is no true mitral regurgitation on this study.
>
> Dr. Cohen refers to time markers 19:54:26; 20:03:20; 20:05:23, and 22:01:21, as showing moderate mitral regurgitation. There are no measurements on these frames, and none of them demonstrate the presence of any FDA Positive mitral regurgitation.
>
> In addition, Dr. Cohen asserts that spectral Doppler views confirm the presence of moderate mitral regurgitation. However, spectral Doppler shows no high velocities characteristic of FDA Positive mitral regurgitation.
>
> In summary, due to the high 2-D gain setting, this is a technically inadequate study, such that the degree of regurgitation, if any, cannot be reliably assessed. Nevertheless, even with this technical limitation, no true mitral regurgitation is visualized on this study.

The Court finds that the echocardiogram was not conducted in a technically adequate manner such that reliable medical conclusions regarding the presence and severity of valvular regurgitation could be drawn from it. Moreover, none of Dr. H. Cohen's reported frames support his claim that Reagan has MMR. In short, Wyeth has established that this echocardiogram is technically infirm and no reasonable medical conclusions could be drawn from it.

BBB. MILDRED RIVERA

Rivera relies on a June 29, 2002 echocardiogram report by Dr. James Colasacco. Dr. Colasacco found Rivera had MMR using CAS criteria -- RJA/LAA = 35%.

The echocardiogram was reviewed by three (3) experts: Dr. Marino, Dr. Millman and Dr. Colasacco. All three (3) physicians found the echocardiogram to be technically adequate.

Both Drs. Millman and Marino concluded that the echocardiogram did not demonstrate MMR. Rather, according to Dr. Millman, "[t]here is no true mitral regurgitation demonstrated. Each freeze frame calculation represents the closing 'puff' of the mitral valve at the onset of systole. [T]here is no holosystolic signal." Dr. Marino, too, found no holosystolic jet. In addition, he observed "[t]he still frames from which the purported regurgitation was measured are not representative of what is observed when the echocardiogram is in motion. The purported regurgitation was overtraced and included pre-valvular acceleration, black signal and areas of low-velocity and laminar blue flow."

Dr. Colasacco disagreed. He reported MMR using CAS criteria of RJA/LAA = 24% (RJA of 3.34 cm^2; LAA of 13.97 cm^2) and RJA/LAA = 25% (RJA of 4.09 cm^2; LAA of 16.07 cm^2). Dr. Colasacco was challenged on these measurements and during direct and cross-examination conceded that the measurements were made in the first frame of systole, that the LAA was traced in the same frame as the RJA and that frame was not well visualized.

Dr. Marino's criticisms of Dr. Colasacco's approach are contained in his reply affidavit. Dr. Marino insisted that the claimed mitral jet is not holodiastolic, and that the RJAs, in any case, were overtraced.

> As I indicated in my original report, this echocardiogram does not show any true holosystolic mitral regurgitation. Instead, the traced purported regurgitation consists of prevalvular acceleration, laminar flow, and black signal.
>
> Dr. Colasacco asserts that he conducted planimetry at times markers 9:53:05 and 9:55:14. However, the tracings on the study at these points include both laminar blue flow and black signal, rather than true aliased flow.

> There is perhaps a speck of orange flow, which might either be aliasing flow or simply color artifact, but there is certainly no mosaic color, and furthermore this orange speck represents only a tiny portion of the area traced as the RJA.
>
> Dr. Colasacco asserts that spectral confirms the presence of moderate mitral regurgitation. However, I see no CW Doppler confirmation of mitral regurgitation on this study. The PW Doppler views available do not show aliasing velocities.
>
> In summary, no FDA Positive mitral regurgitation is present on this study. The flow selected for measurement is not holosystolic and emanates from above the mitral valve and is therefore not true mitral regurgitation.

The Court finds that its review of the echocardiogram supports each of Dr. Marino's points. But, in the Court's view, the main criticism here is that this jet is not holodiastolic. Rather, it is a fleeting phenomenon seen at the outset of systole. Wyeth has satisfied its burden of establishing that no reasonable medical conclusion that Rivera has MMR can be based on this echocardiogram.

CCC. ANGELA RIVERS

Rivers relies on a January 22, 2002 echocardiogram report by Dr. James Colasacco. Dr. Colasacco found the Rivers had MMR using CAS criteria -- RJA/LAA = 29%.

The echocardiogram was reviewed by three (3) experts: Dr. Marino, Dr. Millman and Dr. Colasacco. Both Drs. Millman and Marino concluded that this echocardiogram was not conducted in a technically adequate manner such that reliable medical conclusions regarding the presence and severity of valvular regurgitation could be drawn from it. Dr. Millman found that "[t]he color Doppler gain settings are too high, introducing significant noise into the study. In addition, the Nyquist limit is let (sic) [set] at a suboptimal range, 41 cm/sec. It would have been better set at approximately 60 cm/sec." Dr. Marino agreed. "This study was unreliable for assessing the level of regurgitation, and is technically inadequate. The Nyquist was set too low at 41 cm/sec. Setting the Nyquist this low can

produce artifacts that can be misinterpreted as regurgitation, and can exaggerate the degree of any regurgitation that may be present."

Dr. Colasacco did not even mention the extremely low Nyquist limit set here. In his initial report, he noted that this was a "[g]ood quality echocardiogram."

Both Drs. Millman and Marino also determined that a review of this inadequate echocardiogram demonstrates the absence of MMR. Drs. Millman and Marino noted the "jet" was not holosystolic and probably amounted to nothing more than closing volume. Dr. Marino also criticized Dr. Colasacco's planimetry and analysis.

> As I stated in my original report, the Nyquist level is set inappropriately low at 41 cm/sec throughout this study, making it impossible to reliably assess the presence or severity of mitral regurgitation, if any. A low Nyquist setting can exaggerate the severity of regurgitation. For that reason, a panel of experts convened by the American Society of Echocardiography in July 2003 stated that the Nyquist limit should be set above 50 to approximately evaluate the level of regurgitation. Specifically, they stated that:
>
> > The size of the regurgitant jet by color [D]oppler and its temporal resolution, however are significantly affected by transducer frequency and instrument settings such as gain, output power, Nyquist limit, size and depth of the image sector…. Standard technique is to use a Nyquist limit (aliasing velocity) of 50-60 cm/sec.… Jet area is inversely proportional to PRF, and substantial error can be introduced with use of higher or lower settings than the nominal settings to which echocardiographers have become accustomed. [Citation omitted.]
>
> Because the Nyquist limit is set at 41 cm/sec on this study, the echocardiogram is technically inadequate and

> it is impossible [to] reliably assess the presence or severity of mitral regurgitation, if any, based on this study.
>
> Although I would not make tracings on a technically inadequate study such as this one, I can state nonetheless that the tracings of MR on the study are also inappropriately conducted. Black signal is included in the tracing, and it is unclear whether there is in fact any real aliasing flow, due to the Nyquist setting.
>
> Dr. Colasacco states that CW/PW Doppler shows FDA Positive MR is present. On page 20 of the DICOM, the signal of the CW Doppler in systole is so faint as to be essentially invisible at velocities beyond approximately 1.4 m/sec. Even if there is some very faint signal on the spectral Doppler, there is no high velocity signal at all. Therefore, I would certainly not rely on this spectral Doppler image for confirmation of any significant mitral regurgitation. This is true of all other spectral Doppler images on the study as well.

Review of the echocardiogram shows all these criticisms have merit.

The Court finds that Wyeth easily satisfied its burden of establishing that no reasonable medical conclusion that Rivers has MMR could be drawn from this echocardiogram. As noted, the echocardiogram is technically inadequate and the few conclusions that can be drawn from it exclude MMR as a reasonable medical conclusion.

DDD. SHEILA L. ROUFF

Rouff relies on an August 26, 2002 echocardiogram report by Dr. James Colasacco. Dr. Colasacco found that Rouff had MMR and MMAR using CAS criteria -- RJA/LAA = 35%; JH/LVOT = 33%. The aortic regurgitation claim was withdrawn when Dr. Colasacco conceded that the echocardiogram did not support it. Dr. Colasacco noted that this was a "[g]ood quality echocardiogram."

The echocardiogram was reviewed by three (3) experts: Dr. Marino, Dr. Sherrid and Dr. Colasacco. Both Drs. Sherrid and Marino found this

echocardiogram was not conducted in a technically adequate manner such that reliable medical conclusions regarding the presence and severity of valvular regurgitation could be drawn from it. Dr. Sherrid cryptically noted "[g]ain is too high." Dr. Marino noted that "[t]his is a poor quality study. The color Doppler gain settings are too high, making it impossible to reliably assess the degree of any regurgitation present on the study." Dr. Colasacco admitted that the gain was high, but claimed he could interpret the echocardiogram.

> Q. Doctor, the first criticism of this echocardiogram is there was excessive gain.
>
> Can you tell us whether or not you agree with whether or not there's excessive gain?
>
> A. I think this is more gain than I would want for an optimal study but I think it's adequate for this particular image.
>
> MR. NAPOLI: Is it interpretable?
>
> A. And I considered it interpretable.

While judging the echocardiogram uninterpretable, both Drs. Marino and Sherrid found there was enough information there to exclude MMR. Dr. Sherrid noted only occasional "closing" volume. Dr. Marino noted other technical problems.

> The left atrial walls are not well visualized and the LAA was arbitrarily drawn. The RJA was overtraced and included pure laminar blue flow and black signal, and also included signal on the left ventricle. The purported regurgitation measured by the sonographer appeared only in frozen isolated frames and was not representative of what is seen in real time, where no mitral regurgitation is seen.

Dr. Colasacco traced a RJA of 2.37 cm^2 and a LAA of 10.78 cm^2, giving a percentage of 22%. Dr. Marino, however, testified that in addition to the severe technical limitations the purported jet was not holosystolic; and he agreed with Dr. Sherrid that it was probably a closing phenomenon. Moreover, the RJA was overtraced -- including laminar flow and black signal (no moving red blood cells).

Dr. Marino noted:

> As I indicated in my original affidavit, the color Doppler gain is too high on this study, as evidenced by sparkling in the tissues (see, for example, page 102 of the DICOM). As a result, it is impossible to reliably assess the actual size of any regurgitant jets. Nevertheless, it is possible to see that there is no real aliasing high velocity flow.
>
> Although Dr. Colasacco asserts that he conducted planimetry at time marker 10:59:59 (which appears to correlate with the measurements at Page 64 of the DICOM), there is no apparent mosaic, aliasing flow in this image. The overwhelming portion of the area traced is laminar blow (sic) [blood] flow, along with some black signal.

The Court finds that Wyeth has established that the echocardiogram was not conducted in a technically adequate manner such that reliable medical conclusions could be drawn from it. To the extent it can be analyzed at all, it demonstrates that no reasonable medical conclusion that Rouff has MMR could be drawn from this echocardiogram.

EEE. KATHY E. RYAN

Ryan relies on a May 31, 2002 echocardiogram and report by Dr. Curtis S. Burnett. Dr. Burnett found Ryan had mild to MMR and MAR using CAS criteria -- RJA/LAA = 15%; JH/LVOT = 10-24%. The worksheet provided to the Court is not readable. The mitral valve claim was withdrawn at the hearing when Dr. Burnett conceded that no MMR was apparent. Dr. Burnett noted that this was a "[t]echnically difficult study."

The May 31, 2002 echocardiogram was reviewed by three (3) experts: Dr. Marino, Dr. Sherrid and Dr. Burnett. Dr. Marino found that this echocardiogram was not conducted in a technically adequate manner such that reliable medical conclusions regarding the presence and severity of valvular regurgitation could be drawn from it. "The quality of this study is suboptimal and the study is barely interpretable. The black and white gain setting is not optimal, making it difficult to visualize structures. The Nyquist limit is set very low (48) in apical views. A low Nyquist setting can produce artifacts that can be misinterpreted as regurgitation and can exaggerate the degree of any regurgitation that may be present." Dr.

Burnett agreed that the study quality was marginal but "[i]t was the best we could do." Dr. Sherrid simply noted the technical quality was adequate, and he was not questioned on it.

Dr. Burnett based his determination that Ryan had MAR on the apical short axis (apical 5 chamber) view. Though he believed that MAR could be seen in the PLAX view, he could not isolate it at the hearing although the echocardiogram was moved to the location he referenced. As he candidly admitted, he spent most of his time examining the apical 5 chamber view which is not an approved view.[28]

---

[28] Dr. Burnett's testimony on cross-examination and on re-direct is set out below.

> Q. All right, Doctor then let's move to your testimony on direct about this study. I made a notation Doctor that you again indicated that the parasternal long axis view was available on this echocardiogram but that you could not visualize FDA-positive aortic insufficiency in that view;
> correct?
> MR. NAPOLI: Objection to the form of the question. That's not what he said.
> JUDGE WALSH: Oh, we'll let him answer. He's the expert.
> A. Now, this is Cathy Ryan?
> Q. Yes, sir.
> A. Where did you see that I said that I couldn't get an adequate measurement?
> Q. Doctor, that's what my note -- I'm sorry that's what my notes reflect. If I'm wrong, you tell me I'm wrong and testify correctly so we can move forward. The record will speak for itself on what you said.
> A. Right. Well, I recall my saying that it was sub-optimal and that it was supported by the short axis that the parasternal short axis definitely showed mild aortic insufficiency and then that was supported by the five chamber view. And you know I do have an area of the tape that I looked at last night on this patient but you don't have that.
> Q. Dr. Burnett, would you agree with me that if one were to look at the PLAX views alone, it would not be medically reasonable to conclude that this patient has mild aortic insufficiency looking at those views and those views alone?
> MR. NAPOLI: Objection to the form of the question.
> JUDGE WALSH: Overruled.
> A. Just a second. Let me -- do I have pictures --
> Q. Yes, sir, Doctor. In fact you didn't make any time markers on your affidavit so we would presume I guess that you would rely upon the tracings made by your sonographer?
> MR. NAPOLI: Objection. Is he withdrawing the last question and asking a new one, or are both questions still pending?
> MR. WHEELER: I understood the witness to request clarification, and I'm attempting to do that. I still want an answer to my original question.
> JUDGE WALSH: Why don't you just rephrase the question? He doesn't remember.
> Q. Dr. Burnett, in the interest of simplicity, my question stands.
> Do you agree that in (sic) [if] one were to look at the PLAX view and that view alone, it would not be medically reasonable to diagnose this patient was (sic) [with] FDA-positive aortic insufficiency?
> MR. NAPOLI: Objection to the form of the question.
> JUDGE WALSH: Overruled.

A. You know, but you're asking me to disregard the rest of the study for the purpose of, you know, this question regarding the sub-optimal quality and that parasternal view, and I'm just trying --
JUDGE WALSH: I don't think -- he may be asking that. Here's the point, Doctor. And maybe I can clarify it, because I'm the one who has to make the decision here. The PLAX view has got to, if it's available, show that the person is FDA-positive here with mild aortic insufficiency. If you have confirmatory evidence, you can bring that forward as well. But the PLAX view if available has to show aortic insufficiency that is at least mild. If you can -- if you believe you have frames that show that or you can see it in the dynamic, you can also refer to apical views or continuous wave [D]oppler as confirmatory. I hope that helps you.
A. Well, I'll say yes then.
Q. All right, Doctor, let's look at a couple of the PLAX view images then if we might. The first one I believe is one that's identified by your sonographer, again there's no time stamps on your report at time reference your Honor 19:10:18. This is Exhibit D-4501 and it's RK-5.

Dr. Burnett, isn't it true in this image, your sonographer mistakenly measured the area of an ostensible aortic jet as opposed to the height?
A. I'm not sure what she was trying to do there. Maybe she was trying to show me that that's what she thought the jet was. Yeah, but I consider that artifact.
Q. You would agree that would not be a proper method for an ultrasonographer technician to measure; would it?
A. Correct.
Q. Let's look at the next one, and I represent to you, Doctor, [] these are the only two tracings I could find on the study the next one is at time stamp 19:33:21. It's Exhibit D-4502 and it's RK-6. Again, Doctor, isn't that an effort by some sonographer in your lab to measure the area of an ostensible aortic jet?
A. I think she's trying to show me what she thought was a puff of insufficiency and I think it's totally artifactual.
Q. Well, the question would then stand the judge asked you a question a moment ago --
JUDGE WALSH: Hold it. You said the puff in other words the color here is totally artifactual.
THE WITNESS: Correct. The big puff thing that she outlined was, but there is a smaller sort of jet just proximal to that bloom that probably represents the aortic insufficiency again although it's sub-optimal study and we had to go to the other views of the five chamber view.
JUDGE WALSH: If this is a jet, Doctor, it certainly wouldn't satisfy the 10 percent criteria JH/LVOT once you take out the artifact?
THE WITNESS: Which wouldn't?
JUDGE WALSH: The width of a jet you identify in this picture.
THE WITNESS: Depends on where the edges are. I mean I've had extreme difficulty in finding the edges but when you watch it over and over, then -- and then -- and reconstruct it in your head and then draw it, and then draw the jet height, I mean I mean you might be able to come up with it.

I didn't re-measure that because I thought it was sub optimal to measure but whether or not you can say that there was sufficient appearance of insufficiency, there to say that's FDA-positive AI is -- you know, kind of the crux of the problem.
JUDGE WALSH: Well, are you saying that there were no measurements taken here in the PLAX view?
THE WITNESS: I'm seeing -- well, I'm saying that neither one of these are accurate measurements.
JUDGE WALSH: Okay.

THE WITNESS: And these are -- these specific measurements are inadequate in and of themselves.
Q. Dr. Burnett, can you identify [] any frame reference where a sonographer made any effort to measure a jet high (sic) [height] in the PLAX view on this study?
A. Well, I can't -- I have a card here. I looked at PLAX view 0:17:40.00.
Q. Is that where you made a measurement?
A. This is where I made a measurement.
JUDGE WALSH: Why don't we get that down in slow motion again what is it.
THE WITNESS: It's 0 -- I'm not sure. I just have this on my card from last night, PLAX view 0:17:40.00
Q. Dr. Burnett, while the technician is looking at that image let me ask you a couple of other questions about this study in the interest of time. You actually put in your report that the 2D gain on this study made it a technically-limited study; correct?
A. Correct.
Q. So, you would agree with me would you not that the technical limitations of this study make it very different for one to interpret the PLAX view?
A. Correct.
Q. And once we find the image that you referenced a moment ago, my question will still stand, Doctor and that is whether or not any sonographer in your office made any effort to trace a jet height in the PLAX view that we can visualize on this study?
JUDGE WALSH: I'm going to let him measure the jet.
MR. NAPOLI: Is this from a freeze frame or a still shot?
THE TECHNICIAN: That appears to be a freeze frame because they've traced something?
Q. Dr. Burnett, are we now on the appropriate frame that you referenced?
MR. NAPOLI: 00.
JUDGE WALSH: Well, it appears to say 42.
THE TECHNICIAN: It's a 0.
A. You know, it could be. It looks like we're seeing a jet there. That's like, you know, consistent with -- what I can later can see in the five chamber.
Q. Sorry, Doctor. Dr. Burnett, we now have I believe the image you referenced a moment ago. We'll capture that and make it an exhibit.
MR. NAPOLI: Is that a 02 or a 01?
JUDGE WALSH: Mr. Napoli, believe me, whoever makes these numbers, zeros routinely look like twos.
Q. Doctor, this is the imagine you referenced a moment ago; correct?
A. Yep.
Q. Do you agree with me --
A. Yeah, I think so, what I see on the screen supports, yes, okay.
Q. Do you agree with me that your sonographer was in the process again of measuring the area of this image?
A. Well, I'm not sure what she was doing with that. I mean, probably stands from the frustration of trying to get a good image. I'm not really able to tell you what that was about.
Q. Doctor, I know we don't have the technical capacity for you to point to an image where you think there is as a regurgitant jet that you think is measurable in height version by calipers, but can you tell us or can you direct it
to where you believe a jet is present here that would be FDA-positive regurgitation?
A. Well, the sort of white-ish, you know, alias signal that looks linear, that initiates at the valve closure site, the cursor is sort of towards the end of the mitral valve leaflet. That looks like an attempt at freezing. What was difficult

to see in the cine form, attempt at freezing that jet. So, I would say that looks like it represents what I later could see in the five chamber view.
MR. WHEELER: Your Honor, this will be Exhibit D-4575.
Q. Is it your testimony, Dr. Burnett, that this image is one that can be reproduced in a real-time cine loop?
A. I would think so, yes. I mean --
Q. Do you know?
A. It's not a great image. We've got short axis that you shows it. Is it -- you're not buying a parasternal short axis that does show that.
Q. Doctor, it's not a question of what I buy. It's a question of what the court accepts. And my question is whether or not there's a PLAX view --
MR. NAPOLI: Objection, your Honor.
Q. My question is whether or not this can be reproduced real-time in a PLAX view, this very image, whatever it may be, can it be reproduced real-time in a PLAX view Doctor, do you know?
MR. NAPOLI: Objection to the quolloquy at the beginning of the question of what the court allows.
JUDGE WALSH: Overruled.
A. I'll say yes, I think with a cine loop, you'd be able to see that. Otherwise I wouldn't have written it down here, but.
Q. Can you give us time references so we can watch it in real-time, Doctor?
A. You mean -- you're just going to have to go back a few images and forward. So, I mean, you just reverse for a few cycles and then play it through.
MR. WHEELER: Back it up, TJ. Let's look at it in real-time.
Your Honor, we won't have a specific exhibit for this reference. We'll try to do it by time numbers on this overall study, but the exhibit number for the overall study is Exhibit D-42 -- I'm sorry -- D-4449. Play it through that time frame in real-time and we'll let the doctor comment.
Q. Doctor, do you see where your sonographer is measuring an area of something on the study in the PLAX view?
A. Well, that's actually an apical view.
Q. Okay.
A. That's a three chamber view. Yeah, --
Q. Would you agree --
A. She kind of shows me where she thinks the jet is.
Q. Would you agree Doctor, that the gain on this studies such that it would be very difficult to attempt to accurately quantify any jet height in the PLAX view?
A. No question.
Q. All right?
A. This is tough.
MR. WHEELER: I have no further questions for the witness, your Honor.
JUDGE WALSH: Anything, Mr. Napoli.
MR. NAPOLI: Yes.
REDIRECT EXAMINATION BY MR. NAPOLI:
Q. Doctor, did you measure on the Ryan case in the PLAX view in making a determination that there was mild aortic regurgitation?
A. I haven't measured it, I don't have the measurements here but I have measured it and it exceeded the 10 percent that I described.
Q. Okay.
A. More so in the short axis I actually spent more time in the short axis.
Q. And, Doctor, Mr. Wheeler talked about what the court allows and one of the things is the PLAX view is not available, you can look to the other views to determine whether or not there's aortic regurgitation. Assuming for the moment that the PLAX view is not sub-optimal but unavailable, would those other views assist you in determining whether there was mild aortic valve regurgitation?

MR. WHEELER: Objection, your Honor there's specific alternative views.
JUDGE WALSH: There is specific alternative views. It's right in the settlement.
MR. NAPOLI: It's the short axis?
MR. WHEELER: No.
JUDGE WALSH: No, it is not.
MR. NAPOLI: It's the four chamber?
JUDGE WALSH: No, it is the apical.
MR. NAPOLI: Apical excuse me.
JUDGE WALSH: Long axis.
Q. Can you look at the apical long axis in this case, Doctor?
A. The apical five chamber view, it's what we call a five chamber view we hardly saw the other chambers, but -- so we -- I could see it in the short axis, parasternal and the five chamber and the five chamber apical.
Q. And the five chamber apical, the apical long axis view, is that the same; is that what you're telling me?
A. Yes.
Q. Okay. And, Doctor, what would be required for -- for the PLAX view to be considered medically to be unavailable?
A. If I didn't see anything whatsoever but when you re played that -- by the way I don't have video anymore --
Q. They have the screen off?
A. But when you re played that, there was one cycle where I could see a narrow -- a narrow jet of aortic insufficiency in the PLAX view that that represents -- -- so we don't have that one frozen anywhere. I've never seen that actually frozen anywhere but when you played that through, there is a narrow jet that I could see, so, -- on the PLAX view.
Q. So, it was available?
MR. WHEELER: Your Honor, I object to leading.
Q. Was it available?
A. It was available and it was sub-optimal to measure.
Q. Okay.
A. So it was -- because when that he went through it was -- the jet was into the ventricle enough that you couldn't get close enough to the valve leaflet to get an accurate measurement.
Q. And Doctor, do you know the technician that's involved with conducting this study on Cathy Ryan?
A. I think, yes, I think it's Arlene Crane.
Q. And, Doctor, as part of your practice of supervision of technicians, is there some interplay between you and the technician through the echocardiogram?
A. On some of these -- you know, those -- but not every one back and forth. She came in on a Friday and did her study and was paid per study.
Q. Specifically in Cathy Ryan's case, some of the aortic jets were circled as Mr. Wheeler pointed out.
A. Uh-huh.
Q. And what would be the reason why she would do that?
A. I can only guess that she was having a difficult time doing the measurements and she was either -- in retrospect she's leaving it for me to measure or -- I don't know.
Q. Okay. Doctor, also on the Ryan case, the Nyquist limit, does the Nyquist limit of 48 in any way effect your diagnosis of aortic regurgitation?
A. You know, I don't really believe so. I think we're at the limit of an adequate study there and that may be one of the factors is that we're up against this just how fast you can -- you can measure things and you know you've got a depth

Neither Dr. Sherrid nor Dr. Marino found evidence of MAR in the PLAX or apical long axis view. Dr. Sherrid states that the "[j]et is very narrow and insubstantial at its actual origin. Any measurement made on a selected beat would exagerate [sic] the true situation which is that the jet is trivial." Dr. Marino notes that:

> On at least two occasions, the sonographer measured the area of the purported aortic regurgitation jet rather than making linear measurements. There is no holodiastolic aortic regurgitation seen on this echocardiogram. Only a trace amount of signal is seen for less than most or all of diastole, and it is primarily low velocity flow.

There is no doubt that this echocardiogram is technically infirm. The Nyquist limit of 48 cm/sec is simply too low to get reliable results. Even Dr. Burnett admitted that this echocardiogram was at the limit of his acceptance. While the Court found Dr. Burnett's explanation for the low Nyquist setting to be credible, this cannot permit the use of an echocardiogram whose technical quality makes any medical judgments about valvular regurgitation incredible. Even going to the merits, no reasonable medical conclusion can be drawn from this echocardiogram that Ryan has MAR. Dr. Burnett admitted that the PLAX view was available and he could not find any indication of MAR. In fact, he noted that the traced images provided to him by his technicians were likely artifact.[29] Dr.

> problem. You've got, you know, -- it's a difficult study and you're -- so, I would say yes, that's probably part of the problem.
> Q. And that didn't effect your diagnosis in this case?
> MR. WHEELER: Object to leading.
> JUDGE WALSH: Yes, it's leading.
> Q. Did that effect your diagnosis in this case?
> A. No, I'm sure it does affect your ability to get good measurements, yes.

[29] Dr. Marino's criticisms of Dr. Burnett's approach mirror the Court's. His remarks are set forth below.

> I … noted in my original report that the black and white gain on this study is suboptimal making it difficult to reliably measure the LA area or to reliably calculate the RJA/LAA ratio. As a result, the inappropriately high 2-D gain setting also makes this a technically inadequate study such that no medically reliable conclusions concerning the degree of mitral regurgitation can be made from this study.
>
> [I]n spite of the technical limitations of this study, no FDA Positive AR … is present on this study. Dr. Burnett does not provide specific time markers to support his conclusion that moderate AR is present, but merely states that measurements in the PLAX view and the apical five-chamber view demonstrate the presence of moderate AR. I have reviewed all of the measurements in the PLAX view and I did not view any holodiastolic FDA Positive aortic

Burnett clearly relied on the apical 5-chamber view to support his conclusion that Ryan has MAR. But this is not even an acceptable alternate view; the only alternative view is the apical long axis (apical 3-chamber view). Taking the evidence most favorably to Ryan, the Court concludes that Wyeth has established that no reasonable medical conclusion that Ryan has MAR could be drawn from this echocardiogram.

FFF. THOMAS SCORSONE

Scorsone relies on a September 25, 2002 echocardiogram report by Dr. James Colasacco. Dr. Colasacco found that Scorsone had MMR using CAS criteria -- RJA/LAA = 23%. Dr. Colasacco noted that this was a "[g]ood quality study."

The echocardiogram was reviewed by three (3) experts: Dr. Marino, Dr. Sherrid and Dr. Colasacco. All three (3) physicians found the echocardiogram to be technically adequate.

Both Drs. Sherrid and Marino found the MMR claim was unsupported. Dr. Sherrid reported that only one (1) in eight (8) beats shows mitral regurgitation "and then it is trivial." Dr. Marino agreed.

> The purported mitral regurgitation does not have the characteristics of true mitral regurgitation because it does not emanate from the mitral valve and does not last through all of systole. The purported regurgitant jet was overtraced and included blue signal from the left ventricular side of mitral valve and black signal in the left atrium.

Dr. Colasacco disagreed. Dr. Colasacco found that Scorsone had MMR ,finding a RJA of 1.80 cm^2 and a LAA of 7.63 cm^2 which computes to 24%. But Dr. Colasacco acknowledged that he measured the left atrial diameter at 4.9 cm. A

---

regurgitation on this study. On at least two occasions, the area of the regurgitant jet was measured, rather than the jet height. Although a tiny amount of color is visible in the PLAX view, this signal is primarily low velocity flow and is not holodiastolic. It certainly is to indicative of FDA Positive AR. Finally, pursuant to the requirements of the Class Action Settlement Agreement, because the PLAX view is available, it is inappropriate to rely on any measurements made in the apical view, as Dr. Burnett did….

finding of a LAA of 7.63 cm^2 is inconsistent with a 4.9 cm left atrial diameter and calls into question this measurement.

> Q. Did you have your original report in front of you on Scorsone?
> A. I'm sorry, no, I don't.
> MR. AGNESHWAR: Let's put it up. It is -- what is it?
> MS. PETERSEN: It's D-4187.
> MR. AGNESHWAR: It's defense Exhibit 4187. You characterize the left atrial diameter as normal; didn't you on paragraph 3?
> A. Yes, I did.
> Q. Okay and in fact you characterize it also 4.9 centimeters on the apical four chamber view; correct?
> A. Correct.
> Q. And based on your own testimony just a minute ago, that's getting to the upper limits of normal if not enlarged; correct?
> A. That is correct.
> Q. But you measured a 7.6 [cm^2], which you testified in response to the judge's question for area that is 2 to 3 standard deviations smaller than the average?
> A. Correct.
> Q. And you stand by that measurement?
> A. I -- this measurement here may not be from that particular slide, though.
> JUDGE WALSH: Well -- it's the same heart, I hope. It may not be the same slide, but I think what Mr. Agneshwar is driving at, when you have a 4.9 centimeter diameter it's awful hard to have an area measurement of 7.68; wouldn't you agree with that?
> THE WITNESS: I would agree.

Dr. Colasacco claims that spectral Doppler supports his claim that the mitral regurgitation seen by him is holosystolic. The Court disagrees. Review of the echocardiogram's continuous wave shows the purported jet clearly is not holosystolic. This review also shows that the purported jet is not holosystolic by

color Doppler and that the jet Dr. Colasacco chose to trace is right at the beginning of systole.[30] The phenomenon reported is consistent with closing volume.

The Court finds that Wyeth has established that no reasonable medical conclusion could be drawn from this echocardiogram that Scorsone has MMR.

GGG. NATHAN SHAMOSH

Shamosh relies on an October 24, 2002 echocardiogram report by Dr. James Colasacco. Dr. Colasacco found Shamosh had MMR using CAS criteria -- RJA/LAA = 27%.

The echocardiogram was reviewed by three (3) experts: Dr. Marino, Dr. Sherrid and Dr. Colasacco. All three (3) physicians found the echocardiogram to be technically adequate.

Both Drs. Sherrid and Marino concluded that Shamosh does not have MMR based on their review of his echocardiogram. Dr. Sherrid found that on a number of pages of this Dicom format, there is no evidence of mitral regurgitation. He criticized the study and retraced frames that claimed to support a MMR diagnosis because "[t]he traced frames do not give context, that is, the full loop. We cannot assess if the regurgitant area shown is just a transient puff or if it continues on several frames in systole. The full loops 37 and 42 are better. But they show mild to trivial mitral regurgitation."

Dr. Sherrid planimetered loops at frames 42 and 37 and developed RJA/LAA percentages of 9.7% and 6.8%, respectively. The LAAs were similar to those traced by Dr. Colasacco. Plainly, the differences between them lay in the

---

[30] Dr. Marino's reply certification makes many of these same points.

> As I indicated in my original report, there is no true mitral regurgitation [ ] present on this study. The flow selected for measurement on the original study does not have the characteristics of true mitral regurgitation because it does not emanate from the mitral valve, and does not last throughout systole. Although Dr. Colasacco asserts that he conducted planimetry at Page 26, the bulk of the flow traced is laminar blue signal from the ventricular side of the valve, and does not appear to be a jet emanating from the mitral valve, as true regurgitation would be. It is more likely simply a closing volume, based on its velocity and appearance. Furthermore, on Page 26, it appears that the left atrial border is arbitrarily traced. The structure is not adequately visualized on this Page.
>
> Continuous wave Doppler throughout the mitral valve confirms the absence of high velocity flow characteristic of mitral regurgitation.

RJA tracings. Dr. Marino concurred with Dr. Sherrid that closing volume was a reasonable explanation for the phenomenon observed and noted that the RJA tracings by Dr. Colasacco were aggressive. "The purported regurgitation appears to be closing volume and is not true mitral regurgitation. The RJA was significantly overtraced and included laminar blue flow."

Dr. Colasacco disagreed. He found MMR based on two (2) measurements of RJA/LAA (3.45 cm^2/12.25 cm^2 and 2.73 cm^2/9.8 cm^2). Both RJA/LAA measurements computed to 28%. He identified these tracings as frames 26 and 28 on the Dicom. Dr. Colasacco conceded that these frames were at the very beginning of systole.

The Court finds that Wyeth has established that no reasonable medical conclusion that Shamosh has MMR could be drawn from the review of this echocardiogram. The phenomenon is not well visualized by Dr. Colasacco. In Dicom frame 26, he appears to be measuring a jet at the beginning of electrical systole which occurs momentarily before mechanical systole. Dr. Marino claimed that in this frame the mitral valve was not fully closed. There is some dispute as to whether the purported jet is holosystolic but, in any case, it is clear that Dr. Colasacco took his measurements in the earliest systolic phase. The Court's review of the echocardiogram shows that spectral Doppler fails to confirm the high velocity (4 to 6 meters/second) one would expect to see in a truly regurgitant jet. Moreover, the Court finds Dr. Colasacco was aggressive in his RJA tracings including dark blue laminar flow within these two (2) jets. Finally, even if one were to assume there was sufficient evidence so that reasonable people could differ over whether the jet was holosystolic and whether the LAA was properly taken at this stage of systole, Dr. Colasacco's RJA measurements cannot be reasonably supported.

HHH. MICHAEL J. SHEEHY

Sheehy relies on a May 29, 2002 echocardiogram performed by Cardiac Consultants of Chicago, Ltd. and a report by Dr. Richard Levinsky. Dr. Levinsky found that Sheehy had MMR using CAS criteria -- RJA/LAA = 30%.

The May 29, 2002 echocardiogram was reviewed by three (3) experts: Dr. Marino, Dr. Sherrid and Dr. H. Cohen. Both Drs. Marino and Sherrid questioned the technical adequacy of the echocardiogram. Dr. Marino found that the echocardiogram was not conducted in a technically adequate manner such that

reliable medical conclusions regarding valvular regurgitation could be drawn from it. According to him:

> The study was not technically adequate, and a conclusion that Mr. Sheehey [sic] is FDA positive can not [sic] be reliably drawn from this echocardiogram. The black and white gain was set very high, so that there is an improper signal to noise ratio. A high black and white gain setting can create significant background noise making it impossible to accurately measure the LAA. Also, the sonographer did not measure RJA/LAA on the study, making it impossible to determine whether the Singh criteria were followed.

Dr. Sherrid checked "Yes" to the question regarding the echocardiogram's technical adequacy, but then observed that it had "[b]arely adequate imaging." In another part of his report, Dr. Sherrid noted "terrible imaging" and "[a]wful tracing."

Dr. H. Cohen reported no technical difficulties with this study, finding "[t]he echocardiogram settings were appropriate and the study was of diagnostic quality." He confirmed this conclusion during his testimony at the hearing.

Both Drs. Sherrid and Marino found that despite the technical quality they were able to conclude that no reasonable medical conclusion could be drawn from this echocardiogram that Sheehy has MMR. Both found that the observed phenomenon occurred early in systole, was not holosystolic and was consistent with backflow or closing volume.

Again, Dr. H. Cohen disagreed and pointed to six (6) locations he claimed supported his conclusion. The Court reviewed the echocardiogram and finds Dr. Marino's observation on these findings to be in accord with its own.

> Dr. Cohen refers to several time markers (38:38:08; 38:41:00; 38:41:29; 38:42:24; 38:43:21; and 41:26:26) as demonstrating the presence of moderate mitral regurgitation. There are no measurements recorded on any of these frames. I have reviewed the frames in detail and I see either non-aliased flow or closing volume signals only.

> Dr. Cohen also asserts that spectral Doppler views confirm his conclusion regarding the presence of moderate mitral regurgitation. However, CW Doppler through the mitral valve does not demonstrate the presence of any high velocity flow characteristic of true mitral regurgitation.

` The Court finds that Wyeth has established that this echocardiogram is so technically flawed that no reasonable medical conclusion regarding the presence and severity of valvular regurgitation could be drawn from it. To the extent the echocardiogram can be analyzed, it demonstrates that no reasonable medical conclusion that Sheehy has MMR could be drawn from it.

III. FRANCES SHEPHERD

Shepherd relies on a June 25, 2002 echocardiogram and a report by Dr. Scott L. Roth. Dr. Roth found that Shepherd had MMAR using CAS criteria -- JH/LVOT = 29% (.5cm/1.7cm). The technician performing the echocardiogram suggested Shepherd had SAR with JH/LVOT = 62% based on three (3) readings (JH = .74, .82, .91; LVOT = 1.47).

The June 25, 2002 echocardiogram was reviewed by three (3) experts: Dr. Marino, Dr. Sherrid and Dr. Lassetter. Both Drs. Sherrid and Marino found that the Nyquist limit in the critical PLAX view was too low. Dr. Sherrid observed that the "[a]liasing velocity [was] too low in [the] parasternal view to reliably read." He also noted that the apical long axis (apical 3 chamber) view was not available. Dr. Marino agreed, stating "[t]he Nyquist limit is 41 cm/sec, making the echocardiogram technically inadequate. Therefore, no reliable medical conclusions could be drawn from this study. A low Nyquist limit can produce artifacts that can be misinterpreted as regurgitation and can exaggerate the degree of any regurgitation that may be present." As a result, both concluded that, as to the PLAX view the echocardiogram was not conducted in a technically adequate manner such that reliable medical conclusions regarding the presence and severity of valvular regurgitation could be drawn from it.

Dr. Lassetter disagreed, finding the echocardiogram to be "of diagnostic quality with an adequate gain setting and an acceptable Nyquist limit of 51 [cm/sec]." He claimed to have measured a JH of .81 cm and a LVOT of 1.19 cm

in the PLAX view which computes to 42.4%, which Dr. Lassetter claims is MMAR (under Singh it actually is SAR).

Dr. Marino disputed Dr. Lassetter's claim that the Nyquist limit was at or above 51 cm/sec during any PLAX view.

> As I stated in my original report, the Nyquist level is set inappropriately low at 41 cm/sec in the PLAX view (the required view under the Class Action Settlement ("CAS") for assessing aortic regurgitation). Due to the low Nyquist level, it is impossible to reliably assess the degree, if any, of aortic regurgitation in the PLAX view. Although the Nyquist level increases later on the study to 51 cm/sec, this is only in the apical views.
>
> A low Nyquist setting can exaggerate the severity of regurgitation. For that reason, a panel of experts convened by the American Society of Echocardiography in July 2003 stated that the Nyquist limit should be set above 50 to approximately evaluate the level of regurgitation.
>
> * * * *
>
> Because the Nyquist limit was set inappropriately low in the PLAX view on this study, the echocardiogram is technically inadequate to assess the degree and presence of aortic regurgitation in the PLAX view as required under the CAS. Therefore, I disagree with Dr. Lassetter's conclusion that the degree of aortic regurgitation can be reliably assessed in the PLAX view on this study.

The Court has reviewed the testimony as well as the echocardiogram. It is evident that the Nyquist limit was set at 41 cm/sec during the interrogation in the PLAX view. Dr. Lassetter practically conceded that his claim that the Nyquist limit of 51 cm/sec in the PLAX view was, at the very least, an error.[31]

---

[31] Dr. Lassetter's direct testimony on this point is set out in full.

> Q. Have you had an opportunity, Dr. Lassetter, to review the echocardiogram dated June 25th of 2002 on Frances Shepherd?
> A. Yes.

Q. Based upon your review of the echocardiogram dated June of '02, did you consider it to be of diagnostic quality?
A. Yes.
Q. Did you see any FDA positive levels of aortic regurgitation on this echo?
A. Yes.
Q. And what level of regurgitation, based upon your review and interpretation of the echo, did you diagnose?
A. Moderate aortic regurgitation.
Q. Did you see the presence of moderate aortic regurgitation in any of the realtime images that you looked at?
A. Yes.
Q. Did you see the presence of moderate aortic regurgitation in the parasternal long axis view as required by the settlement criteria?
A. Yes, I did.
Q. Did you look at this echocardiogram to see if the Nyquist settings were appropriate?
A. Yes.
Q. Do you believe that the Nyquist settings were appropriate for diagnosing aortic regurgitation?
A. Yes.
Q. Did you look at the gain settings?
A. Yes.
Q. Did you feel that the gain settings were acceptable for diagnosing aortic regurgitation?
A. Yes.
Q. If we could turn to page 12 of the echocardiogram on Ms. Shepherd. We're now on page 12 at time clock 10:40, looks like 42 through 40 something. Correct?
A. 41, 42, 43.
Q. Okay. And what view are we looking at here?
A. This is a parasternal long axis view.
Q. And in looking at this parasternal long axis view, do you see the presence of aortic regurgitation?
A. Yes.
Q. Does this view look like there's too much gain?
A. The gain is high and the acoustic color window is narrow here. So you don't actually see the jet at the level of aortic valve, but you do see it well within the outflow tract.
Q. Do you feel that the gain setting on this page 12 is acceptable when looking for aortic regurgitation?
A. Yes.
Q. All right. Now, what's the Nyquist level here?
A. 41 here.
Q. All right. Is that considered to be a low Nyquist level?
A. Yes.
Q. Do you feel like that this is still a diagnostic echocardiogram for aortic regurgitation even with that level of Nyquist?
A. Yes, because actually the Nyquist level later gets changed.
Q. Okay. Do you see the presence of aortic regurgitation as you look at this realtime image?
A. Yes.
Q. Does it look like the aortic regurgitation you see is occurring in diastole?
A. Yes, it is.

The Court finds that Wyeth has established that this echocardiogram was not conducted in a technically adequate manner such that reliable medical conclusions regarding the presence and severity of valvular regurgitation could be drawn from it. In doing so, the Court is aware that Dr. Lassetter reported that Shepherd had MMAR based on information taken from the apical 5 chamber view and Dr. Sherrid agreed that Shepherd has MAR based on his review of these same views.

Perhaps one or both of these physicians are correct. But the Court's role here is not to determine whether any particular plaintiff has valvular pathology. Rather, it is to determine whether the echocardiogram proffered by the plaintiff provides sufficient information so that, *in compliance with the CAS criteria*, a reasonable medical opinion can be formed that the particular plaintiff has at least MAR. The CAS criteria here are specific: aortic regurgitation must be reliably determined based on views taken in PLAX or, if not available, the apical long axis (apical 3 chamber) view. This simply was not done here.

JJJ. CAMILLE B. SNOKE

Snoke relies on a December 19. 2002 echocardiogram and a report by Dr. John E. Lassetter. Dr. Lassetter found Snoke had MMR using CAS criteria -- RJA/LAA. Dr. Lassetter did not provide the percentage but the technician found a RJA of 3.61 cm^2, 4.61 cm^2 and 3.90 cm^2 and a LAA of 17.13 cm^2.

The December 19, 2002 echocardiogram was reviewed by three (3) experts: Dr. Marino, Dr. Sherrid and Dr. Lassetter. Dr. Marino faulted the technical adequacy of the study, noting that "[t]he color Doppler gain was set very high, making it impossible to accurately assess the level of regurgitation." Dr. Lassetter found the echocardiogram "to be of diagnostic quality with appropriate settings for interpretation." During the hearing, however, he conceded that the gain was set "high."[32] Dr. Sherrid made no comment of the quality of the echocardiogram other

[32] Dr. Lassetter's testimony on that score is set out below.

> Q. Let's go to Snoke, please. Your measurements were -- moderate MR were 4.6 and 17.1;. 4.6 for RJA and 17.1 L.A. Right?
> A. That's what it says.
>
> * * * *
>
> Q. Okay. Go to page 37. Now, you list page 37 as being one of the pages that you relied on to assess her regurgitation, correct?
> A. Yes.
> Q. And doesn't this show abnormally high gain setting?
> A. It shows a high gain setting, but it also shows a presence of mitral regurgitation. And I will grant, it is not the best representation of mitral regurgitation on this tape.

than checking the box that it was adequate; and he was not examined by the Court or the parties on these issues.

Both Drs. Sherrid and Marino found that no reasonable medical conclusions that Snoke had MMR could be drawn from review of this echocardiogram. Dr. Sherrid found all the frames that claimed to support MMR were taken in early systole and were consistent with closing volume. Dr. Marino concurred, finding that "there is no sustained holosystolic mitral regurgitation seen on this study." In Dr. Marino's view, severity of mitral regurgitation in any case could not be assessed because of the color gain. Dr. Marino also criticized the RJA measurements as overtraced.

Dr. Lassetter claimed that a representative RJA was 4.6 cm^2 and the LAA was 17.1 cm^2 yielding 27% -- clearly MMR by measurement. Dr. Lassetter, however, conceded that the frames he selected occurred early in systole. He also conceded that at least in the loops shown to him, the claimed mitral regurgitation was not holosystolic. Although he suggested other evidence present in the media may have shown the jet to be holosystolic, he did not identify it in his affidavit or during his testimony.[33] Review of the echocardiogram does not indicate that these color bursts are holosystolic.

> Q. Did you mention the fact that the gain settings were high in your certification, Doctor?
> A. No, sir.
> Q. Let's go to page -- I think the next page you say you relied on is page 38, Exhibit 38. All right. Once again, in this view, Doctor, which you say you relied on to assess this lady's regurgitation, there's still a lot of speckling indicative of high gain, isn't there?
> A. In the apex, yes.
> Q. Go to page 39. Same question here, Doctor. In this view there's still a lot of gain, isn't there, Doctor?
> A. There's a lot of gain, but it does not make for the fact that there is no mitral -- that there is mitral regurgitation -- excuse me -- mitral regurgitation is present despite the fact there is high gain.
> Q. But this is not an ideal quality study because of the high gain?
> * * * *
> A. If we looked for ideal quality on every single person, a lot of people would have nondiagnostic studies. And I will say it again, I don't look and nitpick an echocardiogram to ignore all the evidence present to suggest that mitral regurgitation is present. That is how we are diagnostic. Otherwise, echocardiography would be thrown out and all of these textbooks would be useless if you look for only an ideal setting.

[33] Dr. Lassetter's testimony on this point appears below.

> Q. (BY MR. GHOLSON) Now, this is the other -- one of the other pages that you've referred to in your direct testimony?
> A. Yes.

The Court finds that Wyeth has established that no reasonable medical conclusions can be drawn from this echocardiogram that Snoke has MMR. In so finding, the Court bases its conclusions neither on the technical adequacy of the echocardiogram nor the actual measurements. Although the echocardiogram clearly is suboptimal in quality, Wyeth has not produced sufficient evidence to satisfy the Court that it cannot be meaningfully interpreted. Nor has Wyeth produced sufficient evidence to establish that the measurements, which even Dr. Lassetter conceded, were overtraced. Wyeth has not produced sufficient evidence to show that a different tracing would have brought the ratio below 20% and that interreader variability could not explain these differences. The Court bases its finding solely on the fact that the purported jets here never last for a substantial part of systole. Rather, they are transient, fleeting, color flashes which vanish shortly after systole begins. Such jets can never support a reasonable medical diagnosis of MMR based on the echocardiographic evidence.

KKK. FRANCES SULSER

Sulser relies on a June 17, 2002 echocardiogram report by an unidentified physician cardiologist. The physician found Sulser had MAR using CAS criteria -- JH/LVOT = 16%.

The June 17, 2002 echocardiogram was reviewed by three (3) experts: Dr. Schwartz, Dr. Sherrid and Dr. Lassetter. Both Drs. Sherrid and Schwartz found the echocardiogram was not conducted in a technically adequate manner such that reliable medical conclusions regarding the presence and severity of valvular regurgitation could be drawn from it. Dr. Sherrid noted that "[t]he gain was turned too high." He also noted that, in particular, the gain was "too high of (sic) [in] the parasternal view." Dr. Schultz concurred, finding "[t]he color Doppler gain [to be] excessive."

Q. And according to your testimony earlier, this is the beginning of systole; right?
A. It's early in systole, yeah.

* * * *

Q. Is it fair to say, Doctor, that what you characterize as mitral regurgitant jet on page 73 does not persist throughout most or all of systole required by the Weyman protocol?
A. I will grant it does not persist throughout all of systole.
Q. And it doesn't even persist through most of systole, does it not?

* * * *

A. There is other evidence on this tape. In these frames that you have represented no, it does not.

Dr. Lassetter found the echocardiogram "to be of diagnostic quality with appropriate settings for regurgitation." During the hearing, Dr. Lassetter conceded the gain was "high" but continued to claim the echocardiogram was diagnostic. Dr. Schwartz criticized Dr. Lassetter's conclusions on the adequacy of the echocardiogram.

> Dr. Lassetter contends that the echocardiogram is of diagnostic quality. This is not true. The color gain setting on this echocardiogram is clearly excessive as demonstrated by the speckling throughout the tissue structure on pages 8, 9, 14 and 21.
>
> It is well-established that high gain settings can greatly exaggerate the size of a regurgitant jet. As noted by the America Society of Echocardiography,
>
>> the size of the regurgitant jet by color Doppler and its temporal resolution, however, are significantly affected by transducer frequency and instrument settings such as gain…. [S]ubstantial error can be introduced with use of higher or lower settings than the normal settings to which echocardiographers are accustomed.
>
> ASE Guidelines at 778.

Dr. Lassetter, in his affidavit and at the hearing, testified that Sulser has MMAR. Dr. Schwartz criticized Dr. Lassetter's methodology and conclusions.[34] But the Court does not base its opinion on these disagreements.

---

[34] Both Dr. Lassetter's claims and Dr. Schwartz's criticisms are set out below. Dr. Lassetter found that:

> The aortic regurgitation on this echocardiogram was visualized in the parasternal long axis view, in diastole close to the origin of the valve, tracking backward into the left ventricle. It is seen in multiple frames on pages 10-14. The jet was red/yellow/mosaic in color. The jet color, location, and timing of this jet is consistent with the criteria for aortic regurgitation as stated in the Singh article. Using measured JH of 0.66 cm and the LVOT diameter of 2.0 cm, the Singh ratio of Ms. Susler's AR is 33%, which falls into the moderate range according to Singh criteria.

Dr. Schwartz disagreed:

The Court finds that this echocardiogram was not conducted in a technically adequate manner such that reliable medical conclusions regarding the presence and severity of valvular regurgitation could be drawn from it. Accordingly, Wyeth has satisfied its burden and established that no reasonable medical conclusion could be drawn from this flawed echocardiogram.

LLL. JESSICA M. TALBOT-JAKUBOWSKI

Talbot-Jakubowski relies on a May 30, 2002 echocardiogram performed by the University of Wisconsin Hospital & Clinics and a report by Dr. Peter Rahko. Dr. Rahko found that Talbot-Jakubowski had MMR using CAS criteria -- RJA/LAA. The RJA was measured at 2.9 cm^2 and the LAA was 12.5 cm^2. This computes to a RJA/LAA of 23%. Dr. Rahko commented that the study quality was "good."

The May 30, 2002 echocardiogram was reviewed by three (3) experts: Dr. Schwartz, Dr. Sherrid and Dr. Rahko. All three (3) physicians found the echocardiogram to be technically adequate.

Both Drs. Sherrid and Schwartz concluded that no reasonable medical conclusion that Talbot-Jakubowski has MMR could be made from review of this echocardiogram. Both doctors concluded that the echocardiogram showed trivial mitral regurgitation which was the result of closing volume.

Dr. Lassetter cites pages 10-14 as showing moderate aortic regurgitation. These are single frames, and these images are not shown in real time. It is difficult to discern whether these images represent regurgitant flow because they are not in real time. There is no way to discern whether the purported jet is holodiastolic or what effect the gain has on the purported jets. By way of example, on page 14, even though it is not shown in real time, one can tell that the gain is too high as demonstrated by the sparkling flow in the pre-cardiac tissues. Without seeing the images in real-time, one cannot make a reliable medical diagnosis based on single, isolated frames.

Looking in real time, there is only a flash that is very brief, lasting only two frames in early diastole. True aortic regurgitation lasts throughout diastole. Weyman at 529. The continuous wave Doppler confirms that there is no aortic regurgitation on this study.

Lastly, the purported regurgitant jet is generously overmeasured.

Based on the above, it is not medically reasonable to conclude that this echocardiogram shows any aortic regurgitation.

Dr. Rahko believed the jet he observed was holosystolic although he conceded that most of the CW envelope was in the first third of systole. Dr. Rahko admitted that the jet he traced was in the beginning of systole and concluded laminar flow. He also agreed that under Weyman and Feigenbaum the RJA was overtraced by a significant amount. Dr. Rahko claimed that he traced the jet following the criteria of Singh and planimetered the LAA in the same frame as the RJA measurement because that is what was required by Singh. However, as the Court explained to Dr. Rahko, the CAS referenced Singh only insofar as the mechanical criteria for mitral and aortic regurgitation were concerned. The article was not intended to establish standards for the conduct of these echocardiograms.[35]

---

[35] Dr. Rahko's testimony on these points is set out in full so that the reader will get the full context of his testimony.

> Q. Doctor, if we can now turn to Ms. Talbot-Jakubowski and I'll refer to her as Ms. Talbot if you don't mind. Now, with regard to Ms. Talbot, you certified that she had moderate mitral regurgitation of 23.2 percent, correct?
> A. That's correct.
> Q. Doctor, in your certification of October 29, 2004, you reflected your measurements at certain frames and because of a difference in format on the newest echo report that you certified on February 10, you still had the same measurements from the same frames but they had a different time, correct?
> A. Yes.
> Q. Just because a difference in formatting. All right.
> Doctor, the particular frames that were chosen, and the areas that were measured, those were done by the echo tech as such?
> A. That's correct.
> Q. And you simply reviewed and confirmed those measurements when you reviewed the echo?
> A. My policy on these is if I liked what they measured, I accepted it. If I didn't, I remeasured them at the time I read the study. In this case, I accepted what was measured.
> Q. All right, sir. And in this particular case, we're talking about a measurement that ultimately was 3 to 4 percent above the threshold for it to be FDA-positive, correct?
> A. Correct.
> Q. All right. If we can turn to Exhibit 4581 and that is TJ.1.
> Doctor, that is the particular frame that you utilized, or that was utilized that you have confirmed as yielding a regurgitant jet area of 2.9 centimeters?
> A. Yes, yes, it is.
> Q. Doctor, when one is attempting to assess the degree of a regurgitant jet -- well, let me ask you this way. A regurgitant jet by definition should be a high velocity turbulent flow, should it not?
> A. Okay. Now, I'm going to tell you the same thing I told you in November. When I read this, I applied the Singh criteria as listed in the methods section of that paper and that criteria does not require a high velocity jet.
> Q. All right, sir.
> A. It says blue color or mosaic color. It does not require a high velocity jet and it does not make any requirements about the length of time in systole of the jet. That's how I applied that because that's what the method section says.

Q. Doctor, this particular frame was taken in early systole, at least based upon the EKG, correct?
A. It's taken in relatively early systole, yes.
Q. Is it your testimony that if one plays and reviews the echo that one would find that what you have circled here was holosystolic?
A. If you look at the continuous wave Doppler tracing, there's evidence of holosystolic regurgitation. The majority of the regurgitation is in the first part of systole.
Q. All right. Sir, if one were to look at it in the apical four chamber view, frame by frame, one would not be able to determine that it was, in fact, lasting through most or all of systole, would it?
A. The color flow phenomenon?
Q. Yes, sir.
A. That's correct.
Q. Now, again, and I understand your position that based upon your reading of Singh when you, in fact, attempted to determine the degree or the measurement of what you contended was a regurgitant jet, even if it's laminar blue, if it's nonturbulent, low velocity, you would include that in your measurement?
A. I would. That's my interpretation of that criteria.
Q. All right, sir.

Doctor, would it be fair to say, based upon this frame that if one were to eliminate just the laminar blue, the monochromatic color there, certainly one would end up with a measurement that would at least be a third or more less than the 2.93 square centimeters reflected in this measurement?
A. I can't say that.
Q. Can you say that it would be at least a third?
A. The trouble here is that we don't use variance maps.
Q. Yes, sir.
A. And so our views tend to look a little bit less mosaic than maybe other systems or other centers that use variance maps.

* * * *

Q. Doctor, I'm going to show you with a mouse -- all right. Can you see where I'm pointing here?
A. Yes.
Q. On the -- well, as one looks at it on the left side of the portion measured, can we agree that that is certainly not turbulent and is low flow?
A. Yes.
Q. Low velocity?
A. Yes.
Q. Some might even call that entrainment, would they not?
A. The criteria says nothing about entrainment.
Q. Yes, sir. I'm talking about in the practice of cardiology, many of those at the institution where you practice would call this entrainment, would they not?
A. Well, are we changing the criteria then.
Q. Well, if you would please answer my question, please, sir.
JUDGE WALSH: Well, Doctor, probably a fair comment is that Singh doesn't set the criteria for measurement of the regurgitant jet simply the criteria for the declaration that there's moderate mitral regurgitation. But I take your meaning. That's not the criteria.
THE WITNESS: Yeah, you know, the problem with the Singh criteria, you know, unfortunately, it's based upon the studies done in 1987. They, literally, lifted the sentences right out of the Helmke and Perry papers and plopped them into this paper in 1999. So, unfortunately, when I did this, I said well, that's what they did, okay, I'll measure it that way.
Q. May I reask my question?

A. If you're changing the rules when we reevaluate these things, then you have to let me know.
JUDGE WALSH: Well, I think that's a fair point, Doctor. What I'm letting you know right now is that Singh does not set the criteria for what constitutes the regurgitant jet, simply under the settlement criteria what constitutes moderate mitral regurgitation.

* * * *

Q. Doctor, let me ask you this question. You're familiar with the Weyman textbook, as well as the Feigenbaum textbook, are you not?
A. Yes.
Q. And is the definitions and criteria set out in those two textbooks, this low velocity nonturbulent flow would not be considered as regurgitant jet, would it?
A. Well, probably not.
Q. All right. Now, when we look at the right pointer where I'm pointing, it would appear, would it not, sir, that at the very least the person who circumscribed this area was very generous with the margin on the right, does it not?
A. All right. Let me go up to the monitor.
Q. All right.
A. Move the pointer out of the way.
Q. Sorry.
JUDGE WALSH: Doctor, would it be fair to -- I'm sorry.
A. I'll tell you on your view, I would agree with you. The thing is when I looked at this on the less compressed higher resolution monitor when I first read it, I thought it was an adequate tracing.
Q. All right, sir. Generally, it would not be acceptable to include black on a margin as part of a regurgitant jet, would it?
A. That's correct.
Q. All right. Now, sir, here again, if one eliminates then the monochromatic blue on the left portion of this drawing and eliminates as well that portion that is circumscribed within this area, but which, in fact, is black, meaning there's no flow, can we agree that the amount that would be actually depicted as far as an area would probably be no more than two centimeters if that much?
A. When I looked at this very carefully, what's traced is there's a distinctly different shade of blue that was in that tracing and the blue over on the left is clearly not part of the regurgitant jet and that's why we didn't include it in there, so, you know, when it comes to trying to figure out what's entrained and what's not, I think on this particular one, it's almost impossible. I can't [] tell.
Q. Fair enough. Let me ask you this: In instructing your technicians, do you instruct them as to the most reliable frames in which to attempt to obtain a left atrial area?
A. Okay. Now, here's another interesting thing. When I went back to the first principles of the original definition of this, this technique it clearly says in the method section of that paper that you use the same frame to trace the left atrial area and so that's what we did.
Q. All right, sir.
A. No one ever told me to take a different frame or take a four chamber view and maximize the size of the left atrium. I never had that instruction and so I went back to the literature, went to the original 1987 paper, I've got it right here. It clearly says that what they did when they applied this methodology was they traced the jet and then they traced the left atrium at the very same frame that the jet was displayed in and that's what we consistently did through all of these echocardiograms.
Q. Well, sir, if --
MR. RAMSAY: TJ.2.

Q. I'm going to show you what has been marked as Defense Exhibit 4583. That is the particular frame in which the measurement was made, wasn't it?
A. And that's -- is that 23 -- what's the time stamp on there, I can't -- 2342.
Q. Let me see -- yes, sir.
A. Yeah, that is, that's right.
Q. Well, it wasn't measured in the same frame then, was it?
A. Yes, it was.
Q. But without the color Doppler?
A. We suppressed the color, the same frame.
Q. Once again, this is in early systole, is it not?
A. It's the exact same frame, sir. It's just with the color turned off.
Q. It's in early systole?
A. You can turn the color on and overlay on and off on these Philip systems and we commonly do that when we make a noncolor measurement so we get the color out of the way.
Q. It's measured in early systole, is it not?
A. You're exactly right.
Q. Doctor, I'm going to refer you to Weyman's textbook, Page 474 at 65.4.1, and before I get to it, if you can read down at the bottom, talking about the -- there are normal cyclic variations in the left atrial dimensions, are there not?
A. That's correct.
Q. And the size of the atrium normally changes throughout the cardiac cycle?
A. You're exactly right.
Q. And is it for that reason that in Weyman, that it reflects that the atrial dimensions are most often traced at end of systole just before the mitral valve opening because the atrial volume is greatest at this point?
A. That's the way we generally measure it when we would like to report a left atrial size or volume. You are correct.
Q. That was not done in this case, correct?
A. That was not done in this case for the reasons I've already stated.
Q. Can we agree, sir, that because this measurement was taken in early systole, that in all probability, it understates the true left atrial area had it been measured in late systole?
A. That's correct.
Q. Pause for one second. Consequently, then if you applied the criteria according to Weyman, this would not be considered moderate MR, would it?
A. Well, what Dr. Weyman is talking about is the method of measuring the left atrium and again, it really is determined by what technique you want us to use.

I mean, I'll use any technique you want, just set the rules straight for me.

Q. No, sir, I wasn't clear and that's not (sic) [my] fault. I'm talking about the criteria by Weyman with regard to the fact that the jet would be mosaic or aliased as opposed to a monochromatic dark low velocity flow as well as the timing of the measurement of the left atrial area. If those criteria had been applied to this case, this 23 percent certainly would have been significantly less than 20 percent, wouldn't it?
A. Most likely.

* * * *

JUDGE WALSH: Oh, Doctor, was the jet here holosystolic?
THE WITNESS: The jet is predominantly in the first third of systole. I do not believe this is an artifact of valve leaflet closure because I wouldn't have reported anything like that, but this jet when you look at the continuous loops, it's -- most of the regurgitation also in the first third of systole and then it dies out but if you look at the continuous wave Doppler signal that I mentioned at

While the Court found Dr. Rahko highly credible, it believes that Wyeth has established that no reasonable medical conclusion can be drawn from this echocardiogram that Talbot-Jakubowski has MMR. When the jet is examined, it is clearly overtraced and contains significant amounts of non-aliased blood. The Court also believes that the spectral Doppler here does not support a claim that any mitral regurgitation seen here is holosystolic.

2347, the signal is strongest in the first part, but there still is demonstrable signal all the way out to end systole.

* * * *

CROSS-EXAMINATION BY MR. RAMSAY:

Q. I'm going to ask you, Doctor, to turn to that frame and that's TJ.3.

Now, Dr. Rahko and I don't pretend to be a doctor, much less a cardiologist, but based upon my reading, when one looks at continuous wave Doppler, in determining the extent and duration of a regurgitant jet, one usually is looking for a dense envelope, are they not?

A. Well, the more severe the insufficiency, the denser the envelope tends to get.

Q. One certainly would expect, irrespective of insufficiency, that the envelope would be reasonably well developed if, in fact, one was dealing with a holosystolic jet, wouldn't one?

A. Not necessarily. Ultrasound is a weak medium and it's hard to get a good signal sometimes.

Q. Well, we've already -- I think you've already answered -- we've established the fact that on color Doppler mapping one could not observe a holosystolic jet and so you're looking at the CW based upon this CW, as one looks at the EKG tracing above it, would it be fair to say that whatever occurred at the commencement of systole dies out completely within one-third of that entire systolic cycle?

A. Doesn't die out completely. There's still flow all the way to the end of systole. It's just much weaker. Two possible explanations of that: Number one is the regurgitant jet is predominantly early systolic. Or Number 2 because of motion of the heart or the movement, we're unable to maintain the color -- or the continuous Doppler interrogation beam within the jet throughout all of systole.

Q. Doctor, are you counting when you talk -- in the response you just gave, are you counting this area that appears to be, if it's true flow at all, that appears to be moving at approximately .5 meters a second at most?

A. No, I'm saying, I can see a full envelope, it's weak on the right side of each one of those. There's a whole envelope that is much weaker that gradually diminishes in velocity and extends all the way out to the end of systole where the valve closure artifact is -- or opening artifact is visible. Right where the junction and it crosses the zero line. It's a much weaker signal there and again, in doubly compressed images, it's harder to see these weak signals, but there still is a signal there.

Q. Where there are at least more or two or more probabilities would it be medically reasonable for another cardiologist[] at your institution to conclude based upon this CW that it demonstrates holosystole?

A. I mean I think when you see it, you can see -- you can see it go out all the way to the end, but the signal is much -- is strongest in the first part of systole. There's no question about that.

Q. All right. When you say you see it go all the way out to the end. Are you talking about this area right here?

A. I'm talking about that area.

MMM. ANDREA TURNER

Turner relies on a May 3, 2002 echocardiogram performed by Associates in Cardiology, Ltd. and a report by Dr. Roger A. Billhardt. Dr. Billhardt found that Turner had MMR using CAS criteria -- RJA/LAA = 36%.

The May 3, 2002 echocardiogram was reviewed by three (3) experts: Dr. Schwartz, Dr. Sherrid and Dr. Billhardt. All three (3) physicians found the echocardiogram to be technically adequate.

Both Drs. Sherrid and Schwartz concluded that no reasonable medical conclusion that Turner has MMR could be based on this echocardiogram. Dr. Sherrid found no mitral regurgitation apparent in the study. Dr. Schwartz agreed.

> The duration of the flow was relatively brief (only lasting one frame), and not holosystolic, most consistent with physiologic backflow, rather than true mitral regurgitation. In fact, the purported mitral regurgitation, measured in the apical view, included entirely laminar blue caval flow. Additionally, the sonographer improperly measured the purported mitral regurgitation in the parasternal long axis view as well. Even using this improper view, no holosystolic mitral regurgitation is present.

Dr. Billhardt disagreed, claiming that Turner "has definite regurgitation jet in parasternal long axis view [not an approved view], harder to see on apical 4 chamber view (large woman) but mitral regurgitation jet blooms out into the left atrium." Dr. Billhardt found a RJA of 5.3 cm² and a LAA of 16.55 cm² yielding a percentage of 36%. But during the hearing, Dr. Billhardt conceded that virtually the entire RJA was low flow with laminar characteristics.[36] There simply was no

---

[36] Dr. Billhardt's testimony on this point is set out below.

> Q. You diagnosed Ms. Turner with moderate mitral regurgitation, correct?
>
> * * * *
>
> A. Yes, Ms. Turner was moderate mitral regurgitation.
>
> * * * *
>
> Q. Now, your assessment was 5.3/16.55, and I think this is left atrial area of 16.55. Is this the image that you relied on for that?
> A. It looks to be, but I don't see the tracing of the mitral regurgitant jet, so I am assuming that would come up next.
> Q. Yes, sir. I will refer to it in a moment.

regurgitant jet seen. Dr. Schwartz's critique of Dr. Billhardt's measurements reflect the Court's view: "Dr. Billhardt refers to planimetry obtained at 1:45:30 which clearly encompasses a tiny amount of closing volume and a large area of low-velocity laminar flow emanating from the superior vena cava."

The Court finds that Wyeth has established that no reasonable medical conclusions that Turner has MMR could be based on review of this echocardiogram.

Now, this particular measurement, the cursor is shown at -- toward the end of systole, is it not?
A. Yes.
Q. On the backside of the T wave?
A. Yes.
Q. And that would tend to maximize that left atrial area, wouldn't it, Doctor?
A. It should be fairly large at that point, yes.
MR. GHOLSON: Okay. Let's go to TA.2.
MS. REED: That is Defense Exhibit D4353.
BY MR. GHOLSON:
Q. Now, the area here is 5.277, which is consistent with your assessment of 5.3. Is this the image you relied on for that?
A. Yes.
Q. Okay. Now, what you have -- what has been drawn on here by the technician, I am indicating the top.
A. Uh-huh.
Q. Is it your testimony that this -- that I am indicating with the cursor is high velocity?
A. That area appears to be high velocity, yes.
Q. All right, sir. Now there is a drawing coming -- extending down, which I am tracing with the cursor now. Within that neck, I will call it, is there any high velocity flow there?
A. No.
Q. Okay. And even down to the point where I have indicated with the cursor at this point, is there any high velocity flow?
A. No.
Q. In this image is there seen any high velocity flow connecting the top of what you have described as regurgitant jet with this other blue that is traced within the planimetry?
A. There is not.
Q. Now, the colors that are seen in the bottom half of this planimetry, right here that I am indicating with the cursor, are all contained within the color map over here, correct?
A. Yes.
Q. And would that indicate that the velocities represented there are less than the number on the Nyquist level?
A. Yes.

NNN. JANET E. VAVRA

Vavra relies on a July 13, 2002 echocardiogram performed by Associates in Cardiology, Ltd. and a report by Dr. Roger A. Billhardt. Dr. Billhardt found Vavra had MMR using CAS criteria -- RJA/LAA = 26%.

The July 13, 2002 echocardiogram was reviewed by three (3) experts: Dr. Schwartz, Dr. Sherrid and Dr. Billhardt. All three (3) physicians found the echocardiogram to be technically adequate.

Both Drs. Sherrid and Schwartz found that no reasonable medical conclusion that Vavra has MMR could be based on this echocardiogram. Dr. Sherrid noted that mitral regurgitation was "only seen on rare beats, and when it does occur, it is very, very brief." Dr. Schwartz concurred.

> The duration of the flow was relatively brief (only lasting one frame in early systole), and not holosystolic, most consistent with physiologic backflow, rather than true mitral regurgitation. Additionally, the sonographer improperly measured the purported mitral regurgitation in the parasternal long axis view as well. Even using this improper view, the purported mitral regurgitation was very brief and not holosystolic.

Dr. Billhardt disagreed. He observed a "mitral regurgitant jet [and it was] present in both parasternal long axis and 4 chamber views." His RJA measurements, however, were considerably different from his original ones. For the purposes of his testimony, he measured a RJA of 1.07 cm^2 and a LAA of 5.4 cm^2. This produced a percentage which was actually under 20%. More to the point, the LAA is almost certainly too small to be from an adult human. Vavra is reported to be a relatively small woman (5'2" - 142 pounds). Nevertheless, a LAA of that size would be minus three (3) standard deviations from the mean according to the information reported in the Weyman Text. This means that over 99% of the population would have larger LAAs. The measurements are also inconsistent with the left atrial diameter reported during the study which led Dr. Billhardt to conclude that Vavra's left atrium "was normal in size." Dr. Billhardt essentially acknowledged these facts and further could not locate the frame he purported to measure.[37]

[37] Dr. Billhardt's testimony on this score is set out below.

Q. Janet Vavra. Once again, you diagnosed her with moderate mitral regurgitation, correct?
A. That's correct.
Q. All right, sir.
MR. GHOLSON: Let's look at VJ.2.
MS. REED: That's Exhibit 4356.
BY MR. GHOLSON:
Q. Doctor, is this the image that you relied on for your assessment in this case?
A. 1.552 and 6.074. Not --
Q. Not according to your numbers. This is a little bit different, right?
A. Yeah, that's different.
Q. Okay. Would this number -- would these numbers be consistent with your assessment? You said 1.07 and 5.4. This one is 1.55 and 6.07.
A. This may have been where I remeasured it, but I can't tell you absolutely that this is the complex that I measured again.

* * * *

BY THE WITNESS:
A. And I am afraid that is going to be the problem with having remeasured it.
BY MR. GHOLSON:
Q. Okay. So -- and, I confess, I looked on the study, Doctor. I did not see these precise measurements on there.
A. Right.
Q. Can you direct us to a frame or a page number that would show that regurgitant jet?
A. That would have been wise for me to do, but I didn't write it down.
Q. Okay, sir.

* * * *

BY MR. GHOLSON:
Q. Doctor, as it relates to Mrs. Vavra's study, as I understand it, you retraced what you described as regurgitation to arrive at the numbers which are in your certification, correct?
A. Correct.
Q. And you can't identify the specific page or frame where that was done on the study, correct?
A. That's correct. It is possible that the frame that you had up there was one that I
retraced. It is possible it is another that I looked at and thought was a better indication of whether real mitral regurgitation was.
Q. Would it be fair to say that what you would have traced and the manner and methodology that you used to assess Ms. Vavra was consistent with the others that we have already discussed today?
A. Yes. It would have been showing the regurgitant jet and then also measuring the left atrial area.
Q. All right, sir. Now, in your initial assessment dated July 16, 2002, you assessed
Ms. Vavra's left atrial dimension at 3.8 centimeters, which would be within the normal range, correct?
A. For M-mode dimensions, yes, that's correct.
Q. And in the measurements that you made assessing her putative regurgitation, you found a left atrial area of 5.4 square centimeters?
A. That was what I had -- right. That is the number that I have down there. You are correct.
Q. And that is well below the norm for an adult, correct?
A. That would be low for an adult, yes.

The Court finds that Wyeth easily satisfied its burden to show that no medically reasonable conclusion that Vavra has MMR could be drawn from review of this echocardiogram.

OOO. BARBARA A. WALTERS

Walters relies on an undated echocardiogram report by Dr. James Colasacco. Dr. Colasacco found Walters had MMR and MAR using CAS criteria -- RJA/LAA = 35%; JH/LVOT = 23%. The aortic regurgitation claim was withdrawn at the hearing when Dr. Colasacco testified he could not support it. Dr. Colasacco noted this was a "[g]ood study."

The echocardiogram was reviewed by three (3) experts: Dr. Schwartz, Dr. Sherrid and Dr. Colasacco. Dr. Sherrid simply checked the box saying the study was technically adequate. Dr. Schwartz found that the gain settings were too high, but were adequate to assess mitral regurgitation.

> The color Doppler gain appears too high -- there is increased signal in areas of normal laminar flow and sparkling color pixels in low-flow areas. In the parasternal long axis views, the images appear hazy and the endocardial definition is very poor. In fact, the color pixels are too poor to make reliable measurements of the aortic valve plane. The apical views, however, are adequate to assess mitral regurgitation.

Dr. Colasacco claimed that the echocardiogram settings were "appropriate" and proceeded to his analysis.

Both Drs. Sherrid and Schwartz concluded that no reasonable medical conclusion that Walters has MMR could be drawn from review of this echocardiogram. Dr. Sherrid found nothing but closing volume. Dr. Schwartz concurred. Dr. Colasacco found Walters has MMR, finding a RJA of 3.48 cm^2 and a LAA of 11.20 cm^2 at page 28 of the Dicom.

Dr. Schwartz's criticisms of Dr. Colasacco's conclusions are supported by the echocardiogram and the Court adopts them as its own.

> [I]t is my opinion that the color gain is too high. There is excess color signal throughout the cardiac cycle, and

> sparkling color in the soft tissue, particularly in the near field. This would tend to exaggerate the apparent degree of mitral regurgitation, if any.
>
> Despite this limitation, moderate mitral regurgitation is not present. It is well shown in the real-time acquisitions, particularly using the pause/step-frame function, that backflow is seen only during the first 2 frames of systole. Throughout most of systole there is no mitral regurgitation at all. Such a brief amount of signal cannot be construed to represent moderate mitral regurgitation. According to Weyman and Feigenbaum, in accordance with the physiology of valvular disease, mitral regurgitation is a holosystolic phenomenon. This is probably normal closing volume exaggerated by excessive gain. Planimetry of this phenomenon is an inappropriate application of the criteria of Singh, Weyman, Feigenbaum and others, which are intended for the assessment of true mitral regurgitation jets. The clinician in practice would not be considering this patient for mild vs. moderate mitral regurgitation.

The Court finds that Wyeth has established that no reasonable medical conclusion that Walters has MMR can be drawn from review of this echocardiogram. The claimed jet here is not holosystolic. The technical quality of this echocardiogram at best is marginal. The tracing done here was at the outset of systole and the so-called jet was no doubt influenced by the high gain.

PPP. ZANDRA M. WATLEY

Watley relies on a June 3, 2002 echocardiogram and report by Dr. Robert M. Smith. Dr. Smith found that Watley had MMR using CAS criteria -- RJA/LAA = 35%.

The echocardiogram was reviewed by three (3) experts: Dr. Schwartz, Dr. Sherrid and Dr. Charash. Dr. Sherrid found the echocardiogram was not conducted in a technically adequate manner such that reliable medical conclusions regarding the presence and severity of valvular regurgitation could be drawn from it. He found that the "gain is too high in much of this echo." Drs. Schwartz and Charash

found the echocardiogram technically adequate, though Dr. Charash acknowledged the color gain was "a little high."

Both Drs. Sherrid and Schwartz found that no reasonable medical conclusion that Watley had MMR could be drawn from review of this echocardiogram. Both doctors concluded that any jet visualized here was not holosystolic. Dr. Sherrid believed closing volume was a reasonable conclusion. Dr. Schwartz noted that any measured jets occurred early in systole and were not holosystolic.

Dr. Charash agreed that the echocardiogram did not demonstrate that the regurgitant jet was holosystolic, but he believed that this was a function of the movement of the patient's heart and the angle of the transducer. He acknowledged that his RJA/LAA measurements were taken in early systole but believed they were accurate. The Court finds that Dr. Charash's LAA of 9.25 cm^2 is inconsistent with the M-mode finding of 4.07 cm and the cardiologist's conclusion that Watley had "left atrial enlargement."

The Court also agrees with Dr. Schwartz's observations that the measurement Dr. Charash proposes is anomalous.

> It is not medically reasonable to diagnose this plaintiff with moderate mitral regurgitation based on this study. It is well shown in the real-time acquisitions, particularly using the pause/step-frame function, that backflow is seen only during the first 2 frames of systole. Throughout most of systole there is no mitral regurgitation whatsoever. Such a brief amount of signal cannot be construed to represent moderate mitral regurgitation. Planimetry of this phenomenon is an inappropriate application of the criteria of Singh, Weyman, Feigenbaum and others, which are intended for the assessment of true mitral regurgitation jets.
>
> Moreover, spectral data from 13:51:38 support absence of mitral regurgitation throughout most of systole.

The Court finds that Wyeth has established that no reasonable medical conclusion that Watley has MMR could be drawn from a review of this echocardiogram. The jet is plainly not shown to be holosystolic. The quality of the echocardiogram is marginal and Dr. Charash's measurements, which he

conceded in his testimony he accepted on faith because the color gain obscured the left atrial structures, are suspect.

QQQ. TERI M. WEAVER-KENNEDY

Weaver-Kennedy relies on a November 5, 2002 echocardiogram and an April 19, 2003 echocardiogram report by Dr. James Lazar. Dr. Lazar found Weaver-Kennedy had MMR using CAS criteria -- RJA/LAA = 20%.[38]

The November 5, 2002 echocardiogram was reviewed by three (3) experts: Dr. Schwartz, Dr. Sherrid and Dr. Lazar. All three (3) physicians found the echocardiogram to be technically adequate.

Both Drs. Sherrid and Schwartz concluded that no reasonable medical conclusion that Weaver-Kennedy has MMR could be drawn from review of this echocardiogram. Dr. Sherrid found that "[v]irtually all frames show no [mitral regurgitation]…. The CW Doppler shows just how short the [mitral regurgitation] activity is." Dr. Schwartz agreed.

> The purported mitral regurgitation is not holosystolic. In fact, the purported mitral regurgitation is very brief, lasting less than one third of the systolic cardiac cycle. Additionally, the planimetered frames selected are out of context and are not consistent with the real time images.

Dr. Lazar disagreed. In his certification, he reports much larger RJA/LAA ratios than reported in his initial worksheet (RJA/LAA = 32%). But both frames had LAAs which actually were too low (9.8 cm² and 8.9 cm²), and actually conflicted with Dr. Lazar's five (5) previous LAA measurements which averaged 12.4 cm².[39] Even if the RJA measurements he claims to have measured (3.10 cm²

---

[38] Dr. Lazar apparently took five (5) measurements:

1.9/10.9 = 17.43%
2.7/12 = 22.50%
2.2/12.2 = 18.03%
3.4/13.6 = 25 %
2.5/13.3 = 18.79%

He initially concluded that Weaver-Kennedy had mild mitral regurgitation. He altered his worksheet to indicate Weaver-Kennedy had MMR.

[39] Dr. Lazar essentially conceded this fact on cross-examination. He also conceded he altered his review sheets.

Q. Teri Weaver-Kennedy. And in this one you are contending that you found evidence of mitral regurgitation, moderate, 23 to 30 percent; correct?
A. Correct.
Q. And in both of those images that you obtained the left atrial area, here again, the first one you had an 8.9 square centimeter.

Doctor, do you think it would be medically reasonable to rely upon a left atrial dimension of that small of an area in light of what is the normal range, especially for a woman of this lady's size and surface area?

* * * *

A. I would say one would have to be suspect.
Q. All right, sir. Well, in fairness, if one really wants to get the left atrial area, one would then go and see if one could find a more representative measurement where the structures were clear.

And it would probably be systole; correct?
A. Mid to -- mid to end, probably.
Q. All right, sir. And did you look at the -- this particular Dicom to see if, in fact, there was another measurement that might be more representative?
A. Yes.
Q. Did you find any?
A. Difficult to say.
MR. RAMSAY: If you'd pull page 27, please.
Q. Doctor, that looks like that's a pretty clear reflection of the structure of the left atrium; doesn't it?
A. It's not bad. It's a little overtraced, actually.
JUDGE WALSH: It is a little overtraced, but not by much.
Q. Right. And here again, in that particular tracing --
MR. RAMSAY: And we can quibble about whether there's a little undertracing on the left-hand side, Judge. I see what you're talking about on the right.
Q. The figure they came up was 12.87 centimeters. Wouldn't it be fair to say that, at the very least, that particular frame, page 27, is more representative of this lady's true left atrial area than the frames that you measured, on pages 28 -- I think it's 28 and 42?
A. Yeah. I guess it would be.

* * * *

JUDGE WALSH: I do have a couple of questions.

This is your sheet on Weaver-Kennedy, Dr. Lazar. Forgive me. It looks to me like you found -- you did four of these -- five of them, actually.

And you came out with 17 percent on a LAA of 10.9 and a RJA of 1.9. You came out with 18 percent on a LAA of 12.2 and a RJA of 2.2. 19 percent on a 2.5 RJA and 13.3 LAA. 25 percent on a 3.4 RJA and 13.6 LAAA. (sic) And 22 percent with a 2.7 and a 12 centimeter square LAA.

So, you made all those measurements.
MR. RAMSAY: Is this on the screener sheet, Judge?
JUDGE WALSH: Yes. It's his sheet.

So, you're hovering right around 20 percent; right?
THE WITNESS: Right.
JUDGE WALSH: Okay. I mean, you add these up, it adds right to about 20 percent.

I'm showing you the sheet.
THE WITNESS: Could it be present in another medium?
JUDGE WALSH: You're the one that did the review. How do I know that? This is your worksheet.
MR. D'ANGELO: I believe the Dicom studies are only on Dicom.
JUDGE WALSH: Well, I don't know what they're on, Mr. D'Angelo. But I have a worksheet that's in evidence that basically --

and 2.05 cm^2) were used, the RJA/LAA ratio would continue to hover around 20%. The Court, based on the record before it, puts little value on Dr. Lazar's later measurements.

The Court finds that Wyeth has satisfied it that no reasonable medical conclusion that Weaver-Kennedy has MMR could be drawn from this echocardiogram. The measurements which are suspect hover around 20%, but the jet is clearly not holosystolic. Further, review of this study is hampered by the high gain in the only diagnostic loop seen in the apical view.

RRR. PAULA K. WILLIAMS

Williams relies on a November 23, 2002 echocardiogram and a report by Dr. Scott L. Roth. Dr. Roth found that Williams had MAR using CAS criteria -- JH/LVOT = 20%.

The November 23, 2002 echocardiogram was reviewed by three (3) experts: Dr. Schwartz, Dr. Sherrid and Dr. Lassetter. Dr. Sherrid found that the echocardiogram was not conducted in a technically adequate manner such that reliable medical conclusions regarding the presence and severity of valvular regurgitation could be drawn from it. Dr. Sherrid noted that the gain settings were too high. Dr. Schwartz agreed that the gain was too high, but believed the echocardiogram could be interpreted. Dr. Lassetter found the study "had an adequate gain setting."

I mean, did you write this?
THE WITNESS: Yes.
MR. D'ANGELO: What's the date?
THE WITNESS: 11/5/02.
JUDGE WALSH: The date of review is 4/19/03.
MR. D'ANGELO: No. The date of the study.
THE WITNESS: Same date.
JUDGE WALSH: So, that's your worksheet. You're really hovering, as I said, right around 20 percent.
If you add all the figures up, you probably come out right at -- just at 20. Then your review document comes out at 32 and 23 percent.
So, how can that be?
THE WITNESS: Obviously I selected two of the five frames.
JUDGE WALSH: Well, the fact is you didn't. I mean, the sheet will speak to it. But those measurements aren't on this sheet. At least they're not on the sheet that I have.
So, can you explain that?
THE WITNESS: No.

Dr. Sherrid found no aortic regurgitation in the PLAX view which was available. Dr. Schwartz found the same thing. "Although the parasternal long axis view was available, the measurements were made in the apical 5-C view and apical 3-C view. In the apical 3-C view, the JH was not measured close enough to the aortic valve plane or perpendicular to the left ventricular outflow tract."

Dr. Lassetter disagreed. He claimed "[t]he parasternal long axis view is not well demonstrated on this study; the aortic regurgitant jet is, however, well demonstrated in the apical 5 chamber view. The jet is red/yellow mosaic in color and is demonstrated during diastole."[40]

---

[40] During the hearing, Dr. Lassetter made it clear that he relied on the apical 5 chamber view which is not an approved view.

> Q. (BY MR. GHOLSON) The parasternal long axis view is available on [Williams's] study, correct?
> A. And I disagree with that statement[]
> Q. Well, this is the parasternal long axis view, is it not?
> A. It is. And the acoustic window for color flow is inadequate in order to diagnose aortic insufficiency, and there is ample evidence elsewhere in this echocardiogram to support the presence and the level of aortic regurgitation.
> Q. Let me ask you a different way. When the technician was performing this study, they were able to capture the parasternal long axis view on the study, correct?
> A. Correct.
> Q. And the reason you say it's not available is simply because the acoustic window, the color window is not large enough to capture the view?
> A. That's not what I said.
> Q. Okay.
> A. The body habitus and the characteristics of this acoustic window are not such that color flow is adequate to make the diagnosis. There is a suggestion of aortic insufficiency here, but not enough to make the diagnosis. The other views are better. And in clinical practice, I don't nitpick
> through an echocardiogram in order to say, oh, this view is not available, so therefore I ignore all other evidence and now make a diagnosis.
> Q. Nevertheless, you did not do any assessment of Ms. Williams' alleged aortic regurgitation in the parasternal long axis view, did you?
> A. No. I didn't think this was adequate enough to make that diagnosis.
> Q. And what you relied on was on page 48, which is an apical view; correct?
> A. That is correct.
> Q. Can you flip over to page 48. Just to confirm, Doctor, this is the view that you used to assess what you characterize as aortic regurgitation; correct?
> A. Yes.
> Q. Now, the gain is high also in this view, isn't it?
> A. Yes, it is.
> Q. And the reason that you want to make sure that the gain is appropriate is because if gain is too high it can introduce artifact into the study, can't it?
> A. If it is too high, yes.

During the hearing, it was clear that Dr. Lassetter attempted to make a diagnosis of MMAR or MAR with frames taken from the apical 5 chamber view. He claimed that the PLAX view was not technically adequate, but under those circumstances the CAS requires the diagnosis to be made from the apical long axis (apical 3 chamber) view. Dr. Lassetter conceded that he did not attempt to use that view, thereby dooming his analysis.[41]

---

[41] Dr. Lassetter's direct testimony in this regard is instructive.

> Q. In your opinion, do you feel the parasternal long axis view on Ms. Williams' echocardiogram was unacceptable to evaluate aortic regurgitation?
> A. As far as the color flow and dynamics of that view, yes.
> Q. Did you look to see if there was aortic regurgitation with regard to the apical long axis view on Ms. Williams' echocardiogram?
> A. Yes, I did.
> Q. All right. Was the apical long axis view acceptable in terms of determining whether or not Ms. Williams had aortic regurgitation?
> A. Well, in my statement I don't make any particular mention of the apical on the (sic) [long] axis view.
> Q. It is, though, a view that you take into consideration when looking for aortic regurgitation?
> A. Yes. It is one of the three views that you can demonstrate aortic regurgitation with.
> Q. What other view did you look at in this study to see if there was the presence of aortic regurgitation?
> A. The apical five-chamber view.
> Q. Is the apical five-chamber view an acceptable view for measuring aortic regurgitation?
> A. Yes, it is.
> Q. Do you use the apical five view in your clinical practice to evaluate whether there is or is not presence of aortic regurgitation?
> A. Yes. In fact, it's one of the more common ones to interrogate with spectral Doppler or continuous wave Doppler to measure pressure half time.
> Q. Did you look to see whether or not the Nyquist settings were appropriate in the frames that you utilized for diagnosing aortic regurgitation on this echo?
> A. Yes, I did.
> Q. And were they appropriate?
> A. Yes.
> Q. Was the gain setting appropriate for diagnostic purposes of aortic regurgitation?
> A. Yes.
> Q. If we can turn to page 48. All right. Doctor, we're now on page 48. We're at time clock 13:27:02 through 05. And are we -- is this a realtime image?
> A. Yes, it is.
> Q. And what are we looking at here?
> A. This is an apical five-chamber view demonstrating -- or with color flow interrogation on the aortic valve demonstrating aortic regurgitation.
> Q. Okay. And as this realtime image runs, do you see the presence of aortic regurgitation?
> A. Yes.
> Q. Is it occurring during diastole?
> A. Yes, it is.
>
> * * * *

The Court finds that Wyeth has established that no reasonable medical conclusion that Williams has MAR or MMAR could be drawn from review of the PLAX view or the apical long axis view.

SSS. DAWN M. YOUNG

Young relies on a May 8, 2002 echocardiogram performed by Associates in Cardiology, Ltd. and a report by Dr. Neal Ruggie. Dr. Ruggie found Young had MMR using CAS criteria - RJA/LAA = 29%.

The May 8, 2002 echocardiogram was reviewed by three (3) experts: Dr. Schwartz, Dr. Sherrid and Dr. Ruggie. All three (3) physicians found the echocardiogram to be technically adequate.

Both Drs. Sherrid and Schwartz found that no reasonable medical conclusion that Young has MMR could be drawn from review of this echocardiogram. Dr. Sherrid concluded that closing volume was all that was seen. "This MR is a trivial early systolic 'closing' puff caused by the shutting of the mitral valve. For many beats no MR is seen 00:25:30, 17:08, 17:20. :54 and 1:14 transient puff. 12:20 Trivial MR, transient puff.[] All the beats at 18:00, 11:14 are all very soft puffs. The transient nature of these puffs is nicely shown on CW Doppler at 10:17." Dr. Schwartz is of the same view. "The duration of flow was relatively brief (only a 'flash'), and not holosystolic, most consistent with closing volume, or backflow, rather than true mitral regurgitation. Additionally, the left atrium was measured in early systole, rather than at end systole."

Q. Okay. From the multiple frames that we've looked at right here where we talked about aortic regurgitation, did it seem the gain setting was a little high?
A. I think it is on the high end.
Q. Okay.
A. In an ideal setting you'd like to get the speckling out of the apex of the ventricle. But it is not too high as to obscure the presence. Let's put it this way: high gain is not going to make an aortic regurgitant jet be present.
Q. Okay. Well, do you believe that the gain setting here still allows you to diagnose aortic regurgitation?
A. Absolutely.
Q. Does the gain setting here, is it turned up such that it would exaggerate the size of the jet?
A. I don't believe so.
Q. Would it exaggerate the duration of the jet?
A. No.
Q. And so you believe that this is a true aortic regurgitant jet?
A. Yes.

Dr. Ruggie concluded otherwise. He believed that "the MR jet … [was] present in multiple views and on CW (continuous wave Doppler). I am unaware of any specification that jet needs to be holosystolic." During the hearing, Dr. Ruggie candidly admitted that in his practice he rarely measured left atrial areas.[42] He

---

[42] Dr. Ruggie's testimony on cross-examination is set out below.

> Q. All right, sir. Let's go to Dawn Young, please.
> MR. GHOLSON: That is YD.1.
> MS. REED: That is Defense Exhibit D4359.
> BY MR. GHOLSON:
> Q. This particular measurement, Doctor, shows a regurgitant jet area of 2.93. Does that comport with your finding of 2.94?
> A. Yes, it does. Q. Is this the image that you relied on for your opinion in this case?
> A. I believe so.
> Q. All right, sir. Now, is it your testimony that what is encompassed within the planimetry here constitutes high velocity regurgitant flow?
> A. Yes, I believe it does.
> Q. All right, sir. And that is true with all of the area that is encompassed within the planimetry, correct?
> A. Pretty much so, yes.
> Q. Okay. Is there any part that you would exclude as not being high velocity turbulent flow?
> A. You might be able to argue about a little bit at the tip here but not much more than that.
> Q. Okay. According to the EKG, this is done at the beginning or very early in systole, isn't it?
> A. Yes, it is.
> MR. GHOLSON: All right. Pull up YD.2, please.
> MS. REED: Defense Exhibit D4360.
> BY MR. GHOLSON:
> Q. Now, this is a left atrial measurement taken out of that same frame, correct, Doctor?
> A. It's a different frame but same cardiac cycle.
> Q. Same cardiac cycle. Okay.
> It shows an area of 13.86, and your assessment was 13.9. Is this the image that you relied on for your opinions.
> A. I believe it is, yes.
> Q. In your opinion, does this fairly and accurately describe the left atrial area in this lady?
> A. Yes, I think it does.
> Q. Now, I direct your attention to the lower left-hand part of that. There is some black which is on the outside of the tracing. Just above there.
> A. Down here (indicating)? Is that what you mean?
> Q. No, sir. Actually, up -- right there.
> A. Oh, over there? Okay.
> Q. Yes, sir. Would it have been appropriate to include that in the tracing?
> A. I would have to see it in motion, but it is possible. It is possible it is not. The wall is certainly up here this way and it is over here down here. I am not sure exactly where it connects in there (indicating).
> Q. Okay. Again, this cursor shows that, according to the EKG, we are in very early systole, correct?
> A. Correct.

measured a RJA of 2.94 cm^2 and a LAA of 13.9 cm^2, yielding a RJA/LAA equal to 21.2%.

This RJA/LAA measurement was taken at the outset of systole. The purported jet lasts momentarily in this and the other cycles on this echocardiogram. To the extent it would even be appropriate to measure this non-systolic phenomenon, there are large areas of the RJA which no reasonable echocardiologist could demonstrate as a regurgitant jet. Contrary to Dr. Ruggie's belief, the available spectral Doppler does not confirm that this is holosystolic.

Dr. Schwartz's comments made in his reply certification in this regard are consistent with the echocardiogram and the Court's observations.

> There is a small amount of blue signal seen within 1 cm of the mitral valve for one frame at the initiation of systole (at the time of the QRS complex on the ECG tracing) consistent with closing volume. This is well shown in all views. There is also, intermittently, a larger blue "flash" seen in the left atrium at the time of the QRS complex on the ECG tracing, lasting no longer than 1 frame, that represents backflow.
>
> It is well shown that throughout systole there is no mitral regurgitation jet. The planimetry applied in the study to the purported mitral regurgitation jet is both inappropriate given the absence of any mitral regurgitation jet and erroneous in that it includes large areas that have nothing to do with mitral regurgitation.

The Court finds that Wyeth has established that no reasonable medical conclusion that Young has MMR could be drawn from a review of this echocardiogram. The observed phenomenon is consistent with closing volume.

Q. And based on what we have seen, wouldn't you expect, Doctor, that the left atrial area would be larger actually toward the end of systole?
A. That is the same question you asked me before, and I am going to have to think about that one.
Q. All right.
A. Okay? The end of systole.
I think you are right. I think that would be the point of the biggest area. Yes, it would.
Now, would I expect it to be larger than that, I honestly don't know. I don't measure areas.

Certainly, this transient flash, even if considered a regurgitant jet, does not last long enough to signal the pathology represented by a MMR diagnosis.

IV

For the reasons set forth in this Letter Opinion, the following dispositions on Wyeth's eligibility challenges are made.

	Plaintiff	**Docket No.**	**Disposition**
1	Janice F. Adeyemo	L-1396-04	Granted
2	Cynthia Barrett	L-1418-04	Granted
3	Jack L. Bly	L-1644-04	Granted
4	Madeline L. Broadway	L-1500-04	Granted
5	David W. Burnett	L-1390-04	Granted
6	William F. Busch	L-1490-04	Denied
7	Kimberly L. Callison	L-1553-04	Granted
8	Pamela Chudyba	L-2187-04	Granted
9	Laurania Cid-Cruz	L-1091-04	Granted
10	Kelli Crider	L-1956-04	Granted
11	Nathan Davidson	L-2454-04	Granted
12	Christine DiDodo	L-2489-04	Granted
13	Carol Duffey	L-2437-04	Denied
14	Nancy Eder	L-2445-04	Granted
15	Shaun Egbert	L-2447-04	Granted
16	Laura Eske	L-2330-04	Denied
17	Donna M. Evans-Briggs	L-1374-04	Granted
18	Karen Farinella	L-2463-04	Denied
19	Cynthia Fedorik	L-1571-04	Granted
20	Roberta M. Fews	L-1377-04	Granted
21	Marjorie E. Filver	L-1379-04	Denied
22	Zella Fitleberg	L-2465-04	Denied
23	Bernice Folsom	L-2477-04	Denied
24	Diane Fosnow	L-1904-04	Granted
25	Katherine Grayson	L-1893-04	Granted
26	Leonilda I. Harriott	L-1378-04	Granted
27	Marylou Hatley	L-1532-04	Granted
28	Loretta J. Hayes	L-1423-04	Granted
29	Shirley A. Hess	L-1563-04	Granted

30	Rosie Hicks	L-1887-04	Granted
31	Barbara Hines	L-1632-04	Granted
32	Rita Hofeditz	L-1533-04	Granted
33	Dale Kane	L-1726-04	Granted
34	Patrick B. Kane	L-1617-04	Granted
35	Joan Kenaston	L-1425-04	Granted
36	Dennis M. Kilgallon	L-1651-04	Granted
37	Doris King	L-1430-04	Granted
38	Bobbi Jo C. Lapee	L-1628-04	Granted
39	Elaine E. Lee	L-1633-04	Granted
40	Michael P. Lombardi	L-1569-04	Granted
41	Regina K. McGovern	L-1570-04	Granted
42	Kathleen E. McLaughlin	L-1682-04	Granted
43	Unice McReynolds	L-1681-04	Granted
44	Audrey D. Melvin	L-1382-04	Granted
45	Debra Messer	L-1426-04	Granted
46	Adrianne A. Ornelas	L-1443-04	Granted
47	Dorothy Ortiz-Gwitt	L-1444-04	Granted
48	Rebecca Owens	L-1446-04	Granted
49	Kenneth D. Patrick	L-1416-04	Granted
50	Michele R. Pinto	L-1748-04	Granted
51	Sheila J. Pollock	L-1424-04	Denied
52	Aisa Purvis	L-1461-04	Granted
53	Maureen J. Reagan	L-1457-04	Granted
54	Mildred Rivera	L-1384-04	Granted
55	Angela Rivers	L-1388-04	Granted
56	Sheila Rouff	L-1097-04	Granted
57	Kathy E. Ryan	L-1411-04	Granted
58	Thomas Scorsone	L-1389-04	Granted
59	Nathan Shamosh	L-1391-04	Granted
60	Michael J. Sheehy	L-1745-04	Granted
61	Frances Shepherd	L-2311-04	Granted
62	Camille Snoke	L-2298-04	Granted
63	Frances Sulser	L-2294-04	Granted
64	Jessica M. Talbot-Jakubowski	L-1542-04	Granted
65	Andrea Turner	L-1493-04	Granted
66	Janet E. Vavra	L-1555-04	Granted
67	Barbara A. Walters	L-1734-04	Granted
68	Zandra M. Watley	L-1090-04	Granted

69	Teri M. Weaver-Kennedy	L-1551-04	Granted
70	Paula K. Williams	L-2299-04	Granted
71	Dawn M. Young	L-1479-04	Granted