SUPERIOR COURT OF NEW JERSEY

CHARLES J. WALSH
JUDGE

BERGEN COUNTY JUSTICE CENTER
HACKENSACK, NJ 07601-7689
(201) 527-2690

SUPERIOR COURT BERGEN COUNTY
FILED
JUN 01 2005
DEPUTY CLERK

June 1, 2005

Anand Agneshwar, Esq.
Cara Petersen, Esq.
Arnold & Porter
555 Twelfth Street NW
Washington, DC 20004-0106

E. Armistead Easterby, Esq.
Avram J. Blair, Esq.
Amy M. Carter, Esq.
Williams Bailey Law Firm
8441 Gulf Freeway, Suite 600
Houston, TX 77017

Daniel K. Winters, Esq.
Reed Smith LLP
599 Lexington Avenue, 29th Floor
New York, NY 10022

John G. Wheeler, Esq.
Mitchell, McNutt & Sams
105 S. Front Street
Tupelo, MS 38804

Anita Hotchkiss, Esq.
Porzio, Bromberg & Newman
100 Southgate Parkway
P.O. Box 1997
Morristown, NJ 07962

J. Robert Ramsay, Esq.
Ramsay & Hammond
106 Madison Plaza
P.O. Box 16567
Hattiesburg, MS 39404

Thomas J. Herten, Esq.
Herten, Burstein, Sheridan, Cevasco,
Bottinelli, Litt, Toskos & Harz
25 Main Street
Hackensack, NJ 07601

RE: IN RE: DIET DRUG LITIGATION
Master Docket No. BER-L-13379-04MT

PATRICIA AZAIZA v. WYETH, INC.
Docket No. BER-L-3154-04MT

MELODY ASHMAN v. WYETH, INC.
Docket No. BER-L-3155-04MT

DONNA BAGWELL v. WYETH, INC.
Docket No. BER-L-3181-04MT

FAYANN CHRISTENSEN v. WYETH, INC.
Docket No. BER-L-3160-04MT

DEBRA ELLISON v. WYETH, INC.
Docket No. BER-L-2348-04MT

MARIE FILLMORE v. WYETH, INC.
Docket No. BER-L-3157-04MT

NANCY FRAME v. WYETH, INC.
Docket No. BER-L-3090-04MT

CAROL FREDERICKSON v. WYETH, INC.
Docket No. BER-L-3097-04MT

ROBERT GREIDER v. WYETH, INC.
Docket No. BER-L-3115-04MT

JANETTE HARDEN v. WYETH, INC.
Docket No. BER-L-3053-04MT

NANCY HARRIS v. WYETH, INC.
Docket No. BER-L-3176-04MT

ORIA HAYS v. WYETH, INC.
Docket No. BER-L-3075-04MT

RYANN HENRY v. WYETH, INC.
Docket No. BER-L-3093-04MT

CHERIE HEROLD v. WYETH, INC.
Docket No. BER-L-3099-04MT

LISA A. HORNE v. WYETH, INC.
Docket No. BER-L-3246-04MT

GLEN R. HORSPOOL v. WYETH, INC.
Docket No. BER-L-3255-04MT

JEMMA JACKSON v. WYETH, INC.
Docket No. BER-L-3183-04MT

GARY C. JOHNSON v. WYETH, INC.
Docket No. BER-L-3072-04MT

ANI KELESHIAN v. WYETH, INC.
Docket No. BER-L-3114-04MT

GREGORIA LAMB v. WYETH, INC.
Docket No. BER-L-3198-04MT

MICHELLE LINDSAY v. WYETH, INC.
Docket No. BER-L-3202-04MT

ROBERT J. LINDSTROM v. WYETH, INC.
Docket No. BER-L-3092-04

GERI LOFTHOUSE v. WYETH, INC.
Docket No. BER-L-3098-04MT

PATSY MEDEL v. WYETH, INC.
Docket No. BER-L-3172-04MT

LUCRETIA MEHRABAN v. WYETH, INC.
Docket No. BER-L-3177-04MT

KAYLEEN MEIKLE v. WYETH, INC.
Docket No. BER-L-3185-04MT

COLLEEN MILCHAK v. WYETH, INC.
Docket No. BER-L-3188-04MT

CASSONJA MILLER v. WYETH, INC.
Docket No. BER-L-3126-04MT

MATT MONICA v. WYETH, INC.
Docket No. BER-L-3130-04MT

ALFONSO MONSIVAIS v. WYETH, INC.
Docket No. BER-L-3132-04MT

ANN MORGAN v. WYETH, INC.
Docket No. BER-L-3134-04MT

LENORE NAGLE v. WYETH, INC.
Docket No. BER-L-3139-04MT

CONSTANCE NUTE v. WYETH, INC.
Docket No. BER-L-3247-04MT

COLEEN ORTIZ v. WYETH, INC.
Docket No. BER-L-3257-04MT

DOROTHY PARKS v. WYETH, INC.
Docket No. BER-L-3268-04MT

NIKKI PAYNE v. WYETH, INC.
Docket No. BER-L-3282-04MT

JEAN PERKINS v. WYETH, INC.
Docket No. BER-L-3285-04MT

MARGARET PITTS v. WYETH, INC.
Docket No. BER-L-3204-04MT

LORRAINE PRIETTO v. WYETH, INC.
Docket No. BER-L-3233-04MT

DEBORAH RENAUD v. WYETH, INC.
Docket No. BER-L-3267-04MT

CAROL RICHMAN v. WYETH, INC.
Docket No. BER-L-3273-04MT

KATHY ROBERTSON v. WYETH, INC.
Docket No. BER-L-3280-04MT

TRYNA ROSS (STALLINGS) v. WYETH, INC.
Docket No. BER-L-3274-04MT

PATRICIA I. ROTHE v. WYETH, INC.
Docket No. BER-L-3276-04MT

LORRI M. SHELDON v. WYETH, INC.
Docket No. BER-L-3173-04MT

JULIE SHINER v. WYETH, INC.
Docket No. BER-L-3187-04MT

INGA SHURTZ v. WYETH, INC.
Docket No. BER-L-3207-04MT

EVA SIDES v. WYETH, INC.
Docket No. BER-L-3195-04MT

CAROL A. SMITH v. WYETH, INC.
Docket No. BER-L-3197-04MT

DEBORAH J. SMITH v. WYETH, INC.
Docket No. BER-L-3200-04MT

KERRY M. SMITH v. WYETH, INC.
Docket No. BER-L-3205-04MT

RENE D. SMITH v. WYETH, INC.
Docket No. BER-L-3208-04MT

DONNA SPENCER v. WYETH, INC.
Docket No. BER-L-3214-04MT

BEVERLY WELLS v. WYETH, INC.
Docket No. BER-L-3152-04MT

TAMMIE ZACCARIA v. WYETH, INC.
Docket No. BER-L-3223-04MT

Dear Counsel:

This matter is before the Court on applications by Wyeth Corporation, as the successor to American Home Products Corporation ("AHP") and each of its former subsidiaries, affiliates and divisions (collectively "Wyeth" or "defendants") challenging the eligibility of fifty-five (55) plaintiffs to exercise opt-outs from the Nationwide Class Action Settlement ("CAS"). These plaintiffs are: Patricia Araiza ("Araiz"); Melody Ashman ("Ashman"); Donna Bagwell ("Bagwell"); Fayann Christensen ("Christensen"); Debra Ellison ("Ellison"); Marie Fillmore ("Fillmore"); Nancy Frame ("Frame"); Carol Frederickson ("Frederickson"); Robert Greider ("Greider"); Janette Harden ("Harden"); Nancy Harris ("Harris"); Oria Hays ("Hays"); Ryann Henry ("Henry"); Cherie Herold ("Herold"); Lisa A. Horne ("Horne"); Glen R. Horspool ("Horspool"); Jemma Jackson ("Jackson"); Gary C. Johnson ("Johnson"); Ani Keleshian ("Keleshian"); Gregoria Lamb ("Lamb"); Michelle Lindsay ("Lindsay"); Robert J. Lindstrom ("Lindstrom"); Geri Lofthouse ("Lofthouse"); Patsy Medel ("Medel"); Lucretia Mehraban ("Mehraban"); Kayleen Meikle ("Meikle"); Colleen Milchak ("Milchak");

Cassonja Miller ("Miller"); Matt Monica ("Monica"); Alfonso Monsivais ("Monsivais"); Ann Morgan ("Morgan"); Lenore Nagle ("Nagle"); Constance Nute ("Nute"); Colleen Ortiz ("Ortiz"); Dorothy Parks ("Parks"); Nikki Payne ("Payne"); Jean Perkins ("Perkins"); Margaret Pitts ("Pitts"); Lorraine Prietto ("Prietto"); Deborah Renaud ("Renaud"); Carol Richman ("Richman"); Kathy Robertson ("Robertson"); Tryna Ross (Stallings) ("Ross"); Patricia I. Rothe ("Rothe"); Lorri M. Sheldon ("Sheldon"); Julie Shiner ("Shiner"); Inga Shurtz ("Shurtz"); Eva Sides ("Sides"); Carol A. Smith ("C. Smith"); Deborah J. Smith ("D. Smith"); Kerry M. Smith ("K. Smith"); Rene D. Smith ("R. Smith"); Donna Spencer ("Spencer"); Beverly Wells ("Wells"); and Tammie Zaccaria ("Zaccaria").

The Court conducted its fifth evidentiary hearing on Wyeth's challenges which began on May 9, 2005 and concluded on May 24, 2005. During that period, the Court heard testimony given by: Martin E. Goldman, M.D. ("Dr. Goldman"); Charles Gibbs Vasey, M.D. ("Dr. Vasey"); Muhamed Saric, M.D. PhD ("Dr. Saric"); Mark V. Sherrid, M.D. ("Dr. Sherrid"); Arthur Millman, M.D. ("Dr. Millman"); Chunguang Chen, M.D. ("Dr. Chen"); Aasha S. Gopal, M.D. ("Dr. Gopal"); Kenneth Ong, M.D. ("Dr. Ong"); Jeffrey G. Schwartz, M.D. ("Dr. Schwartz"); Richard Kutnick, M.D. ("Dr. Kutnick"); Nino D. Marino, M.D. ("Dr. Marino"); Shunichi Homma, M.D. ("Dr. Homma"); Louis Evan Teichholz, M.D. ("Dr. Teichholz"); Jason Lazar, M.D. ("Dr. Lazar"); William F. Lassetter, M.D. ("Dr. Lassetter"); Charles Dahl, M.D. ("Dr. Dahl"); all of whom were cardiologists. The Court considered the certifications of Eric H. Stern, M.D. ("Dr. Stern") and the certification and deposition of Dr. David E. Jacob ("Dr. Jacob"). The Court also considered the testimony of James D. Thomas, M.D. ("Dr. Thomas"), a cardiologist with expertise in the field of applied mathematics and physics and Frank Miele ("Miele"), an engineer and physicist provided during the first and fourth evidentiary hearings. Much of the direct testimony of each of these witnesses was presented through affidavits, certifications or reports which were adopted during the course of the evidentiary hearing. In addition, the Court considered the contents of several treatises which were recognized in the proceedings as reliable under **N.J.R. EVID.** 803(c)(18), including: Harvey Feigenbaum, **ECHOCARDIOGRAPHY** (5th Ed. 1994) ("Feigenbaum 5th Edition Text"); Harvey Feigenbaum, **ECHOCARDIOGRAPHY** (6th Ed. 2004) ("Feigenbaum 6th Edition Text"); Arthur Weyman, **PRINCIPLES AND PRACTICES OF ECHOCARDIOGRAPHY** (2nd Ed. 1994) ("Weyman Text"); Novin C. Nanda, **ATLAS OF COLOR DOPPLER ECHOCARDIOGRAPHY** (1989); J.P. Singh, et al., *Prevalence and Clinical Determinants of Mitral, Tricuspid, and Aortic Regurgitation (The Framingham Heart Study), Am. J. Cardiology*: 83 (1999) ("Singh"); Miguel A. Quiňones, M.D., et al.,

Recommendations for Quantification of Doppler Echocardiography: A Report From the Doppler Quantification Task Force of the Nomenclature and Standards Committee of the American Society of Echocardiography, *American Society Of Echocardiography Report,* J. Am. Soc. Echocardiography (2002); James D. Thomas, M.D., et al., *Quantification of Jet Flow by Momentum Analysis An In Vitro Color Doppler Flow Study*, *Circulation*: 81, 248 (1990); J. Geoffrey Stevenson, M.D., *Two-Dimensional Color Doppler Estimation of the Severity of Atrioventricular Valve Regurgitation: Important Effects of Instrument Gain Setting, Pulse Repetition Frequency, and Carrier Frequency*, J. Am. Soc. Echocardiography 2: 1-10 (1989); and *The Task Force on Valvular Regurgitation Recommendation for Evaluation of the Severity of Native Valvular Regurgitation with Two-dimensional and Doppler Echocardiography ("ASE Standards"),* J. Am. Soc. Echocardiography, 16: 777 (2003).

The Court previously discussed the standards to be used in assessing these eligibility challenges. *In Re: Diet Drug Litigation*, BER-L-7718-03 (Law Division April 13, 2004) ("*Eligibility Standards Opinion*") (slip op. at 31-36). Each plaintiff seeking to exercise an intermediate opt-out ("IOO") or back end opt-out ("BEOO") is required by the CAS to establish that he or she is FDA Positive by a qualifying echocardiogram. FDA Positive, as defined, contains two (2) standards. First, the quantitative measurements that constitute FDA Positive heart valve regurgitation are as follows:

> Aortic Valve – Mild or greater regurgitation, defined as regurgitant jet diameter in the parasternal long-axis view (or in the apical long-axis view, if the parasternal long-axis view is unavailable), equal to or greater than ten percent (10%) of the outflow tract diameter (JH/LVOT).
>
> Mitral Valve – Moderate or greater regurgitation, defined as regurgitant jet area in any apical view equal to or greater than twenty percent (20%) of the left atrial area (RJA/LAA).

CAS § I.22.b. The CAS also requires that specific criteria be used in determining whether these levels of valvular regurgitation are present. Singh at 897-98.

Second, the CAS requires the echocardiograms be performed and evaluated by "qualified medical personnel" in accordance with the methodology set forth in

two (2) referenced texts – the Feigenbaum 5th Edition Text and the Weyman Text. *Eligibility Standards Opinion* (slip op. at 12-16).

This Court already has determined that "Wyeth [may] disqualify an IOO or BEOO if it establishes that the performance and/or evaluation of the echocardiogram (at issue) was medically unreasonable as a matter of law. Stated another way, Wyeth "[may] . . . disqualify . . . [an] IOO or BEOO if it can show that . . . [an] expert's conclusions respecting the echocardiogram supporting the opt-out could not 'reliably flow from the facts known to the expert and the methodology used.'" *Eligibility Standards Opinion* (slip op. at 31) (citations omitted).

For the reasons which follow, the Court finds that Wyeth has satisfied the Court that the echocardiograms supporting claims of plaintiffs: Patricia Araiza, Melody Ashman, Donna Bagwell, Fayann Christensen, Debra Ellison, Marie Fillmore, Nancy Frame, Carol Frederickson, Robert Greider, Janette Harden, Nancy Harris, Oria Hays, Ryann Henry, Cherie Herold, Lisa A. Horne, Jemma Jackson, Gary C. Johnson, Ani Keleshian, Gregoria Lamb, Michelle Lindsay, Robert J. Lindstrom, Geri Lofthouse, Patsy Medel, Lucretia Mehraban, Kayleen Meikle, Matt Monica, Ann Morgan, Constance Nute, Dorothy Parks, Nikki Payne, Jean Perkins, Margaret Pitts, Lorraine Prietto, Deborah Renaud, Carol Richman, Kathy Robertson, Tryna Ross (Stallings), Patricia I. Rothe, Lorri M. Sheldon (mitral valve only), Julie Shiner, Inga Shurtz, Eva Sides, Carol A. Smith, Deborah J. Smith, Donna Spencer, Beverly Wells, and Tammie Zaccaria have not been performed and/or interpreted in a medically reasonable manner. Accordingly, the Complaints filed by these plaintiffs are dismissed and those plaintiffs are returned to the Class. The Court, however, finds that Wyeth has failed to support its eligibility challenge as to plaintiffs: Glen R. Horspool, Colleen Milchak, Cassonja Miller, Alfonso Monsivais, Lenore Nagle, Colleen Ortiz, Kerry M. Smith, and Rene D. Smith. Accordingly, Wyeth's motion to dismiss will be denied as to them. The findings of fact and conclusions of law supporting these determinations are reported below.

I

A.

In order to determine whether Wyeth's challenges have merit, one has to understand the underlying medical conditions claimed by these plaintiffs and the tools used to detect and treat those conditions. Mild aortic and moderate mitral regurgitation are the two (2) medical conditions that permit either an IOO or

BEOO. These conditions involve the backward or reverse flow of blood through defective valves during the heart's pumping cycle.

The heart consists of four (4) chambers: the right atrium, the right ventricle, the left atrium and the left ventricle. The right atrium receives deoxygenated blood from the body and ejects that blood into the right ventricle through the tricuspid valve; the right ventricle then pumps that blood across the lungs through the pulmonic or pulmonary valve for oxygenation. The oxygenated blood, in turn, is received by the left atrium, which ejects blood into the left ventricle through the mitral valve. The left ventricle then pumps that oxygenated blood into the aorta through the aortic valve, and from there to the rest of the body. The heart chambers are connected by valves that open to allow blood to pass through and then close to prevent significant backflow. This process ensures the proper directional flow of blood through the heart.

The chambers of the heart fill and empty in a two-phase cardiac cycle that comprises diastole - - the filling cycle, and systole - - the emptying cycle. For our purposes, we are concerned with the active contraction of the left ventricle and pumping of blood into the aorta through the open aortic valve during systole. Throughout this phase the mitral valve is closed to prevent backward flow or regurgitation from the left ventricle into the left atrium. We are also interested in the other phase of the cardiac cycle -- diastole -- which occurs when blood enters the left ventricle through the open mitral valve. During this phase the aortic valve is closed to prevent leakage or regurgitation from the aorta back into the left ventricle.

Healthy heart valves rarely prevent all regurgitation. When these valves are closed there may be a minimal amount of leakage -- trace regurgitation. Moreover, during routine valve closure, blood caught between the valve leaflets is displaced backward resulting in some blood backflow. This backward displacement of blood is considered part of the closing process, and is not regurgitation. According to Weyman, "true" mitral regurgitation "should last throughout most or all of systole." Weyman Text at 429. A brief or non-sustained jet of mitral regurgitation is an indication that the regurgitation is usually less than mild. The same source teaches that "true" aortic regurgitation should continue "throughout diastole." *Id.* at 529. Aortic regurgitation that is brief or non-sustained is usually less than mild.

Normally blood flows at a uniform velocity in a forward direction. This normal blood flow is laminar. Regurgitant flow, on the other hand, produces a jet

of mixed velocities which is turbulent. It is this turbulent flow which is one of the focuses of echocardiography.

According to Singh, the degree of valvular regurgitation or valvular insufficiency is classified as trace, mild, moderate, or severe. Trace aortic regurgitation and trace and mild mitral regurgitation are common in the general population and are considered normal findings. Singh at 900.

B.

Echocardiography is a principal technique used to evaluate the heart, including its function, structure and the flow of blood through it. The underlying principle involved in echocardiography is the use of high frequency sound waves. A transducer is placed on the patient's chest wall which emits sound waves that bounce off of the heart's structures, and that information is translated into moving images of those structures on a screen. There are several different techniques available in echocardiography. The technique relevant here is Doppler echocardiography. "Doppler echocardiography is based on the change in frequency of a sound wave that occurs when it strikes a moving target – in this case the red blood cells." Weyman Text at 143.

Color flow Doppler is used to display the movement of blood flow through the heart by assigning different colors depending upon the direction and velocity of the blood flow. By convention, laminar blood flowing towards the transducer is depicted in shades of red, and laminar blood flowing away from the transducer is depicted in shades of blue; darker shades indicating slower velocity and lighter shades higher velocity. *See* Feigenbaum 5th Edition Text at 33. Turbulent blood flow is depicted in a "mosaic," multi-colored pattern, thus displaying the different velocities and directions of the blood in the area under study. The absence of blood flow is depicted by black on color flow Doppler. Thus, in Doppler echocardiography blood flow is represented as discrete color areas (jets) in real time, superimposed on two-dimensional images of the heart's structure.

The quality of an echocardiogram depends on a number of factors including: the patient's body; the technical skill of the physician or sonographer performing the study; the equipment used and its settings; and, the physician's interpretation and measurements. The proper performance of an echocardiogram in the cases before this Court must follow the guidelines set forth in the Weyman and Feigenbaum 5th Edition Texts.

Settings on the echocardiographic equipment can have a substantial impact on the quality of the images and the accuracy of the recordings. Two (2) key settings on the equipment are referred to as the Nyquist limit and gain setting. The Nyquist limit establishes the maximum velocity of laminar blood flow that can be detected in a monochromatic fashion (solid color).[1] When the velocity of the blood flow exceeds the pre-set Nyquist limit, the color depicting the blood flow "wraps around" so that if the flow is laminar it appears to be flowing in the opposite direction. Turbulent blood flow in such circumstances appears as a "mosaic," multi-colored pattern. If the Nyquist limit is set too low, the velocity of normal blood flow may exceed a low Nyquist setting and will appear as turbulent regurgitation, even though it is actually normal non-regurgitant flow. Additionally, when the Nyquist limit is set too low it will exaggerate the degree of any regurgitation present by including normal blood flow velocity in the turbulent regurgitant jet area. Virtually all the experts who testified here agree that a higher Nyquist limit generally leads to a more reliable echocardiogram. A recent consensus report by the American Society of Echocardiography stressed the importance of an appropriate Nyquist limit.

> Numerous technical, physiologic and anatomic factors affect the size of the regurgitant area and therefore alter its accuracy as an index of regurgitation severity. Jet size is affected by instrument factors, especially pulse repetition frequency (PRF) and color gain. Standard technique is to use a Nyquist limit (aliasing velocity) of 50/60 cm/sec, and a color gain that just eliminates random color speckle from non-moving regions. Jet area is inversely proportional to PRF, and *substantial error can be introduced with use of higher or lower settings* than the nominal settings to which echocardiographers have become accustomed.

---

[1] As the Feigenbaum 5th Edition Text at 29 notes:

> The major disadvantages of pulsed Doppler is that the velocity one can measure is limited. The pulsed system inherently has a pulsed repetition frequency or PRF. The PRF determines how high a Doppler frequency the pulse system can detect…. The inability of a pulsed Doppler system to detect high–frequency Doppler shifts is known as "aliasing." The upper limit of frequency that can be detected with a given pulsed system is known as the "Nyquist" limit or number. This limit is defined as one half the pulse repetition frequency or PRF.

See Miele Certification at ¶¶ 16, 17, 31 and 32.

ASE Standards at 777-778 (emphasis added).

A color Doppler gain setting is another important variable in the echocardiographic system. If the gain on echocardiographic equipment is set too high, the image may be artificially increased and may also present "background noise" or "speckling," seriously degrading the quality of the echocardiogram and making it difficult to assess true regurgitation. Weyman Text at 240-241 and 258. As Weyman teaches, the "detection of the Doppler frequency shift is critically dependent on the signal/noise ratio, and every effort must be made to maximize this relationship." Weyman Text at 256. To do so, Weyman suggests that:

> Ideally, as in imaging studies, one begins with a high gain setting to be sure that all of the signal present is appreciated. The gain is then gradually decreased to a point where the signal is optimally displayed and the associated noise and mirroring artifacts … are at a minimum.

Weyman Text at 258.

Two (2) dimensional or 2-D gain settings are also significant. The 2-D gain is important in acquiring and displaying cardiac structures such as the left atrium and ventricle. If the 2-D gain is set too high, these cardiac structures are obscured as the display takes on an appearance of a snow storm. Obviously, this can be quite significant when one must trace the left atrial area in making the area measurements required by the CAS.

Another important technical aspect of echocardiographic acquisition relates to the angle the transducer is placed relative to the heart when images are recorded. If those images are not acquired in the appropriate angle or plane, the amount of regurgitation and the sizes of the chambers of the heart may appear larger or smaller than they really are. Again, Weyman teaches that "[D]oppler frequency shifts are maximal when the sound beam is parallel to the flow vector (*i.e.*, aligned parallel to the path of blood flow in the vessel of interest).… The Doppler beam, therefore, is ideally aligned parallel, rather than perpendicular, to flow because larger frequency shifts are easier to detect and the output is less subject to random fluctuation." Weyman Text at 256.

FDA Positive heart valve regurgitation involving the aortic valve requires that two (2) measurements be made: (1) the height of the jet of aortic regurgitation

("JH"); and (2) the height of the left ventricular outflow tract ("LVOT").[2] The JH measurement is the linear width of the jet of aortic regurgitation as it leaks backward into the left ventricle. Feigenbaum tells us that this measurement must be made as close as possible to the point of origin of that jet on the ventricular side of the aortic valve. Feigenbaum 5th Edition Text at 283. Otherwise, the measurement will be exaggerated by the spray or "nozzle effect" that occurs when high velocity liquid (regurgitant blood) is ejected through a narrow orifice into a lower pressure chamber (the left ventricle in diastole). *Id.* at 283. The LVOT is the region of the left ventricle below the aortic valve. These two (2) measurements are then expressed as a ratio, JH/LVOT. Current technology utilizes digitally calibrated calipers or cursors, which can measure the linear width of the JH and LVOT on a frozen frame or image using a digitally calibrated caliper or cursor, from commercially available software packages.

The definition of FDA Positive mitral regurgitation also requires two (2) measurements to be made: (1) the regurgitant jet area, or "RJA"; and (2) the left atrial area, or "LAA." Unlike the linear width measurements made of the JH and LVOT, the RJA and LAA are area measurements. Again these measurements are expressed as a ratio, RJA/LAA, in assessing the degree of mitral regurgitation. These measurements of the RJA and LAA can be done while the sonographer is

[2] The same diagram illustrating how this measurement is actually made is displayed in the Feigenbaum 5th Edition Text at 285, Fig. 6-101, and the Weyman Text at 534. The illustration as it appears in Weyman is reproduced below.

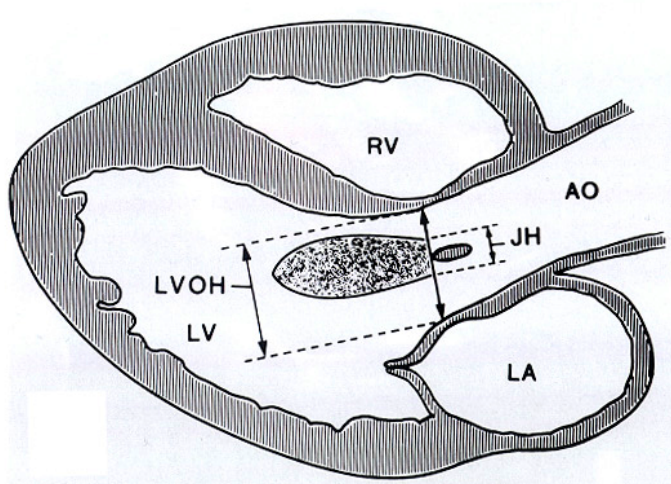

Fig. 19–61. The measurement of regurgitant jet height. Regurgitant jet height (JH) is measured at the aortic valve level in the parasternal long axis view. AO = aorta; LA = left atrium; LV = left ventricle; LVOH = left ventricular outflow tract height; RV = right ventricle. (From Perry GJ, et al.: Evaluation of aortic insufficiency by Doppler color flow mapping. J Am Coll Cardiol 9:952, 1987. Reprinted with permission from the American College of Cardiology.

acquiring the study, or off-line, and are referred to as tracings or planimetry when using the technology just described.

II

A.

The Court considered the qualifications of the experts as required by **N.J.R. EVID.** 702. *Kemp ex rel Wright v. State*, 174 N.J. 412, 427 (2002). Overall, the Court found the experts called by Wyeth and the plaintiffs to be well qualified, or at least qualified, in the areas offered.

The Court finds Drs. Goldman, Chen, Vasey, Schwartz, Stern, Teichholtz, Kutnick, Marino, Homma and Thomas well qualified in the field of echocardiography. Dr. Thomas is also an expert on the theory of echocardiography and its mathematical expression. Dr. Goldman is a Professor of Medicine at the Mt. Sinai School of Medicine in New York and has taught at that medical school for over twenty (20) years. Dr. Goldman has written extensively in the field of echocardiology, holds positions as a director of the American Society of Echocardiography ("ASE"), one of the bodies seeking to promote advances in the field of echocardiography, and serves on several of its committees. He is the immediate past President of the New York Echocardiography Society. Dr. Chen is a Clinical Professor of Medicine at the Mt. Sinai School of Medicine in New York and is the Director of the Cardiac Non-Invasive Laboratory at the Newark Beth Israel Medical Center. He has published extensively in the field of echocardiography and is a Level III echocardiographer. Dr. Vasey is the Director of Noninvasive Services of Asheville Cardiology Associates, P.A. in Asheville, North Carolina. He is a Clinical Professor of Medicine at the North Carolina School of Medicine. He reads several thousand echocardiograms in his practice and is a Fellow of the ASE. He presently serves on the board of the ASE, as well as its operating committees. Dr. Schwartz currently serves as Director of the Echocardiography Laboratory of Morristown Cardiology Associates. He is board certified in internal medicine, cardiovascular medicine, echocardiography, and nuclear cardiology. He is both a practicing cardiologist and designated teaching service attending at Morristown Memorial Hospital. Dr. Stern is an Associate Professor of Medicine at the Mount Sinai School of Medicine in New York City and is Co-Director of the Echocardiography Laboratory at the Mount Sinai Hospital. Dr. Stern also served as Chief of the Echocardiography Laboratory at the Bronx VA Medical Center between 1984 and 1998. Dr. Teichholz is currently the Chief of the Division of Cardiology in the Department of Internal Medicine and the

Medical Director of Cardiac Services at the Hackensack University Medical Center. He is presently a Professor of Medicine at the University of Medicine and Dentistry of New Jersey and an adjunct Professor of Medicine at the Mount Sinai School of Medicine. Dr. Teichholz has been active in the field of echocardiography for thirty (30) years, particularly as this science was being developed, and has served on the board of the ASE. Dr. Marino is an attending physician at Lenox Hill Hospital in New York City specializing in cardiology, with a subspecialty in echocardiography. He has also maintained a supervisory position in the Echocardiography Laboratory at that hospital for over twenty (20) years and has been Chief of that laboratory for approximately twelve (12) years. Dr. Homma is a board certified cardiologist and Director of Adult Echocardiography Laboratories at Columbia University. He is the Margaret Milliken Hatch Professor of Cardiology and is the Associate Chief of the Division of Cardiology at the College of Physicians & Surgeons of Columbia University. Dr. Homma is current Vice President of the New York Echocardiography Society. Dr. Kutnick is Assistant Chief of the Division of Cardiology at Lenox Hill Hospital in New York. He has held that position for over twenty (20) years. He is also a Clinical Assistant Professor of Medicine at New York University Medical Center. Dr. Kutnick is a Level III echocardiographer, board certified in internal medicine and cardiovascular disease. Dr. Thomas is presently the Section Head for Imaging within the Department of Cardiovascular Medicine at the Cleveland Clinic Foundation. Dr. Thomas also is a Professor of Medicine and Biomechanical Engineering at the Ohio State University and an Adjunct Professor of Medicine and Biomechanical Engineering at Case Western Reserve. Dr. Thomas also is the Head Scientist for Ultrasound at the National Aeronautics and Space Administration ("NASA") and has advised that agency on the use of ultrasound in manned space flight. He graduated from Harvard University *summa cum laude* in applied mathematics and physics and from Harvard Medical School. He authored Chapter 12 in the Weyman Text entitled "Fluid Dynamics of Regurgitant Jets and Their Imaging by Color Doppler" and has written well over 700 articles in the fields of Cardiology and Echocardiography, among others. Copies of the curricula vitae of these ten (10) physicians are part of the hearing record.

The plaintiffs, too, produced qualified witnesses. Dr. Lazar is a board certified cardiologist with Level III echocardiographic training. He is currently an Echocardiography Attending Physician at New York Hospital in Queens and the Director of Non-Invasive Cardiology and Associate Director of Cardiovascular Training at the Medical Center at SUNY-Brooklyn (Downstate Medical Center). Dr. Lassetter is a Level II cardiologist in private practice in Utah. He is board certified in internal medicine, cardiology and interventional cardiology. Dr. Dahl

is a board certified cardiologist and a Level II qualified cardiologist licensed to practice clinical cardiology. Dr. Dahl, a Fellow of the American College of Cardiology, has been Co-Director of the Echocardiography Lab at Utah Valley Regional Medical Center since 1996, and is Vice President of Central Utah Medical Clinic. Dr. Jacob has level III training in echocardiography and is board certified in internal medicine, cardiology, and nuclear cardiology. While privately practicing clinical and noninvasive cardiology in New Jersey, Dr. Jacob also acts as a Clinical Assistant Professor in the Department of Medicine at Robert Wood Johnson Medical School. He also serves as Chief of Cardiology and Director of both the Echocardiography Lab and Nuclear Cardiology Lab at St. Peter's University Hospital. Miele is an engineer with training in physics and echocardiographic machine design.[3] Miele helped design echocardiographic equipment while at Hewlett Packard Corporation and presently has his own consulting business. He teaches physicians and technicians how to use echocardiographic equipment. The curricula vitae of these experts also are included as part of the record.

The expert cardiologists appointed by the Court under the terms of the *Eligibility Standards Opinion* also are well qualified. Dr. Saric is presently the Director of the Echocardiography Laboratory at the University of Medicine and Dentistry of New Jersey and has Level III echocardiographic training. In addition to his M.D. degree and board certifications in cardiology and echocardiography, Dr. Saric holds a PhD in medical sciences from New York University. Dr. Sherrid is presently the Director of the Echocardiography Laboratory at St. Luke's Roosevelt Hospital Center and serves as an Associate Professor of Clinical Medicine at the Columbia University College of Physicians and Surgeons. He is the President of the New York Echocardiography Society. Dr. Gopal is the Director of Echocardiography at St. Francis Hospital, Roslyn, New York and is an Associate Professor of Medicine at SUNY (Stonybrook, New York). She is a Level III echocardiographer and has published in the field of echocardiography. Dr. Ong is the Acting Chief of Cardiology and the Director of the Cardiac Non-Invasive Imaging Laboratory at the Brooklyn Hospital Center. He is a Level III echocardiographer and has published in the field of echocardiography. Dr. Millman is the Chief of Cardiology at Trinitas Hospital in Elizabeth, New Jersey. He has had extensive experience in echocardiography and teaches cardiology

[3] Mr. Miele provided general information about the laws of physics governing echocardiography and the equipment used in its practice during the Group I and II hearings. He also provided specific information on Nyquist limits and the effect of transducer angles on color Doppler. As noted later in this Letter Opinion, the Court found Mr. Miele quite knowledgeable in these areas and the Court has referred to his submission in this Letter Opinion. Mr. Miele's resume is part of the record.

fellows from the Seton Hall Graduate School of Medical Education. The curricula vitae of these experts also are part of the record.

B.

As in the past, the Court's decisions in these individual eligibility cases are based largely on the quality of the echocardiograms. The initial reports of physicians with respect to virtually all these challenged echocardiograms have significantly overstated the pathology observed and/or claimed that the echocardiograms were of good diagnostic quality when they clearly were not. Accordingly, as in the eligibility hearings on the Group 1, Group 2, Group 3, Group 4 and Group 5-6 plaintiffs (*see Armstrong et al v. Wyeth, Inc.*, (BER-L-7024-03MT); *Comparato et al v. Wyeth, Inc.,* (BER-L-332-04); *Andrade, et al v. Wyeth, Inc.*, (BER-L-1502-04MT); *Adeyemo et al v. Wyeth, Inc.,* (BER-L-1396-04MT) (Letter Opinions dated August 4, 2004, slip op. at 10-12; dated September 22, 2004, slip op. at 14-15; dated December 9, 2004, slip op. at 16-18; and dated February 24, 2005, slip op. at 18-24), and *Adamson et al v. Wyeth, Inc.,* (BER-L-2997-04MT) (slip op. at 15-22; dated May 6, 2005, amended May 9, 2005), the plaintiffs' experts spent much of their time seeking to excuse and explain these overstatements and/or the poor technical quality of the echocardiograms.

In many instances here, as in the past, color Doppler gains and/or 2-D gains were set so high that the entire color box was filled with artifact and/or the 2-D images obscured. If valvular regurgitation was present, it could rarely be identified and could never be reliably quantified. In spite of these defects, Drs. Lassetter, Jacob, Lazar and Dahl excused the gain settings by saying that either the color speckling was not evident or, if it was, it did not affect their conclusions.

In other instances, Nyquist limits as low as 41 cm/sec, well below the Nyquist limits outlined in the *ASE Standards* at 777-778 (50-60 cm/sec) and in the Weyman Text at 245 (60-90 cm/sec), appeared in echocardiograms supporting the opt-outs. The low Nyquist settings sometimes appeared in conjunction with high color gain settings, further compounding the problem. In the face of such obvious deviations from proper echocardiographic practice, Drs. Lassetter, Jacob, Lazar and Dahl as well as Miele were left to opine that the capacity of this low Nyquist limit to inflate any observed regurgitant jet was significantly overestimated by Wyeth's and the Court's appointed experts or were overwhelmed by angle effects where views were taken in the PLAX view. It was also claimed that some of the echocardiograms here were "technically difficult" because, in some instances, obese plaintiffs required greater probe depths thus lowering the Nyquist. But as

will be seen later in this Letter Opinion, these unacceptable Nyquists often resulted from the technicians failing to properly adjust the Nyquist limit upward as examinations were conducted. As it turns out, the Accuson Cypress echocardiogram machine was used for the bulk of these echocardiograms. That machine does not automatically adjust the Nyquist limit upward when returning from lower probe depths. Dr. Michael S. Mancina ("Dr. Mancina"), an expert called by the plaintiffs and appearing in the Group 5-6 hearings, put it this way:

> THE WITNESS: [The Cypress machine] ... does have limitations. I can name them, if you like[.] [I]t has limitations, as all machines do.
> JUDGE WALSH: I would like you to name them.
> THE WITNESS: Okay. We find that it doesn't have high PRF and that can limit the pulse Doppler frequencies that you can obtain. It has some features that we have to train our sonographers to deal with, which is *it registers a Nyquist limit and doesn't change automatically from patient to patient; even from one moment in the study to the next moment. So sonographers have to be trained and have to be attentive to the Nyquist limit that is being used*, because that's an important consideration in doing ultrasound.
>
> *And, so, if there is not an automatic change, the sonographer has to make that change. And that's different than most machines.* Those are the two major considerations, but they are certainly workable and we've taught all our sonographers about them.... (Emphasis added.)

The Court finds that Dr. Lassetter's assertion that he regularly uses Nyquist limits in the 40 cm/sec range not to be credible.[4] Dr. Lassetter indicated in prior

---

[4] Dr. Mancina, the expert called by the plaintiffs during the Group 5-6 hearings, also claimed to regularly use Nyquist limits in the 40 cm/sec range. But his testimony was belied by guidance memoranda written in 2002 and 2003 and given to the sonographers working on some 20,000 phen-fen cases with him. Dr. Mancina directed sonographers to:

> ***Never*** test with a color scale [Nyquist limit] of less than 51 [cm/sec] (preferably test in the range of 60's).
>
> * * * *
>
> ***Do not ever*** use a color scale [Nyquist limit] of less than 51. Show the jet primarily in live motion and replay in live motion, rather than clips stored of the jet. (Emphasis added.)

testimony in these Eligibility Hearings that while he would occasionally have to use Nyquist limits in the high 40's cm/sec range, it was dictated by the patient's body habitus. In every case where inappropriate Nyquist limits were used, they could have been adjusted to over 50 cm/sec -- the least acceptable Nyquist limits identified in the *ASE Standards*. Dr. Lassetter also asserted that an article, Keepak Khonna, et al, *Quantification of Mitral Regurgitation by Live Three-Dimensional Transthoracic Echocardiographic Measurements of Vena Contracta Area*, Echocardiography: 21: 727 (2004), supported his position that Nyquist limits of 40 cm/sec to 50 cm/sec did not cause a significant enlargement of a regurgitant jet. Figure 1 of the article indicated that the vena contracta area did not significantly change in the 40 cm/sec to 60 cm/sec range in a group of five (5) patients. The article, in the Court's view, provides no support to Dr. Lassetter's claim. Regurgitant jet flows were not being measured. Moreover, the sample size of five (5) is too small to draw any conclusions even if regurgitant jets were being measured.

The Court also rejects Dr. Jacob's application of gain setting criteria to the evaluation of the echocardiograms he reviewed here. Dr. Jacob, by and large, agrees with the view that gain settings should be raised until speckling is seen and then lowered to the point where the speckling disappears. Dr. Jacob put it this way:

> Q. Now, you mentioned gain settings. Is that something you actually see in the Settlement Agreement or is that something that you applied through the Feigenbaum and Weyman texts?
> A. That's something that is applied through the texts.
> Q. Since you brought us to that subject, could you describe to the court, in your view, what is an appropriate gain setting?
> A. Well, the appropriate gain setting would be that there isn't a significant amount of noise throughout other -- speckling pattern throughout other areas of the echocardiogram. And in final analysis, the echocardiogram would be diagnostic for what you are looking for.

The Nyquist settings articulated by Dr. Mancina are in accordance with the *ASE Standards* and the Weyman Text. This plainly indicates what Dr. Mancina's clinical practice was in 2002 and 2003. His present testimonial claims in light of these memoranda plainly are entitled to little or no weight.

> Q. And can you describe generally what is your understanding of the appropriate procedure for calibrating or arriving at the right gain setting.
> A. The gain would be increased so that noise would appear in a background. And then it would be dialed down to an optimal level so that you can see that regurgitant jet, while not seeing a lot of extraneous noise.
> Q. Is that something that you take from the Weyman text that's referenced in the Settlement Agreement?
> A. Yes.

Dr. Jacob also generally subscribes to the general teachings on Nyquist limits though he believes that lower Nyquist limits may be necessary where a patient's body habitus requires it. In that regard, he says a Nyquist limit below 50 cm/sec range may be acceptable.

> Q. With regard to the issue of Nyquist, Doctor, do you have an understanding of the 2003 NEC guidelines for Nyquist?
> A. Yes.
> Q. And what are those, Doctor?
> A. They prefer the Nyquist settings to be between 50 and 60.
> Q. Is it possible, in your opinion, to have a diagnostic quality echocardiogram with a Nyquist below 50?
> A. Yes.
> Q. And could you just describe to me and to the court generally when it can be that you can have a diagnostic quality echo with an Nyquist below 50.
> A. Well, I mean, it would depend on the individual echocardiogram and individual patient and body habitus. You would have to see the echocardiogram to see if it's diagnostic, you know, for what you are looking for.

However, it is apparent that Dr. Jacob abandoned those principles in his review of the echocardiograms here. In most of the cases he reviewed here, gain settings were excessive and in one instance the gain was set at 24 on an Accuron

Cypress machine,[5] the highest gain setting the Court has seen in these hearings. Despite these high gain settings, Dr. Jacob claimed to be able to detect valvular regurgitation. However, as will be seen, in most of these instances spectral Doppler was available and failed to confirm the regurgitation claims. Dr. Jacob's solution to this dilemma was to reject the CW Doppler in every case as poorly done. As to the low Nyquist limits, it was evident that the Nyquist limits could have been raised on the studies in issue here so as to reach acceptable readings if the technician chose to do so. Thus, Dr. Jacob's point that body habitus could play a role, even if a justification for accepting a Nyquist limit lower than 50 cm/sec, is not relevant here.

Finally, plaintiffs' broader attacks on standard setting for parameters such as Nyquist limits lack credibility as well. Miele challenged the mathematical underpinnings for the claim that low Nyquist limits can significantly affect the apparent area of a regurgitant jet. In his view, while the mathematics plainly support the claim that as a Nyquist limit falls the regurgitant jet area enlarges at an increasing rate, the formula is useless in real world situations.[6] Miele believes that there are simply too many variables in the real world -- *in vivo* -- to accept that these mathematical truths are applicable.

The Court rejects Miele's claims that Nyquist limits are nothing but a function of clinical judgment. Instead, it accepts Dr. Thomas' testimony that low Nyquist limits have a significant distorting effect on regurgitant jet area measurements. Dr. Thomas acknowledges that "chamber constraint, coflow, orifice irregularity, unsteady flow and spatial, temporal, and velocity resolution issues in the ... [echocardiographic machine]" may also influence regurgitant jet

---

[5] Dr. Mancina previously testified in the Group 5-6 Eligibility Hearing. Dr. Mancina extensively used the Accuson Cypress echocardiography machine. Many of the echocardiograms here used the same equipment. Dr. Mancina supervised the performance of approximately 20,000 echocardiograms in connection with efforts to opt-out of the CAS and for other purposes in the phen-fen litigation. In providing guidance to the echocardiographic sonographers working on this project, Dr. Mancina specifically addressed proper gain settings. In two (2) memoranda written in 2002 and 2003, he reminded the sonographers on the phen-fen project that they "*[a]lways* [should] use gains in the range of 6-11 for color gain" on the Cypress echocardiographic machine. (Emphasis added.) He further cautioned: "Be sure your color gains are not set too high (go up to the point where the color gain causes a spark in the soft tissue and then decrease it so there is no soft tissue color)."

[6] Miele himself accepted the theoretical physics that a decreasing Nyquist limit caused the regurgitant jet area to increase at an increasing rate.

> JUDGE WALSH: Does a decreasing Nyquist, all things equal, cause the regurgitant jet area to enlarge at an increasing rate:
> THE WITNESS: Yes, it does. In fact, that's one of the first points I made this morning, that I agree with that premise.

size. Nevertheless, he was clear that as Nyquist limits decrease, jet area size increases at an increasing rate.

Dr. Thomas put it this way:

> As I derived in my 1991 *Circulation* manuscript, for an unconstrained axisymmetric jet, jet area should rise as the inverse square of the low-velocity cut-off (generally a percentage of the Nyquist limit, whether this is based on discretization criteria or wall-filter criteria, since both are tied to the Nyquist limit in practical terms). This would produce a strongly curvilinear increase in jet area with falling Nyquist. It should be emphasized that the vast majority of jets under consideration in the Fen Phen litigation are indeed unconstrained, or "barely" constrained, in that they do not come anywhere near filling the receiving chamber, be it the left atrium for mitral regurgitation or the left ventricle for aortic regurgitation. Therefore, we anticipate the inverse of the first power of the low-velocity cut-off, this would still present a curvilinear increase in jet area with falling Nyquist velocity, as the second derivative of $1/x$ is $2/x^3$, which remains strongly curved upwards (positive curvature) as it approaches 0 velocity. (*A perhaps simpler way of seeing this is to note that if jet area is proportional to 1/Nyquist velocity, then going from 60->50 cm/sec leads to a 20% increase in jet area, while going from 50->40 cm/sec leads to a 25% increase in an already enlarged jet area, thereby confirming that it grows faster and faster as Nyquist falls.*) As to the issue of whether the increase in jet area when lowering Nyquist ever flattens out, this is only a possibility with much larger jets that are coming close to filling the receiving chamber. Clearly, a jet can grow no larger than the chamber into which it is flowing, no matter how low the Nyquist velocity. So for very severe regurgitation, we would indeed expect that jet area would rise with lowering the Nyquist limit, but would eventually flatten out and ultimately level out at the full size of the left atrium or left ventricle. (Emphasis added.)

Dr. Thomas' observations, which are supported by science and the scientific community, make it abundantly clear that Nyquist limits in the 40 cm/sec to 49 cm/sec range significantly distort and enlarge regurgitant jet areas and should not be accepted by the Court.

The Court finds that in many instances the techniques used in acquiring the echocardiographic images presented here fell so far below appropriate practice as to make the data reported and conclusions made by plaintiffs' experts virtually worthless in either diagnosis or treatment. With respect to the fifty-five (55) plaintiffs included in this Letter Opinion, the experts appointed by the Court concluded that with respect to fifty-one percent (51%) of them, the echocardiograms were so technically inadequate that reasonable medical conclusions could not be drawn from them.

Plaintiffs were aware that the qualifying echocardiograms in issue would be used to support the opt-outs sought. As will be seen, however, in the fifty-five (55) cases reviewed here, many of the submitted echocardiograms were of such poor quality or were interpreted in a manner so plainly at odds with good medical practice that they cannot, as a matter of law, support those plaintiffs' claims to qualify as FDA Positive. Overall, the experts appointed by the Court opined in seventy-eight percent (78%) of the cases that the FDA Positive mitral or aortic regurgitation determinations made by the plaintiffs' experts were not medically reasonable.

The findings with respect to the fifty-five (55) plaintiffs follow in the next section of this Letter Opinion. Where credibility determinations in these individual cases are made, they are reflected in the findings reported below.

III

A. PATRICIA ARAIZA

Araiza relies on a December 12, 2002 echocardiogram and report of Dr. Robin S. Freedberg. Dr. Freedberg found that Araiza had moderate mitral regurgitation ("MMR") and mild aortic regurgitation ("MAR") using CAS criteria -- RJA/LAA = 22%; JH/LVOT = 14%. Dr. Freedberg noted that the study quality was "good."

The December 12, 2002 echocardiogram was reviewed by three (3) experts: Dr. Chen, Dr. Gopal and Dr. Lassetter. Both Drs. Gopal and Chen found that this

echocardiogram was not conducted in a technically adequate manner such that reliable medical conclusions regarding the presence and severity of valvular regurgitation could be drawn from it. According to Dr. Gopal, "color gain was excessive (see speckling and color mosaic noted in image 7). Here, jet thickness and jet areas would be overestimated." Dr. Chen concurred also noting the marginal Nyquist limit of 51 cm/sec. The gain settings on this Accuson machine ranged from 13 to 17. Dr. Lassetter disagreed. According to him, while the gain settings were high, the echocardiogram was interpretable.

Both Drs. Gopal and Chen concluded that the echocardiogram failed to establish that Araiza had either MMR or MAR. As to the MMR claim, Dr. Gopal noted that

> [c]olor gain was excessive and traced jet areas were overestimated by an amount that cannot be determined exactly. Mitral regurgitation does not appear to last for more than 2 videoframes - not holosystolic. It appears to be only trace or mild and not moderate. The traced jet areas included low velocity closing volume components that should not be traced.

Dr. Chen concurred.

Both Drs. Gopal and Chen agreed that this echocardiogram did not demonstrate MAR either. Dr. Gopal found that

> [e]ven accounting for excessive color gain, there is only trace aortic regurgitation. The jet cannot be clearly seen in apical views either. Mild aortic regurgitation if present, can usually be seen in both views.

Again Dr. Chen concurred though he specifically found that there was no "definite" aortic regurgitation in the PLAX view.

Dr. Lassetter disagreed on both scores. He viewed the echocardiogram as a "good" quality study though with high gains. According to Dr. Lassetter, Araiza has MMR which can be seen in the apical 4 views and in an apical 2 view. Dr. Lassetter provided measurements which show MMR at 23%. As to the aortic regurgitation claim, Dr. Lassetter found it in the PLAX views and identified it as 16%.

The Court finds that Wyeth has satisfied its burden to show that this echocardiogram was not conducted in a technically adequate manner such that reliable medical conclusions regarding the presence and severity of valvular regurgitation could be drawn from it. Moreover, to the extent any of Araiza's claims may be reliably examined, it adopts Dr. Chen's criticisms of Dr. Lassetter as its own.

> Dr. Lassetter relies on images on Pages 8, 9, 10, and 11 of the DICOM for his conclusion that there is mild AI present on this study. He asserts that he made JH/LVOT measurements of 0.35/2.2 (16%) on Pages 8-11. I have re-reviewed the study in its entirety, with particular attention to these pages.
>
> On Page 8, in one of 3 cardiac cycles, there is a tiny color cluster with the appearance of an AR jet that lasts 4 of 8 frames of diastole. Thus it is not a holodiastolic phenomenon, but rather a half-diastolic non-continuous or broken AR jet, if anything. I have doubts about the certainty of this as an aortic regurgitant jet because of high color Doppler gain on this study that can produce strange artifacts that can mimic AR at times. Typically, an AR jet starts in early diastole before the mitral valve opens, an important differentiation point from the flow in the LVOT due to the opening excursion of the anterior mitral leaflet. The color cluster that appears only in one of the cardiac cycles on this Page of the DICOM started 3 frames after diastole began, or about 110-120 ms into diastole, when the mitral valve already has opened. Therefore, it is only a suspicious, broken AR jet. At any rate, due to high color Doppler gain settings, JH measurement, or JH/LVOT ratio, overestimates the degree of aortic regurgitation and prevents reliable assessment of degree of aortic regurgitation in this study. Reliable measurements cannot be made, but Dr. Lassetter relied on the technician's improper selection and measurements of JH.
>
> On Page 9 of a still frame image, the technician measured a homogenous low velocity color cluster which is not a

typical regurgitant mosaic color with turbulent flow. Furthermore, electrical cursors were placed too far into the LVOT, not just below the aortic valve and not on the posterior and anterior edges of the jet, even assuming that the color cluster were a jet. Just for demonstration, to show what is a color cluster that is suspicious for an AR jet in this study as mentioned earlier, and to show proper measurement of the jet height of an AR jet, I selected the largest, suspicious "AR" jet and performed JH/LVOT measurements on Page 8. Even with high color Doppler gain settings that exaggerate regurgitant jet size, JH/LVOT is still measured within the trace AR range. The JH was 0.22 cm on frame 14/49 (Exhibit 1). The LVOT was 2.32 cm on frame 14/49 (Exhibit 1), for a JH/LVOT ratio of 9.48% if it were an AR jet.

On Page 10, there is no AR jet visualized in real-time images. On Page 11, the technician measured a color cluster that is in early systole on the EKG tracing, after the peak of the R wave, and thus is not an AR jet.

Dr. Lassetter relies on images on Pages 31, 32, 34, 36, 38, and 66 of the DICOM for his conclusion that there is moderate MR present on this study. He asserts that he made RJA/LAA measurements of 5.6/24.1 (23%) on Page 38. I have re-reviewed the study in its entirety, with particular attention [to] these pages.

I find that on Pages 31, 32, 34, 36, and 66, the MR jet only lasted 2-3 frames of 8-9 systolic frames, appearing in early systole in real-time images. The early systolic jet is exaggerated by high color Doppler gain settings and a relatively low Nyquist velocity (51 cm/s[ec]). I would not have measured this very briefly lasting jet for quantification of mitral regurgitation for two reasons: the high color Doppler gain settings and the non-holosystolic nature of the jet. Obviously, high color Doppler gain exaggerates jet size but even this appearance cannot make the exaggerated small jet last longer.

> The measurement on Page 38 that was relied on by Dr. Lassetter is improper. The MR jet is overtraced significantly as the electronic cursor is far beyond the jet borders. In addition, the color cluster is in very early systole, without a proximal acceleration region, indicating the possibility of exaggerated backflow during mitral valve closure. Nevertheless, for demonstration purposes only, I traced the color cluster and its area is 4.17 cm^2 (Exhibit 2). If the LAA measurement by the technician were to be used, the "RJA"/LAA would be only 17%.

B. MELODY ASHMAN

Ashman relies on an October 9, 2002 echocardiogram and report of Dr. Edward S. Katz. Dr. Katz found that Ashman had neither MMR nor MAR using CAS criteria. Dr. Katz calculated a RJA/LAA = 13% using CAS criteria. The study quality was judged to be "fair."

The October 9, 2002 echocardiogram was reviewed by three (3) experts: Dr. Schwartz, Dr. Gopal and Dr. Lassetter. Both Drs. Gopal and Schwartz found that the echocardiogram was not conducted in a technically adequate manner such that reliable medical conclusions regarding the presence and severity of valvular regurgitation could be drawn from it. Dr. Schwartz's comments summed up the criticisms of this study when he noted that "[t]he color Doppler gain is too high to interpret, particularly with the borderline Nyquist limit of 51 cm/sec."

Dr. Lassetter disagreed. He found that Ashman has "at least mild to moderate AI." Dr. Lassetter noted that the "gain setting was high" and the overall quality was "fair." Dr. Lassetter did not attempt to quantify the aortic regurgitation beyond calling it mild to moderate nor did he evaluate it in the PLAX view. He claimed it was not diagnostic.

Both Drs. Gopal and Schwartz disagreed that Ashman has MAR. Dr. Gopal put it this way:

> Parasternal views do not show aortic regurgitation. Apical views show only trivial aortic regurgitation as the sonographer who performed the study indicates. No jet

> height ratios are provided to substantiate claims of mild aortic regurgitation.

Dr. Schwartz concurred, finding "no [aortic regurgitation] in the PLAX view."

The Court finds that Wyeth has easily established that this echocardiogram was not conducted in a technically adequate manner such that reliable medical conclusions regarding the presence and severity of valvular regurgitation could be drawn from it. Moreover, there is a serious question as to whether Ashman's opt-out was valid in the first place given the echocardiogram and report of Dr. Katz. Finally, the Court is satisfied that to the extent the echocardiogram has any diagnostic value, no reasonable physician could conclude it supports a MAR claim.

C. DONNA BAGWELL

Bagwell relies on a December 2, 2002 echocardiogram and a report of Dr. Scott L. Roth. Dr. Roth found Bagwell had MMR using CAS criteria -- RJA/LAA = 20%. Dr. Roth indicated that the study had "limited windows" and the plaintiff had "[d]ilated left atrium."

The December 2, 2002 echocardiogram was reviewed by three (3) experts: Dr. Chen, Dr. Gopal and Dr. Lassetter. Both Drs. Gopal and Chen found that this echocardiogram was not conducted in a technically adequate manner such that reliable medical conclusions regarding the presence and severity of valvular regurgitation could be drawn from it. Dr. Gopal noted:

> Though Nyquist limits are adequate (in some apical views - see image 48, Nyquist limits of 51 cm/s[ec] are just barely acceptable), color gain is very high - note speckling over the apex in image 36. Hence overestimation of jet area is present.

Dr. Chen concurred. The Court reviewed this echocardiogram and notes it was done on an Accuron machine with gain settings between 20 and 23 -- extremely high gain calibrations.

Dr. Lassetter found Bagwell's echocardiogram to be of "good" diagnostic quality with "good" gain settings. The Court finds that Dr. Lassetter's opinion as to the echocardiogram's technical quality lacks credibility.

Both Drs. Gopal and Chen found that to the extent this echocardiogram can be used to make any evaluations, it fails to show moderate mitral regurgitation. Dr. Gopal noted:

> Many of the traced jet areas included low velocity non-turbulent laminar flow components. Image 48 comes close. However, jet area is still overtraced and includes some cavitary areas as well. In addition, left atrial the left atrial area determine in image 34 shows underestimation of left arial (sic) [atrial] area particularly in the region of the right superior pulmonary vein. Both will tend to overestimate jet area.

Dr. Chen concurred.

Dr. Lassetter again disagreed, finding an RJA of 5.1 cm^2 and an LAA of 25.2 cm^2 which computes to 20.2% -- barely enough to qualify as MMR. The Court rejects this calculation, finding that the RJA was vastly overtraced. The Court believes an RJA of 3.53 cm^2 measured by Dr. Chen is far more accurate, if indeed, it would ever be appropriate to make measurements here. Using that measurement, the RJA/LAA = 14%.

The Court finds that Wyeth has established that this echocardiogram was not conducted in a technically adequate manner such that reliable medical conclusions regarding the presence and severity of valvular regurgitation could be drawn from it. In any case, Wyeth has demonstrated that even if this echocardiogram was accepted as technically adequate, no reasonable physician could conclude, based on its review, that Bagwell has MMR.

D. FAYANN CHRISTENSEN

Christensen relies on a December 9, 2002 echocardiogram and a report of Dr. Scott L. Roth. Dr. Roth found Christensen had MAR using CAS criteria -- JH/LVOT = 15%. Dr. Roth noted that this was a "[t]echnically adequate study."

The December 9, 2002 echocardiogram was reviewed by three (3) experts: Dr. Chen, Dr. Gopal and Dr. Lassetter. Dr. Gopal found that this echocardiogram was not conducted in a technically adequate manner such that reliable medical conclusions regarding the presence and severity of valvular regurgitation could be drawn from it. She observed that the "[c]olor gain is excessive." Dr. Chen

concurred that the color gain settings were high, "particularly in the PLAX view," but believed the study could be interpreted "to exclude FDA positive regurgitation." This study was done on an Accuson Cypress machine with a color gain setting of 12 and a very high 2-D gain of 9.

Dr. Lassetter disagreed. According to him, this echocardiogram was a "good quality" study with "adequate gain." Dr. Lassetter noted aortic regurgitation in the PLAX view as well as the apical three-chamber view ("A3C") and the apical five-chamber view ("A5C"). Dr. Lassetter measured a JH of .3 cm and a LVOT of 2 cm, yielding a JH/LVOT of 15%.

Both Drs. Gopal and Chen disagreed with Dr. Lassetter's assessment. In Dr. Gopal's view,

> [t]he only moving images were 10, 12 and 13 which were off-axis parasternal views in which the aortic root is not completely visualized. These images show only trivial aortic regurgitation lasting no more than 1 or 2 videoframes. No consistent aortic regurgitant jet is noted. The still frames from which measurements were taken were frozen on the R wave and may have included some systolic flow as well. In addition, the jet height would have been overestimated due to high color gain.

Dr. Chen concurred and further noted:

> On Page 11, Dr. Lassetter measured a still frame color cluster that cannot be confirmed as an AR jet since there is no AR jet that lasts at least the majority of diastole in the PLAX view. In addition, Page 11 is not a standard PLAX view, but rather a transitional view between the PLAX view and the short-axis view.
>
> On Page 13, there is an oblique parasternal short-axis view of the LVOT with an unsteadily-held transducer and changing scanning planes. With high color Doppler gain, there is a tiny, suspicious broken AR jet on Page 13 which cannot be differentiated from high gain artifact. This view is not the one required by the settlement criteria for evaluating the degree of AR.

The Court finds that Wyeth has established that this echocardiogram was not conducted in a technically adequate manner such that reliable medical conclusions regarding the presence and severity of valvular regurgitation could be drawn from it. Moreover, looking at the merits, and for the reasons stated by Drs. Gopal and Chen, Wyeth has established that no reasonable physician could conclude that Christensen has MAR based on a review of this echocardiogram.

E. DEBRA ELLISON

Ellison relies on a November 21, 2002 echocardiogram and a report of Dr. Stanley S. Schrem. Dr. Schrem found that Ellison had moderate aortic regurgitation ("MMAR") using CAS criteria -- JH/LVOT = 29%. Dr. Schrem noted that the study's quality was "fair."

The November 21, 2002 echocardiogram was reviewed by three (3) experts: Dr. Teichholz, Dr. Gopal and Dr. Lassetter. Dr. Gopal found that this echocardiogram was not conducted in a technically adequate manner such that reliable medical conclusions regarding the presence and severity of valvular regurgitation could be drawn from it. She found the "color gain was excessive." Dr. Teichholz agreed the gain setting was "somewhat elevated," but "it could still be interpreted" to rule out aortic regurgitation.

Dr. Teichholz found no evidence of "true" aortic regurgitation and observed:

> No flame-shaped jet of aortic regurgitation is seen on any frames of this study. The only "aortic regurgitation" traced was from still frames that are not representative of what is seen in the motion loops. The "aortic regurgitation" traced appears to be noise with timing only in late diastole (near the P-wave). This study does not demonstrate true aortic regurgitation.

Dr. Gopal thought that there was no evidence of a "holodiastolic jet" and any jet noted was "consistent with trivial aortic regurgitation."

Dr. Lassetter disagreed. In his view, Ellison has MMAR which is confirmed in both the PLAX and A3C views. Dr. Lassetter measured a JH of .65 cm and a LVOT of 2.1 cm, which computes to 31%. As indicated during the proceeding, the Court found the JH measurement of .65 cm to be incredible. The Court agrees

with Dr. Teichholz's criticisms of this measurement and adopts them as its findings.

> It would be medically unreasonable to diagnose Ms. Ellison with mild or greater aortic regurgitation. The elevated color Doppler gain settings, as well as the Nyquist limit of 51 cm/sec, create significant noise and artifact on this study. Regardless, aortic regurgitation can be ruled out.
>
> Dr. Lassetter cited to Pages 70 and 73 in support of his opinion that moderate aortic regurgitation is present on this echocardiogram. On these Pages only a few frames of color are seen near the aortic valve very late in diastole when the EKG tracing is on the P-wave (see for example Page 70, Frames 23-25), but even this phenomenon is not consistently seen on different cardiac cycles. These Pages also include significant amounts of noise and artifact.
>
> Dr. Lassetter relies on a JH/LVOT ratio of .65/2.1 yielding 31%. This "JH" measurement shown on Page 71 is exaggerated by at least a factor of 3, as it is not traced at the origin of the "jet," is measured off-angle, and includes laminar blue low velocity flow and static black blood in the tracing.

The Court finds that Wyeth has established that this echocardiogram was not conducted in a technically adequate manner such that reliable medical conclusions regarding the presence and severity of valvular regurgitation could be drawn from it. The 2-D and color gains are too high. In any case, the Court finds that Wyeth has established that no reasonable physician could diagnose Ellison with MAR, much less MMAR, based on a review of this echocardiogram.

F. MARIE FILLMORE

Fillmore relies on an October 17, 2002 echocardiogram and a report of Dr. Stanley S. Schrem. Dr. Schrem found that Fillmore had MAR using CAS criteria -- JH/LVOT = 17%. Dr. Schrem noted that the quality of the echocardiogram was "fair."

The October 17, 2002 echocardiogram was reviewed by three (3) experts: Dr. Chen, Dr. Gopal and Dr. Lassetter. All three (3) physicians found the echocardiogram was technically adequate.

Both Drs. Gopal and Chen found no aortic regurgitation in the PLAX view. Moreover, Dr. Gopal noted that "[o]nly a flicker (of aortic regurgitation) lasting 1 videoframe was noted in the apical views."

Dr. Lassetter disagreed. Dr. Lassetter found the study to be of "fair quality with gain and Nyquist settings which allowed diagnostic conclusions to be reached." Nevertheless, he decided that "AI is not well seen in the PLAX view on this echo." As a result, he used the A5C and A3C views and concluded, based on their review, that Fillmore has MAR. He measured a JH of .3 cm and a LVOT of 1.72 cm, yielding a JH/LVOT of 17%.

Dr. Chen criticized Dr. Lassetter's measurements here as well as his methodology. Dr. Chen observed:

> The PLAX view is available on this study. Dr. Lassetter does not measure the JH/LVOT ratio in the PLAX view, however, as required by the settlement criteria. Instead, he relies upon two apical views on Pages 32 and 42 of the DICOM which he measures a JH/LVOT ratio of 0.3/1.72 (17%). I have re-reviewed the study in its entirety, with particular attention to the pages mentioned, but with a focus on the PLAX view. I find that there is no AR jet in the PLAX view and thus, no AR according to the settlement criteria.
>
> Page 32 is an apical 5-chamber view and does not show a definite AR jet.
>
> Page 42 is an apical 3-chamber view (apical long-axis view) and shows a suspicious, intermittent, broken AR jet (4-5 frames of 8-9 diastolic frames) that cannot be measured and used to quantify aortic regurgitation for two reasons. First, it does not comply with the settlement criteria, since the PLAX view is available. Second, the jet is not continuous or fully developed. According to Dr. Weyman's textbook, only a fully developed jet can

> be measured for quantification of AR. Furthermore, the measured LVOT diameter of 1.72 cm is highly unusual, as a normal LVOT is normally more than 1.9 cm. However, Dr. Lassetter did not specify where he measured the LVOT diameter and thus, I cannot comment more specifically on his measurement.
>
> Dr. Lassetter also asserts that continuous wave Doppler images on Page 31 of the DICOM support the presence of AI. Page 31 shows the aortic valve opening and closing signal but no definite diastolic velocity spectrum with a peak velocity of more than 4 m/s. Aortic regurgitant CW velocity spectrum is usually more than 4 m/s. Therefore, there is no definite evidence of high velocity AR spectrum although there are very weak diastolic signals that peak at about 2 m/s, which cannot exclude a weak AR signal. However, this is a suspicious AR signal at best. In addition, the technician acquired the image with an improper baseline. The baseline should be placed on the 1/3 of the bottom of the image in order to properly display the spectrum of the AR signals.

The Court finds that Wyeth has demonstrated that no reasonable physician could conclude that Fillmore has MAR based on a review of this echocardiogram. First, the PLAX view is available and no aortic regurgitation is seen. All three (3) physicians agree on that. Second, the measurements made in the A3C are suspicious (LVOT = 1.72 cm is highly unusual). Third, as Dr. Gopal observed, the jet seen in the A3C view is "only a flicker."

G. NANCY FRAME

Frame relies on a June 24, 2002 echocardiogram and a report of Dr. Robert M. Applebaum. Dr. Applebaum found that Frame had MAR using CAS criteria -- JH/LVOT = 17%. Dr. Applebaum noted that the study's quality was "poor" and listed it as a "suboptimal study."

The June 24, 2002 echocardiogram was reviewed by three (3) experts: Dr. Chen, Dr. Gopal and Dr. Lassetter. All three (3) physicians found the echocardiogram to be technically adequate.

Both Drs. Gopal and Chen found "no evidence of aortic regurgitation in the parasternal long axis view." Apparently Dr. Lassetter did not either. He observed that "AI (aortic regurgitation) is not seen in on [sic] the PLAX view."

Instead, Dr. Lassetter found aortic regurgitation in "the apical views on pages 52, 53 and 60." He determined that the jet was holodiastolic and measured the JH at .56 cm and the LVOT at 2.1 cm, yielding a JH/LVOT = 26% which, in his view, was MMAR. Dr. Gopal, too, found evidence of aortic regurgitation in the apical views (52 and 53) and measured it at 15% (JH = .3 cm; LVOT = 2.0 cm).

Dr. Chen disagreed. In his view,

> [a]s stated in my original report, this echocardiogram is technically adequate, but there is simply no AR jet visible in the PLAX view.
>
> The PLAX view is available on this study. However, Dr. Lassetter does not measure the JH/LVOT ratio in the PLAX view, as required by the settlement criteria. Instead, he relies upon apical views on Pages 52, 53, and 60 of the DICOM, to support his conclusion of moderate AI. He measures (although it is unclear on exactly which of these pages) a JH/LVOT ratio of 0.56/2.1 (26%). I have re-reviewed the study in its entirety, with particular attention to the pages mentioned, but with a focus on the PLAX view as required by the settlement criteria.
>
> I find, again, no AR in the PLAX view. Pages 52, 53 and 60 are apical long-axis views that cannot be used for quantification of AR according to the settlement criteria if the PLAX view is available. In addition, there is no moderate AR according to my visual assessment in the apical views, even if they were allowed to be used.
>
> I agree with Dr. Lassetter that continuous wave Doppler spectrum on Page 42 of the DICOM shows the presence of AR but it cannot be used for quantification purposes.

The Court finds that Wyeth has established that the PLAX view was available -- that is, there were no technical problems rendering this view not available. Accordingly, Frame fails to meet the criteria established in the CAS. The Court finds, however, that a physician acting reasonably could find from a clinical perspective that Frame had at least MAR. While the Court disagrees with Dr. Lassetter's measurements, it is a matter of reasonable medical debate whether Frame, from a clinical perspective, has MAR. But that is not the test here. If the PLAX view is available, it must be used. The Court finds that the intent of the parties in the CAS, which was clearly expressed, was to prevent physicians such as Dr. Lassetter from making debatable medical judgments as to whether the PLAX views were diagnostic or not. If they were available, they were to be used.

H. CAROL FREDERICKSON

Frederickson relies on a July 9, 2002 echocardiogram and a report of Dr. John E. Lassetter. Dr. Lassetter found that Frederickson had MMR using CAS criteria -- RJA/LAA = 22%. Dr. Lassetter found the technical quality of the study to be "good."

The July 9, 2002 echocardiogram was reviewed by three (3) experts: Dr. Chen, Dr. Gopal and Dr. Lassetter. All three (3) physicians found the echocardiogram to be technically adequate, although both Drs. Gopal and Chen noted that the color Doppler gains were high and the Nyquist limit was marginal at 51 cm/sec. The gain setting on the Cypress machine here was high at 19. The Nyquist could have easily been set at a more acceptable 61 cm/sec given the probe depth.

Neither Dr. Gopal nor Dr. Chen found MMR. Dr. Gopal observed that:

> Only mild mitral regurgitation is present by visual inspection. Image 31 that was presumably chosen for the jet ratio analysis is overtraced and includes low velocity non-mosaic components. In addition, image 33 shows an undertraced left atrial area (frame is both undertraced and appears to stop short of end-systole when at the end of the T wave when atrial size should be maximum). Even assuming a value of 17.06 cm^2 is correct, the ratio calculates to 18.5% which does not meet criteria. The report uses larger values of the jet area that include low

> velocity components instead of 3.15 cm² in image 31 or 3.13 cm² in image 38.

Dr. Chen agreed, finding:

> In real-time images with regular heart beats or sinus rhythm, there is mild mitral regurgitation at most, even with the limitation of high color Doppler gain and a relatively low Nyquist velocity (51 cm/s[ec]), both of which exaggerate jet size and overestimate the degree of MR. The technician overtraced MR jets on still frame images. In fact, some of the "MR" jets traced are not real MR jets but are rather likely backflow associated with mitral valve closure at very early systole on the EKG tracing. The LAA was also undertraced by the technician. Measurements really should not be made on a study like this, both because of the technical problems and because the regurgitation is not holosystolic in real-time images. Still frame individual images overestimate the degree of MR.

Dr. Lassetter disagreed. In his view, the gain was adequate and the RJA of 3.77 cm² and the LAA of 17 cm² supported an MMR diagnosis of 22%. Dr. Chen questioned the LAA of 17.06 cm² which was significantly undertraced. Dr. Gopal had the same criticisms. Dr. Chen traced the LAA at 20.34 cm² which the Court believes is reasonable. At this LAA, even the RJA of 3.77 cm² does not compute to MMR. However, the Court believes the RJA too is overtraced. Dr. Chen measured the RJA at 2.86 cm² which the Court also believes is reasonable. These two (2) changes in Dr. Lassetter's measurements take the calculation well under 20%. The Court finds that Dr. Lassetter's measurements of both the RJA and LAA are not medically reasonable.

The Court finds that Wyeth has shown that no reasonable physician could conclude based on a review of this echocardiogram that Frederickson has MMR.

I. ROBERT GREIDER

Greider relies on a November 5, 2002 echocardiogram and a report of Dr. Charles F. Dahl. Dr. Dahl found Greider had MAR using CAS criteria -- JH/LVOT = 24%.

The November 5, 2002 echocardiogram was reviewed by three (3) experts: Dr. Chen, Dr. Gopal and Dr. Lassetter. All three (3) physicians found the echocardiogram to be technically adequate. The Court notes that the color gain setting on this Cypress machine was 15 and review shows the echocardiogram was overgained.

Neither Dr. Gopal nor Dr. Chen found MAR in the PLAX views. Dr. Gopal noted "[t]here is no evidence of aortic regurgitation in the true parasternal long axis view. However, in an apical long axis view or very low parasternal window, trace aortic regurgitation is noted." Dr. Gopal measured a JH of 2 mm and a LVOT of 22 mm or a JH/LVOT = 9.1%. She noted that "[t]his ratio is the highest possible ratio."[7]

---

[7] Dr. Gopal recognized that interreader variability can account for some differences in conclusions about valvular regurgitation. Here, however, it is clear to the Court that Dr. Gopal does not believe that it would be medically reasonable for aortic physicians to conclude that Greider has MAR based on a review of this echocardiogram. Her testimony on cross-examination and redirect on this point is reproduced in full.

> Q. Okay. Doctor, let's go to Mr. Robert Greider.
> And this echo you found to be technically adequate, correct?
> A. Yes.
> Q. It says on your worksheet, you measured Page 52, Frame 44 to arrive at a JH over LVOT of about 9.1 percent, correct?
> A. Correct.
> MR. EASTERBY: Let's go to Page 52, Frame 44, please, TJ. Doctor, is that the page and frame that you measured the jet height and LVOT?
> A. Yes.
> Q. Once again turning to the concept of inter-reader variability, would it be medically reasonable for another physician with your same skill set and training to have measured the jet height either slightly larger or the LVOT as slightly smaller to arrive at a ratio of 10 percent?
> A. Yes, that's possible.
> MR. EASTERBY: That's all the questions I have.
> I'll pass the witness. Thank you.
> REDIRECT EXAMINATION BY MS. PETERSEN
> Q. Hi, Dr. Gopal. I'm Cara Petersen. I just have a few questions for you.
> On Patricia Araiza, if you could turn to your materials on her.
> A. Okay.
> Q. There was some discussion about inter-reader variability and the difference in jet height measurements on this particular echo. I just wanted to turn to your opinions as to Question 1 and the technical adequacy of this echo.
> You found the gain to be elevated on this echo making it technically inadequate, right?
> A. That's right.
> Q. You said in your report that jet thickness and jet areas would be overestimated because of the high gain; is that right?
> A. That's correct.
> Q. Okay. That's all I have on that one.
> And then on Robert Greider, who was the last one we spoke about, again, there was some discussion as to whether inter-reader variability would account for differences in jet height LVOT ratios?

Dr. Lassetter found Greider has MMAR based on a review of this echocardiogram, claiming a JH/LVOT = 30% (JH - .37 cm; LVOT = 2.43 cm). He claims that this diagnosis is supported by CW Doppler.

Dr. Chen takes issue with Dr. Lassetter's conclusions. The PLAX view is available but Dr. Lassetter made no measurements there. Dr. Chen finds no MAR in the PLAX views. Dr. Chen also takes issue with Dr. Lassetter's claim that CW Doppler supports a diagnosis of MAR or greater. The Court agrees with Dr. Chen on both issues. The CW Doppler simply does not show a high velocity holodiastolic envelope one could expect with true aortic regurgitation.

The Court finds that Wyeth has established that no reasonable physician could conclude that Greider has MAR or greater aortic regurgitation based on review of this echocardiogram. There is no significant support for the MAR much less the MMAR claim here. The PLAX views were available and should have

---

A. Just a minute. I'm trying to find it.
THE COURT: Give me the Greider material.
A. Okay, I got it.
THE COURT: All right.
Q. And looking at Question 10, one of the issues you pointed out in your comments there was that this jet height may be overestimated because it is obtained from an apical view; is that correct?
A. That's correct.
Q. So, in your opinion, this nine percent ratio was a maximum in an apical view?
A. Correct.
Q. And, on Question 7 of your report for Greider, you stated that there was no evidence of aortic regurgitation in the parasternal long axis view; is that right?
A. That's right.
MS. PETERSEN: That's all I have.
THE COURT: All right. With respect to Greider, you indicated on this measurement this ratio was the highest possible ratio.

What does that mean, or what did you mean when you wrote that?
THE WITNESS: I mean that, you know, if you want to be really -- how should I say -- give the patient the, you know, most of the benefit of the doubt that this would be the highest, you know, reasonably the highest possible ratio you could come up with.

But, again, you know, this is from an apical view. So it's the -- this particular ratio, I don't know how meaningful it is in an apical view. You know, the criteria for --

(There is an interruption by the stenographer.)
THE WITNESS: (Continuing.) Brumhi (phonetic), I think, that's his -- Dr. Singh who -- Dr. Singh's paper that we referenced, you know, these ratios are supposed to be obtained in the parasternal long axis view and not the apical long axis view. And so we're trying to extrapolate, you know, one set of criteria to another. That's what I meant by that.
THE COURT: All right. Any follow-up Mr. Easterby?
MR. EASTERBY: No, your Honor.

been measured. The A3C view, in any case, provides no better than equivocal support which is not confirmed by CW Doppler.

J. JANETTE HARDEN

Harden relies on a September 30, 2002 echocardiogram and a report of Dr. Stanley S. Schrem. Dr. Schrem found that Harden had MMR and MAR using CAS criteria -- RJA/LAA = 23%; JH/LVOT = 17%. Dr. Schrem found the study to be technically "fair." Wyeth has not challenged the MMR claim.

The September 30, 2002 echocardiogram was reviewed by three (3) experts: Dr. Schwartz, Dr. Millman and Dr. Lassetter. Both Drs. Millman and Schwartz found that this echocardiogram was not conducted in a technically adequate manner such that reliable medical conclusions regarding the presence and severity of valvular regurgitation could be drawn from it. Dr. Schwartz summarized the criticisms as follows:

> The parasternal long-axis views and the apical 3-chamber view are technically inadequate and uninterpretable due to the unreasonably high color Doppler gain. The other apical views, while technically adequate, are of borderline quality.

Dr. Millman concurred and further observed that the Nyquist limit was a borderline 51 cm/sec. The Cypress machine was used here and the gain setting was 17. The poor quality was evident in the PLAX and A3C views.

Dr. Lassetter disagreed. He noted the study was of "fair" quality with acceptable gain settings, though he conceded on cross-examination that the gain was "high." He found MMAR with a JH/LVOT = 25%. No measurements were provided in his affidavit.[8] There is support in the CW that there is some aortic regurgitation. Dr. Millman concluded that "[t]here is a good CW envelope present indicating the presence of ar (aortic regurgitation)." The Court believes that the envelope, however, is not robust.

The Court has reviewed this echocardiogram and has considered the testimony as well. All in all, this echocardiogram has been shown not to be

[8] Dr. Lassetter provided two (2) JH/LVOT measurements during his testimony (JH = .4 cm, LVOT = 1.86 (21.5%); JH = .3 cm, LVOT = 1.86 cm (16.7%).

conducted in a technically adequate manner such that reliable medical conclusions regarding the presence and severity of valvular regurgitation could be drawn from it. While there is some evidence of aortic regurgitation, the Court finds that given the technical information no reasonable physician could conclude that Harden has MAR or greater aortic regurgitation based on this echocardiogram.

K. NANCY HARRIS

Harris relies on a July 30, 2002 echocardiogram and report of an interpreting cardiologist whose signature cannot be deciphered. That physician found that Harris had MAR using CAS criteria -- JH/LVOT = 18%.

The July 30, 2002 echocardiogram was reviewed by three (3) experts: Dr. Chen, Dr. Millman and Dr. Lassetter. Both Drs. Millman and Chen found that this echocardiogram was not conducted in a technically adequate manner such that reliable medical conclusions regarding the presence and severity of valvular regurgitation could be drawn from it. According to Dr. Chen, the "[e]xtremely high color Doppler gain settings exaggerate regurgitant jet size and render assessment of degree of aortic regurgitation with the settlement criteria (JH/LVOT) unreliable." Dr. Millman concurred.

Dr. Lassetter disagreed. He found the study to be of "good quality with acceptable gain settings." The Cypress machine was used here with a gain setting of 11.

Because of the poor quality of the study, both Drs. Millman and Chen found it impossible to identify, much less quantify, any alleged aortic regurgitation. Dr. Millman noted that "[t]he high color gain settings make a clear delineation of a holodiastolic ar signal impossible. In addition, the cw study shows a very poor ar envelope, indicative of less than trivial ar." Dr. Chen was of the same view:

> Extremely high color Doppler gain settings exaggerate regurgitant jet size and render assessment of degree of aortic regurgitation with the settlement criteria (JH/LVOT) unreliable. The color cluster measured by the technician has a lower velocity in its proximal segment than the distal segment and is not consistent with a typical AR jet which has a higher velocity at its proximal segment than the distal part.

Dr. Lassetter found MAR here with a JH of .34 cm and a LVOT of 1.9 cm, yielding a JH/LVOT of 17.8%. During the hearing, it became clear that this was made in the A3C view. During the hearing, Dr. Lassetter reported a JH of .29 cm and a LVOT of 1.9 cm, yielding a JH/LVOT of 15.3%, but there was so much artifact which was commingled with the purported jet that the Court believes no reliable measurement could be made.

The Court finds that Wyeth has established that this echocardiogram was not conducted in a technically adequate manner such that reliable medical conclusions regarding the presence and severity of valvular regurgitation could be drawn from it. The gain simply is too high. The Court finds that given the technical inadequacies here no reasonable physician could determine that Harris has MAR based on a review of this echocardiogram.

L. ORIA HAYS

Hays relies on a December 6, 2002 echocardiogram and report of Dr. Charles F. Dahl. Dr. Dahl found that Hays had MAR using CAS criteria -- JH/LVOT = 22%.

The December 6, 2002 echocardiogram was reviewed by three (3) experts: Dr. Chen, Dr. Millman and Dr. Lassetter. Both Drs. Millman and Chen found that this echocardiogram was not conducted in a technically adequate manner such that reliable medical conclusions regarding the presence and severity of valvular regurgitation could be drawn from it. Dr. Chen explained his reasoning for this determination.

> Technically inadequate study for evaluation of the degree of aortic regurgitation, due to high color Doppler gain settings which exaggerate regurgitant jet size and render assessment of the degree of any aortic regurgitation under the settlement criteria (JH/LVOT ratio) unreliable.

Dr. Millman concurred. The Cypress machine was used here and the gain setting was 17.

Dr. Lassetter disagreed. According to him, this was "a good quality study with acceptable gain settings." The Court disagrees with Dr. Lassetter. The echocardiogram could not be meaningfully deciphered. The color Doppler gain, combined with a high 2-D gain, obscured the cardiac structures and masked any

jets if they indeed existed. While Dr. Lassetter claimed to measure a JH of .53 cm and a LVOT of 1.82 cm, the Court is convinced that no meaningful quantification of aortic regurgitation could be made here. Dr. Chen's observations are particularly apt:

> In real-time images, a tiny AR jet intermingles with high color gain artifacts. In addition, the technician measured JH from low velocity flow or an AR jet tail in the LVOT, but not the proximal segment of any AR jet. Due to technical inadequacy no measurements should be made at all on this study, and no medically reasonable conclusions can be drawn from it about the degree of AR.

The Court finds that Wyeth has easily established that this echocardiogram was not conducted in a technically adequate manner such that reliable medical conclusions regarding the presence and severity of valvular regurgitation could be drawn from it. The 2-D and color Doppler gains make any quantification efforts the functional equivalent of speculation.

M. RYANN HENRY

Henry relies on a November 25, 2002 echocardiogram and report of Dr. Stanley S. Schrem. Dr. Schrem found Henry had MAR using CAS criteria -- JH/LVOT = 19%. Dr. Schrem reported the study quality as "fair."

The November 25, 2002 echocardiogram was reviewed by three (3) experts: Dr. Chen, Dr. Millman and Dr. Lassetter. Both Drs. Millman and Chen found that this echocardiogram was not conducted in a technically adequate manner such that reliable medical conclusions regarding the presence and severity of valvular regurgitation could be drawn from it. Dr. Millman observed that "[t]he color [D]oppler gain was set so high that meaningful data is lost in the 'noise.' The Nyquist limit was appropriate at 0.61." Dr. Chen was more emphatic:

> Technically inadequate for evaluation of the degree of aortic regurgitation due to high color Doppler gain settings which exaggerate regurgitant jet size and render assessment of the degree of aortic regurgitation using the settlement criteria (JH/LVOT ratio) unreliable.

The Cypress machine was used here and had color Doppler gain settings at 14. The 2-D gain here plainly was too high.

Dr. Lassetter disagreed. In his view, the echocardiogram here "is of good quality with acceptable gain." Dr. Lassetter found that Henry has MR based on a JH of .35 cm and a LVOT of 1.8 cm which computes to 19%.

The Court has reviewed this echocardiogram and concurs with Dr. Chen's observations as to Dr. Lassetter's findings. The Court adopts Dr. Chen's observations as its own.

> Dr. Lassetter relies on images in the PLAX view on Pages 9, 10 and 11 of the DICOM to support his conclusion that there is mild AR present on this study. He asserts that he measured a JH/LVOT ratio of 0.35/1.8 (19%). Dr. Lassetter also refers to images in the apical long axis view on pages 47 and 48, but because the PLAX view is available, these images are not pertinent for assessment of AR in this case, according to the settlement criteria. I have re-reviewed the study in its entirety, with particular attention to the pages mentioned.
>
> Pages 10 and 11 are parasternal long-axis views with high color Doppler and 2-D gain settings. High 2-D gain masks high color Doppler gain in the tissue due to the overpowered brightness of tissue with tissue priority of color Doppler algorithm. Although aortic regurgitation is present, its degree cannot be reliably evaluated with high color Doppler gain settings. On Page 9, there is an AR jet with superimposed artifact. The technician's JH measurement which Dr. Lassetter relies upon includes color artifact/low velocity LVOT flow due to high color Doppler gain. Solely for demonstrations purposes only, I remeasured the JH at 0.19 cm and LVOT at 2.22 cm (JH/LVOT = 8.56%) (Exhibit 6). In addition, LVOT of 1.8 cm on page 12 is improperly undermeasured.
>
> Dr. Lassetter also asserts that continuous wave Doppler image on Page 36 of the DICOM supports his conclusion of mild AI, demonstrating a pressure half-time of 357

> m/sec. Page 36 shows a very weak AR signal without a complete regurgitant profile or spectrum that allows for proper measurement of AR pressure half-time. In fact, the technician randomly, or imaginatively, drew a line for the purported AR pressure half-time measurement with a peak AR velocity of less than 3 m/s (generally, AR regurgitant peak velocity is more than 4 m/s). Thus, the measurement is improper and cannot be used for evaluation of the degree of aortic regurgitation.

The Court finds that Wyeth has easily established that this echocardiogram was not conducted in a technically adequate manner such that reliable medical conclusions regarding the presence and severity of valvular regurgitation could be drawn from it. The 2-D color Doppler gains are far too high. Moreover, for the reasons articulated by Dr. Chen, no reasonable physician could conclude, based on a review of this echocardiogram, that Henry has MAR.

N. CHERIE HEROLD

Herold relies on an October 10, 2002 echocardiogram and report of Dr. John E. Lassetter. Dr. Lassetter found Herold had MMR using CAS criteria -- RJA/LAA = 24%.

The October 10, 2002 echocardiogram was reviewed by three (3) experts: Dr. Chen, Dr. Millman and Dr. Lassetter. Both Drs. Millman and Chen found that this echocardiogram was not conducted in a technically adequate manner such that reliable medical conclusions regarding the presence and severity of valvular regurgitation could be drawn from it. Dr. Millman observed that "[t]he Color Doppler gains are too high and the apical views are off-axis, poorly defining the left atrial area. The Nyquist limit of 0.51 is acceptable but not optimum." Dr. Chen concurred in these views and found other technical flaws as well:

> Technically inadequate for evaluation of degree of valvular regurgitation due to high color Doppler gain settings which exaggerate regurgitant jet size and render assessment of degree of regurgitation under the settlement criteria unreliable. Relatively low Nyquist limit velocity (51 cm/s[ec]) exacerbates this problem. This echo has limited study quality with oblique or foreshortened apical views as well.

Both physicians felt that trivial, or at most, mild mitral regurgitation was present.

Dr. Lassetter disagreed. He saw none of the infirmities identified by Drs. Millman and Chen. Dr. Lassetter concluded that Herold's echocardiogram was "of good quality with adequate gain and Nyquist limit of 51...." He found MMR with a RJA of 2.68 cm² and a LAA of 11.25 cm² or 23.6%. Dr. Lassetter believed the CW Doppler supported his conclusion that this jet was holosystolic. The Court disagrees with Dr. Lassetter's conclusions. Dr. Chen's criticisms here mirror those of the Court and are provided in the footnote.[9]

---

[9] Dr. Chen's observations are as follows:

> As stated in my original report, this echocardiogram is technically inadequate due to the high color Doppler gain setting, in combination with the relatively low Nyquist setting of 51 cm/sec. In addition, this study is of limited image quality, with oblique or foreshortened views apical views.
>
> Dr. Lassetter relies on images on Pages 35, 36, 38, and 40 of the DICOM to support his conclusion that there is moderate MR present on this study. He asserts that he made RJA/LAA measurements of 2.68/11.25 (23.6%) on Page 36. I have re-reviewed the study in its entirety, with particular attention to these pages.
>
> Page 36 is a still frame of the apical 4-chamber view which is slightly oblique. The measurements on Page 36 that were relied upon by Dr. Lassetter are improper. The MR jet is not clearly delineated and is mixed with adjacent low velocity atrial flow which is visible due to high color Doppler gain settings. In addition, the technician overtraced the unclearly delineated MR jet. I normally would not choose this jet to measure; however, solely for demonstration purposes, I retraced this MR jet to show the improper overtracing by the technician. I measured the MR jet at 1.99 cm² even with my most generous tracing. (Exhibit 7) Additionally, the sonographer slightly undertraced the LAA in an oblique view with high 2-D gain in the atrial section. Using an oblique view with high 2-D gain can lead to underestimation of the atrial area. Even with this limitation, I traced the left atrial area for demonstration purposes only and found an LAA of 12.54 cm² (Exhibit 8), resulting in RJA/LAA of 15.9%.
>
> Pages 35, 38 and 40 show real-time cine loops of the apical 4-chamber view (slightly oblique) with color Doppler flow mapping. The color Doppler gain setting is too high, preventing reliable assessment of the degree of MR. Despite the high color Doppler gain setting, the MR appears mild at most.
>
> Dr. Lassetter also asserts that spectral Doppler images on Page 44 of the DICOM support his conclusion that the study demonstrates holosystolic MR. Page 44 shows an incomplete, weak signal of MR which is predominantly in mild to late systole on the CW Doppler recording. However, the Doppler scale is set too low (1 m/s) and no full spectrum of MR signal was recorded. Therefore, this CW recording cannot be used to assess the degree of MR. Nor can the CW recording be used to determine whether the MR is holosystolic because of the incomplete Doppler spectrum and improper recording.

The Court finds that Wyeth has established that this echocardiogram was not conducted in a technically adequate manner such that reliable medical conclusions regarding the presence and severity of valvular regurgitation could be drawn from it. The color Doppler gains were far too high in the presence of a marginal Nyquist limit.

O. LISA A. HORNE

Horne relies on a March 28, 2002 echocardiogram and report of Dr. George G. Miller. Dr. Miller found Horne had MAR using CAS criteria -- JH/LVOT = 12%.

The March 28, 2002 echocardiogram was reviewed by three (3) experts: Dr. Schwartz, Dr. Millman and Dr. Lazar.[10] Both Drs. Millman and Schwartz found that this echocardiogram was not conducted in a technically adequate manner such that reliable medical conclusions regarding the presence and severity of valvular regurgitation could be drawn from it. Dr. Schwartz reported the "Nyquist setting is 49 cm/sec throughout the entire study." Dr. Millman concurred that the Nyquist limit was set too low. Moreover, Dr. Millman reported that the CW Doppler failed to demonstrate anything beyond "trivial" aortic regurgitation.

Dr. Lazar disagreed. According to him, Horne's echocardiogram can be evaluated and it demonstrates MAR with a JH of .3 cm and a LVOT of 2.1 cm, yielding 14%. The Court rejects these measurements as artifactual. As noted by Dr. Thomas, lower Nyquist limits significantly distort putative regurgitant jets. More to the point, there is no reason for this artificially low Nyquist limit. As noted by Dr. Schwartz, the probe depth of 15-17 cm would allow Nyquist limits in the high 50's and low 60's. There simply was no reason to artificially lower the Nyquist limit here.

The Court finds that Wyeth has demonstrated that this echocardiogram was not conducted in a technically adequate manner such that reliable medical conclusions regarding the presence and severity of valvular regurgitation could be drawn from it. The artificially low Nyquist limit has the potential for significantly distorting any observed phenomenon.

[10] The attorneys for Horne requested that the Court consider the written submission of Dr. Lazar. He was not present at the proceeding.

P. GLEN A. HORSPOOL

Horspool relies on a March 1, 2000 echocardiogram report of Dr. Richard L. Converse. Dr. Converse found that Horspool had "mild to moderate mitral regurgitation" and "mild aortic insufficiency." It is unclear whether CAS criteria were used to make any of these determinations and no worksheet indicating the measurements used is available. The mitral valve claim is further complicated by Dr. Converse's impression "[m]ild age related valvular abnormalities with *possibly even moderate mitral regurgitation present*." (Emphasis added.)[11]

The echocardiogram was reviewed by three (3) experts: Dr. Schwartz, Dr. Millman and Dr. Jacob. Both Drs. Millman and Schwartz criticized the echocardiogram finding that the study "was of poor quality in the PLAX views chosen." Dr. Millman considered the A3C view and found there "is mild AR present." Dr. Millman also found MMR observing that "[a]lthough the echo report is vague, there is clearly 70% MR in multiple apical views."

Dr. Jacob's affidavit is almost worthless. It completely fails to substantiate the mitral valve claim.[12] While it claims that MAR is present, no measurements are given though time counter locations are provided. During testimony, Dr. Jacob confirmed that he made no measurements. The Court finds that Dr. Jacob's opinion on Horspool is a net opinion under *Buckelew v. Grossbard*, 87 N.J. 512 (1981), and is entitled to no weight.

The Court, however, finds that Wyeth, in this case, has failed to establish that no reasonable physician could conclude that Horspool has either MMR and/or MAR. As to the MAR claim, the Court finds that the PLAX view was unavailable. It was so technically deficient that no useful information could be drawn from it. Dr. Millman found MAR in the A3C view which is a permissible view. While Dr. Jacob has made no useful contribution here, the Court cannot say that no reasonable physician could conclude that Horspool does not have MAR based on a review of this echocardiogram.

---

[11] The attorneys for Horspool claim that Dr. Jacob did not address the mitral claim because Dr. Schwartz did not in Wyeth's challenge. Given the report, it is difficult to understand why Wyeth should have. The report does not put the mitral valve in contest as far as this Court is concerned. The Court probably should preclude this claim based on the March 1, 2000 echocardiography report. However, because it believes the MAR claim has merit, it will not strike the MMR claim.

[12] The Court advises the parties that if a similar report is submitted in the future it will strike the opposition to the challenge and enter judgment for Wyeth.

The Court also finds that Wyeth has not convinced it that no reasonable physician could conclude based on this echocardiogram that Horspool has MMR as well. In so finding, the Court acknowledges that Wyeth could have reasonably believed that no such claim was being made. Dr. Jacob's failure to address any MMR claim certainly provides support for that position. Moreover, the Court has serious doubts that counsel for Horspool was genuine in his representation that Dr. Jacob did not address the mitral claim because it was believed that Wyeth had conceded it. Nevertheless, the Court will permit this claim to remain using an abundance of caution and giving this plaintiff every benefit of the doubt.

QQ. JEMMA JACKSON

Jackson relies on a December 5, 2002 echocardiogram and report of Dr. Stanley S. Schrem. Dr. Schrem found that Jackson had MMR using CAS criteria -- RJA/LAA = 21%. Dr. Schrem noted that the study quality was "fair."

The December 5, 2002 echocardiogram was reviewed by three (3) experts: Dr. Chen, Dr. Millman and Dr. Dahl. Both Drs. Millman and Chen found that this echocardiogram was not conducted in a technically adequate manner such that reliable medical conclusions regarding the presence and severity of valvular regurgitation could be drawn from it. Dr. Chen observed that the "[e]xtremely high color Doppler gain settings with excessive color artifacts and speckles render this study uninterpretable for assessment of degree of valvular regurgitation." Dr. Millman concurred. Both physicians also concluded that the echocardiogram fails to support a MMR claim. Dr. Millman noted

> [t]here is no significant holodiastolic MR signal seen in the real time color images. There is considerable artifact, and the images selected for measurement do not in fact reflect the systolic pattern present. In addition, the measurements were far to[o] inclusive, even on the data presented. The CW [D]oppler doesn't substantiate significant MR.

Dr. Chen concurred and added:

> In addition, "MR" jets measured by the technician are at very early systole and last only a single frame in early systole and thus are not real MR jets. They are backflow

> associated with mitral valve closure, which is exaggerated by high color Doppler gain.

Dr. Dahl disagreed. He stated:

> It is my opinion that the echocardiogram was of diagnostic quality and demonstrated moderate mitral regurgitation with a Singh ratio (JH/LVOT) of 34% according to methods of quantifying regurgitation and ranges for various levels of regurgitation as stated in the Singh article. Further it is my opinion that that diagnosis is medically reasonable utilizing the protocols and criteria required by this litigation.

While Dr. Dahl claims to have measured a RJA/LAA ratio of 34%, it was evident that the LAA was measured early in systole and was not representative of the true LAA.[13]

---

[13] Dr. Dahl's testimony on this report is presented in this footnote.

> Q. Well, the reason I ask, if we can go back to Defense Exhibit 7017, the original echocardiographic report, 5092, when this echo was originally reviewed and read and the qualifying echo, they found the physician found a left atrial area of 19 square centimeters, did he not?
> A. That's what's written there.
> Q. That's certainly a significant departure from what you have revised from your review of the echo and the measurement you made on the frozen frame that you've submitted, isn't it?
> A. That is different, yes.
> Q. Now, by the same token, if I may, I want to show you -- by the way, on Page 22, do you recall where you -- where do you normally measure the left atrial area or attempt to measure it in order to maintain a reliable measurement?
> A. Where do I measure it?
> Q. At what point in the cycle?
> A. At the end of systole.
> Q. If we can put up 20 or 22. I think they're both the same.
> Doctor, would it be fair to say that based upon the cursor at the very least, this is being measured at approximately mid-systole?
> A. Towards late systole, I think that cursor is on the downward slope of the T-wave.
> Q. It would not be end systole, would it?
> MR. EASTERBY: End or in?
> A. It's debatable. The end of the T-wave is the end of systole, so it's very close to the end of the T-wave.
> Q. Let me show you a measurement that has been made and submitted to the Court and that is Page 19, FTI 7022.40.
> MR. RAMSAY: Is that it?
> THE TECHNICIAN: No.

The Court believes that the LAA was seriously undermeasured here and the RJA seriously overmeasured. When one considers the gain which on the Accuron machine here was set at 19, no useful information could be obtained. The Court considered Dr. Chen's comments on these points on all fours and adopts them.

> Dr. Dahl relies on images of apical views on Pages 36 and 39 of the DICOM to support his conclusion that there is moderate MR present on this study. He asserts that he made RJA/LAA measurements of 4.1/12.0 (34%) on

---

Q. Doctor, as you review that measurement, do you have any disagreement with the way it was performed?
A. Yes, I do.
Q. And for the record, that was performed by Dr. Chen. And as you look at it, can you tell that it is, in fact, at end systole?
A. It appears to be. It appears to be outside the borders.
JUDGE WALSH: Your concern is there appears to be tissue infiltration inside the tracing?
THE WITNESS: Yes.
JUDGE WALSH: Apparently, there's a lot of 2-D gain here, but I agree with you, the tracing is outside the color -- the noncolor that, the so-called 2-D images.
BY MR. RAMSAY:
Q. When you make a measurement that you feel is representative of what you see in real-time, do you include
laminar flow in your measurement of mitral regurgitation?
A. You try not to.
Q. Let's turn to Page 36, which was the page that you cited to the Court for your measurement. Excuse me, 39.
I've got 36, but you got 36.
THE TECHNICIAN: 39.
MR. RAMSAY: Excuse me, 39.
Q. With that particular measurement that you've told us you've relied upon, first and foremost we can agree there is over tracing of that measurement, is there not?
A. Very minimal, perhaps in the lower left-hand corner.
Q. And as one looks to the right at the right side, isn't most of what we see there, in fact, low velocity nonturbulent flow?
A. No, it's velocity just about at the Nyquist limit.
Q. Are you including the dark laminar areas?
A. Yes, a little bit is included, a very small amount but a
little is included.
BY MR. RAMSAY:
Q. I have one final question with regard to Ms. Jackson. Doctor, in your practice, where in fact one wants confirmation or questions whether or not the phenomena they see is, in fact, high velocity and/or holosystolic, you utilize continuous wave and spectral Doppler, do you not?
A. We do.
Q. If we can now turn to Page -- let me have Page 33. As one looks at that particular continuous wave Doppler, one does not see high velocity flow that lasts throughout most or all of the cycle, does one?
A. That's correct.

Pages 36 and 39. (Dr. Dahl also refers to parasternal views, but these are not pertinent for assessment of the RJA/LAA ratio according to the settlement criteria). I have re-reviewed the study in its entirety, with particular attention to these pages.

Page 36 is a still frame image of the apical 4-chamber view with color clusters similar to two small regurgitant jets with color artifacts due to high color Doppler gain settings. Dr. Dahl improperly relies on the technician's mitral regurgitant measurement of 4.12 cm^2 in this view. The technician overtraced the MR jet by including the space between the two MR jets and tracing beyond the jet edges. Due to the high color Doppler gain settings with excessive artifacts in the apical 4-chamber view of real-time cine-loops on Page 34, I cannot confirm whether the MR jet visualized on Page 36 in the still frame is a true MR jet that is holodiastolic or lasts at least a significant portion of systole (usually most of systole).

Page 39 is a still frame of the apical 2-chamber view with amorphous color cluster at very early systole without clear evidence of the color cluster stemming from the mitral valve or proximal acceleration area that a typical significant true regurgitant jet would have. Therefore, this amorphous color cluster cannot be confirmed as a true MR jet. In fact, in real-time imaged on Page 38 (apical 2-chamber), a similar amorphous color cluster in very early systole is noted, but the color cluster lasted only a single frame and thus, it is not a true MR jet. It is likely backflow or color artifact due to the extremely high color Doppler gain and relatively low Nyquist velocity (51 cm/s[ec]) at an imaging depth of 16.2 cm (Nyquist velocity should be 61 cm/s[ec] or more at this depth). In addition, the LAA is improperly undertraced by the technician. Solely for demonstration only, I traced the "MR" jet on Page 36 with RJA of 1.05 cm^2 and 1.3 cm^2 (2.35) ... and LAA of 18.25 cm^2 ... on Page 19, resulting in RJA/LAA ratio of 12.88%.

The Court finds that Wyeth has established that this echocardiogram was not conducted in a technically adequate manner such that reliable medical conclusions regarding the presence and severity of valvular regurgitation could be drawn from it. The gain was far too high. Moreover, the claimed mitral regurgitation was measured at the beginning of systole and was wildly overmeasured. No reasonable physician could conclude, based on this echocardiogram, that Jackson has MAR.

R. GARY C. JOHNSON

Johnson relies on an October 8, 2002 echocardiogram report of Dr. G. William Pogson. Dr. Pogson found Johnson had MMR using CAS criteria -- RJA/LAA = 23%. Dr. Pogson noted left atrial enlargement.

The echocardiogram was reviewed by three (3) experts: Dr. Schwartz, Dr. Millman and Dr. Jacob. All three (3) physicians found the echocardiogram to be technically adequate although Dr. Schwartz noted that the study was "borderline." In his view, the "color gain is too high" and the Nyquist limit of 51 cm/sec was "borderline."

Both Drs. Millman and Schwartz found that the phenomenon observed in the echocardiogram was nothing more than closing volume and was seen in only one (1) of twelve (12) systolic frames. This closing volume phenomenon is confirmed with CW Doppler in the view of both physicians.

Dr. Jacob came to a different conclusion. According to him, Johnson has MMR with RJA findings between 22-25%. He relied on the sonographer's tracings and did none of his own. Dr. Jacob conceded that the measured frame was the first and last of the twelve (12) frame systolic cycle and the only evidence of regurgitation. The claimed regurgitation was clearly not holosystolic.

The Court finds that Wyeth has easily met its burden and shown that no reasonable physician could conclude on the basis of this echocardiogram that Johnson has MMR. The phenomenon observed plainly was closing volume.

S. ANI KELESHIAN

Keleshian relies on a September 9, 2002 echocardiogram report of Dr. Charles F. Dahl. Dr. Dahl found that Keleshian had MAR using CAS criteria -- JH/LVOT = 12%.

The echocardiogram was reviewed by three (3) experts: Dr. Teichholz, Dr. Millman and Dr. Dahl. Both Drs. Millman and Teichholz found that this echocardiogram was not conducted in a technically adequate manner such that reliable medical conclusions regarding the presence and severity of valvular regurgitation could be drawn from it. Dr. Millman observed that "[t]he color gains are too high and obscure any useful signal." Dr. Teichholz concurred. The Cypress machine was used here and the color Doppler gain was set at 16 and 20 in the apical views. Both physicians also agreed that there was no "significant" aortic regurgitation present. According to Dr. Teichholz,

> [e]ven with the high gain settings, no aortic regurgitation is visualized in the PLAX view, nor are any measurements of JH/LVOT made in this view. Instead, measurements are improperly made in the apical long-axis view, but regardless, these measurements are made very late in diastole and measure what is probably noise created by the high color gain settings.

Dr. Dahl disagreed. In his view, the echocardiogram "was of diagnostic quality." Dr. Dahl found that the PLAX view was not diagnostic and made his measurements in the A3C. He found a JH of .23 and a LVOT of 1.8 cm, yielding 13%.[14] On cross-examination, Dr. Dahl conceded that CW Doppler did not demonstrate that any phenomenon was holodiastolic.

The Court finds that Wyeth easily met its burden and has shown that Keleshian's echocardiogram was not conducted in a technically adequate manner such that reliable medical conclusions regarding the presence and severity of valvular regurgitation could be drawn from it. The color gains were far too high. Even Dr. Dahl conceded that these gains obscured certain necessary landmarks such as the valve annulus.

T. GREGORIA LAMB

Lamb relies on a September 5, 2002 echocardiogram and a report of Dr. G. William Pogson. Dr. Pogson found Lamb had severe mitral regurgitation ("SMR") using CAS criteria -- RJA/LAA = 43%. The left atrium was noted to be enlarged.

[14] As noted by Dr. Teichholz and acknowledged by Dr. Dahl, the frame in which the JH of .23 is measured is taken right before the onset of the QRS complex which places it potentially in the isovolumic relaxation period. No JH measurements should be made in this transition period.

The September 5, 2002 echocardiogram was reviewed by three (3) experts: Dr. Kutnick, Dr. Ong and Dr. Jacob. Dr. Ong found that this echocardiogram was not conducted in a technically adequate manner such that reliable medical conclusions regarding the presence and severity of valvular regurgitation could be drawn from it. In his view, "the color gain setting [was] too high." Drs. Kutnick and Jacob found the echocardiogram to be technically adequate.

Both Drs. Ong and Kutnick found no support for a MMR claim, much less a SMR claim. According to Dr. Ong, "[t]he measurements were of color-flow artifact that is usually depicted as 'blue.' There was only a small amount of turbulent flow seen in mitral regurgitation. This was not measured. Review of time frames 1:48:00 through 1:49:00 confirmed this." Dr. Kutnick concurred and observed that there was no holosystolic mitral regurgitation. "Real-time loops show that the true MR jet is small, amounting to no more than mild MR. The sonographer measured a flash of early systolic, laminar blue, color artifact. Spectral Doppler showed only a faint jet of MR in early to mid-systole."

Dr. Jacob disagreed. In his view, the echocardiogram demonstrated MMR. No measurements were provided, but only an assurance that "[t]he color duration and timing of the MR jet was consistent with FDA positive levels of moderate MR." He apparently relied on the sonographer's measurements but he could not even clarify that with the cross-examiner. This opinion, which has no substance to it, is of little or no value to the Court. On cross-examination, Dr. Jacob conceded that the jet he claimed was MMR was seen in only one (1) frame and was certainly not holosystolic. He also confirmed that the CW Doppler failed to show a robust regurgitation envelope.

The Court finds that Wyeth has established that no reasonable physician could conclude, based on a review of this echocardiogram, that Lamb has MMR, let alone SMR.

U. MICHELLE LINDSAY

Lindsay relies on a November 7, 2002 echocardiogram report of Dr. Charles F. Dahl. Dr. Dahl found Lindsay had MAR using CAS criteria -- JH/LVOT = 20%.

The echocardiogram was reviewed by three (3) experts: Dr. Chen, Dr. Ong and Dr. Jacob. Dr. Ong found that this echocardiogram was not conducted in a technically adequate manner such that reliable medical conclusions regarding the

presence and severity of valvular regurgitation could be drawn from it. Dr. Ong explained that:

> See Part A regarding technical inadequacy (high color gain). In addition, no aortic regurgitant jet is noted in real-time images on color Doppler. No AR signal is noted on spectral Doppler either. "AR" jets measured by the technician do not have corresponding real-time images and cannot be confirmed by real-time images or spectral Doppler and thus, cannot be confirmed as AR jets. Because of high color Doppler gain setting with excessive artifacts, these color clusters are likely artifacts.

Dr. Chen found the color gains to be "excessively high" but believed the "study was interpretable for excluding regurgitation." The Cypress machine was used here and the color gain was set at 18. Dr. Ong, on the other hand, felt the excessive gain made any quantification efforts impossible.

Dr. Jacob disagreed. In his view, Lindsay's echocardiogram "was of diagnostic quality and demonstrated FDA positive aortic regurgitation." No serious quantification efforts were made by Dr. Jacob. He simply observed that pages 13, 14, 15 and 16 demonstrate ratios greater than 10%. The Court finds that Dr. Jacob's observations are almost useless. On cross-examination, Dr. Jacob conceded that the phenomenon he claimed was aortic regurgitation occurred in only two (2) of fifteen (15) frames and the holodiastolic claim was not supported by CW Doppler. [15]

---

[15] Dr. Jacob's testimony had virtually no content. The entire cross-examination is contained in this footnote and illustrates this point.

> Q. All right. Let's go to Lindsay, Michelle Lindsay. Now, with regard to Michelle Lindsay, you have certified to the court that Ms. Lindsay has FDA positive aortic insufficiency, and you cited the peristomal long axis view, page 12, and measurements on pages 13, 14 and 15, correct, and 16?
> A. Yes.
> Q. And Doctor, here again with regard to Ms. Lindsay, you gave no specific measurements, did you?
> A. No.
> Q. In fact, your Certification simply says according to Singh it would be greater than 10 percent?
> A. Yes.
> Q. So, can you tell me where whether you used calipers or whether you actually just relied on measurements made by the sonographer?
> A. Can we see it again.

Q. Sure. Let's to go page 12, real time. We have a gain that is 13 and you can see speckling there, can you not?
A. Just a bit.
Q. Did I say -- what did I say? I meant to say 18.
A. Page 12?
Q. Page 12, the gain setting is 18, I think it says there, correct? All right. Let's first look and see. You had suggested, at least by your Certification, that this jet in your opinion was holodiastolic?
A. Right.
Q. Let's go to, and I have gone through it, page 12, if we can start at frame 17.

Doctor, as we look at this particular frame, can we agree that at this point we are not in diastole; we are still in systole?
A. Yes.
Q. Frame 18. Where are we now?
A. Just probably beginning diastole.
Q. All right. And you can see where the mitral valve is closing, can you not, or almost closed? You need to verbalize your answer. Is that yes?
A. Can we go on a few frames?
Q. All right. Let's go to frame 19. Can we agree the mitral valve appears to be closed there?
A. Can we keep going?
Q. Can you answer the question based upon this frame?
A. No.
Q. Frame 20. Can you tell me yet whether we are in diastole?
A. Yeah, I think we are.
Q. All right. You don't see anything there, do you?
A. No.
Q. On frame 20. 21, frame 21, please. You don't see anything on frame 21 either, do you?
A. No.
MR. EASTERBY: Object to form. What do you mean see anything?
Q. Well, you don't see anything -- well, you see nothing but a red blob there?
A. Red blob?
Q. Frame 22.
A. I agree, red blob.
Q. Same response, a red blob, correct?
A. Yes.
Q. And part of that is because the gain is high, is it not?
A. I don't know. The gain here is not too bad.
Q. All right. Frame 23. Once again, you cannot discern a regurgitant jet in frame 23, can you?
A. No.
Q. Frame 24. You can't discern a jet in frame 24 either, can you, Doctor?
A. I am not sure. This may be right here.
Q. May be?
A. May be. I mean, it's tough to say when you go -- right here.
Q. All right. Well, other than this little area here, can we agree that that which follows, the dark blue, obviously is low velocity flow?
A. Well, that may be some low velocity, but this in here is probably aortic regurgitation.

And as I said before, I know you are going frame by frame, but holodiastolic, you know, the way it's a dynamic study, it would be in most. Not necessarily every single frame you may not see it. I concede that. Every single frame you may not see it.

Q. All right. In fact, is there a particular portion of the study where you attempt to confirm whether it lasts throughout the entire cycle in an echocardiogram?
A. I don't understand that question.
Q. Well, if you can't, based on color Doppler, are there other techniques in the process of an echocardiogram whereby a clinician can assess whether or not what they are observing is simply a phenomenon or whether it lasts throughout the cycle or most of the cycle?
A. Well, again, I am sorry. I am not sure what you question is.
Q. Are you familiar with spectral Doppler?
A. Yeah, of course.
Q. Isn't that the means by which you confirm?
A. I think that -- I think that when you look at aortic regurgitant and you say holodiastolic, it's most, if not all, of the cycle. But going frame by frame, you may not see it on every single split second because the heart is dynamic, motion, and you may not see it on every single.
Q. Let's go to frame 25. Do you see what you contend to be a diastolic jet?
A. Yes.
Q. All right. Frame 26, it's gone, isn't it?
A. Just about.
Q. Next frame, 27. Next frame, 28. Next frame, 29. Next frame, 30, 31. Are we now through the end of the cycle, the diastolic cycle, Doctor?
A. I am not sure if the mitral valve is still open or not.
Q. Okay. Next frame, 32. Next frame, 33. Doesn't it appear the mitral valve is now closing?
A. It looks like it's closing, yeah.
Q. 34?
A. Closed.
Q. And it's closed?
A. Right.
Q. Doctor, when I review, then, other than frame 24 and 25, you didn't see a diastolic jet, did you, the two that we just mentioned?
A. Right.
Q. Okay. And I think I have reflected there about fifteen frames, only two of which you could identify what you contend is a regurgitant jet.

Let's go to -- quickly to -- let's go to the still frames, page 14 from the parasternal long axis view. This is what you cited to the court. And this is what you contend -- or do you contend that that is, in fact, evidence of regurgitant jet?
A. Yes, I do.
Q. And do you contend that that measurement there is reasonable, as opposed to being measured much more proximally to the orifice?
A. I think that measurement is reasonable.
Q. Let's look at page -- and the gain there is again 18, is it not?
A. Yes.
Q. Is that -- all right. Let's go to page 15. Now, sir, in that particular frame you see where they made the measurement?
A. Yes.
Q. Doesn't that look to be overtraced?
A. It is a bit overtraced, yes.
Q. All right, sir. And here again, let's go to page 16. That's the third frame that's cited by you in your certificate.
Again, Doctor, can you tell that that's a regurgitation jet, versus simply an artifact?
A. I think that's probably part of the regurgitant jet. I wouldn't rely on where they measured it, though.
Q. Okay. You think it's overtraced again, do you not?

Dr. Chen's criticisms of Dr. Jacob are devastating.

> Dr. Jacob relies on images on Pages 12, 13, 14, 15, and 16 of the DICOM to support his conclusion that there is FDA Positive AR present on this study. He relies on quantifications from four of these pages of the DICOM to assert that the JH/LVOT ratios are greater than 10%, but he does not provide any specific JH or LVOT measurements, or any specific ratios. Indeed, other than stating that the ratios were greater than 10%, Dr. Jacob does not even state the degree of FDA Positive AR (mild, moderate, or severe) that he asserts is present. I have re-reviewed the study in its entirety, with particular attention to the pages mentioned.
>
> Page 12 is a parasternal view with excessively high color Doppler gain (GN 5/18 on color gain scale) producing excessive color artifacts and background noise, especially in the tissues. Even with these limitations, there is no clear evidence of an AR jet lasting throughout most or all of diastole. There is a color cluster that lasts only 2-3 frames of diastole at most among excessive color artifacts with high color Doppler gain.
>
> Pages 15 and 16 are still frames of the parasternal view with color Doppler. There are amorphous color clusters which do not have the typical AR jet appearance on these Pages.
>
> Pages 13 and 14 are identical frames with and without the technician's JH measurement of a color cluster. Due to the high color Doppler gain, I cannot confirm whether this color cluster is a true AR jet or merely artifact.

A. Also -- yeah, and as far as where it is in reference to the valve. You don't see the valve well. But I wouldn't rely on this tracing, and it is a bit overtraced, yes.
Q. All right. Well, you can't see the valve, but you can tell that that measurement is made pretty far distally from where you would think the valve would be, would you not?
A. Agreed.

> However, in real-time images there is no definite AR jet present.
>
> Furthermore, on Pages 18, 19 and 20 of the parasternal long axis view, no AR jet is visualized despite the high color Doppler gain (gain slightly lower than Page 12) and relatively low Nyquist velocity (51 cm/s[ec]).

The Court finds that Wyeth has easily satisfied the Court that this echocardiogram was not conducted in a technically adequate manner such that reliable medical conclusions regarding the presence and severity of valvular regurgitation could be drawn from it. The 2-D and color gain are excessive. Moreover, no reasonable physician could conclude, based on a review of this echocardiogram, that Lindsay has MAR.

V. ROBERT J. LINDSTROM

Lindstrom relies on a November 14, 2002 echocardiogram and report of Dr. Arthur Schwartzbard. Dr. Schwartzbard found Lindstrom had MAR using CAS criteria -- JH/LVOT = 15%. Dr. Schwartzbard measured a RJA of 2.4 cm^2 and a LAA of 20.1 cm^2 and evaluated this as "mild to moderate mitral regurgitation." The measured RJA/LAA computes to 11.9%. Nevertheless, it appears that a claim of MMR was made as well. Dr. Schwartzbard noted that the study quality was "fair."

The November 14, 2002 echocardiogram was reviewed by three (3) experts: Dr. Chen, Dr. Ong and Dr. Jacob. Both Drs. Ong and Chen found that this echocardiogram was not conducted in a technically adequate manner such that reliable medical conclusions regarding the presence and severity of valvular regurgitation could be drawn from it. Dr. Ong noted that "[t]he Nyquist limit setting is low, creating excessive aliasing artifact. There was also high color gain setting, resulting in the presence of color flow artifact." Dr. Chen concurred. The Nyquist limit varied between an unacceptable 41 cm/sec and a barely acceptable 51 cm/sec. The color gain setting on this Cypress machine was 18. Color gain ranged up to 21 in the apical 2 and 4 chamber views.

Both Drs. Ong and Chen found no evidence of either FDA positive mitral or aortic regurgitation. As to the MMR claim, Dr. Ong found "[n]umerous real-time pages were present (8, 9, 33, 34, 39, 46, 57, 58, 62, 63, 65, 66) which did not show the same degree of MR as outlined in still-frame pages (37, 38, 47, 48, 60, 61).

This is likely due to the presence of artifact in the still images and inappropriate settings during image acquisition." As to the MAR claim, Dr. Ong found that "even with the current settings, the amount of AR seen appears small." Dr. Chen concurred with both these findings.

Dr. Jacob disagreed. He believed the echocardiogram was "of diagnostic quality with appropriate gain settings and Nyquist limit...." He found MMR with a RJA/LAA = 20% and MMAR with a JH/LVOT = 30%.[16]

---

[16] Dr. Jacob's cross-examination exposed what little support he had for his conclusion.

> Q. All right. Let's go to Robert Lindstrom. Now, with regard to Robert Lindstrom -- let me see your Affidavit -- you have reflected that, in your judgment, from your review, he has moderate mitral regurgitation of 20 percent, and you cite three apical views, pages 36, 56 and 60, as well as frozen frames, page 38 and I believe 61. And you also say that he has FDA positive aortic insufficiency, correct?
> A. Um-hum, yes.
> Q. I will address the aortic insufficiency in a moment. Let's first go to the mitral, mitral valve issue, page 36, please, that you have cited.
> Doctor, as we look at this particular loop, page 36, you see where you have got a Nyquist of 51, do you not?
> A. Yes, sir, I do.
> Q. And would that be fair to characterize that as a minimal level of Nyquist, minimally acceptable level? Even based upon the American Society of Echocardiographic guidelines, that is a minimal level, borderline low level of Nyquist, is it not?
> A. According to their guidelines, the ideal Nyquist -- we talked about that in the beginning -- was 50 to 60.
> Q. Are you familiar with Weyman and with regard to the position stated in Weyman's text with regard to Nyquist limits particularly being between .6 and .9 meters per second? Let's stop one second.
> Pull up FTI 62.12, which is page 245 of Weyman's text. Are you familiar with that statement in Weyman's text?
> A. No.
> Q. Do you agree or disagree with it?
> A. I mean, I think that the ideal Nyquist -- I don't totally agree. I think that it depends on the patient and on the study.
> Q. If one were to look and just randomly inventory the echocardiograms performed at Saint Peter's, even over the last month, one would generally see a Nyquist between .60 and .90, would they not?
> A. .50 and .90, I think so.
> Q. All right. So, you would use a Nyquist down to .50?
> A. I think it depends on the patient. Again, you know, I think it depends on the size of the patient, the depth. But I think probably .5 to .9. You wouldn't see a lot of .5, but you would see some.
> Q. Okay. All right. Now, with regard again to Mr. Lindstrom, in this particular page, page 36, you have got -- you see a lot of speckling in the tissue, indicative of a very high gain, do you not?
> A. Yes, the gain is a bit high.
> Q. In fact, on the monitor reflects the gain to be 21, does it not?
> A. Right.

Q. And then we have a minimal Nyquist of 51, correct?
A. Correct.
Q. Now, that gain certainly would not be consistent with the guidelines you utilize at your lab, would it?
A. It were be a bit high, no.
Q. On a quality review with your sonographers, there would be criticism levied of a gain of that height on this echo, wouldn't it?
A. Yes.
Q. All right. And the reason there would be criticism is that at least, even at your lab, you would not consider that a medically reasonable gain for the taking of an echo such as this, would you?
MR. EASTERBY: Object to form. Asked and answered.
MR. RAMSAY: If I have, I apologize.
Q. Would you?
A. I would want the gain to be lower.
Q. All right. You would not consider it medically reasonable at that level; you would want it lower?
A. I would want it lower.
Q. Doctor, let's go to -- again, looking to see if we have what is really a holosystolic jet, and we can start with frame five.

I pulled at random a cycle. Let's go back to frame four. Doctor, can we agree that on frame four of page 36 it appears that we are just beginning mechanical systole?
A. Yes, I would agree.
Q. Frame five, please. Here again, there is nothing that is really demonstrable there, other than predominantly laminar flow, is there?
A. I agree.
Q. Page six -- I mean frame six. You have there what appears to be some aliasing, correct?
A. Yes.
Q. At least in the portion -- in the upper -- in this frame, in the upper portion of the atrium.
A. Yes.
Q. Radius the lower portion in light.
A. Yes.
Q. Frame seven, do you still see some aliasing there?
A. Yes.
Q. You also see a lot of aliasing in the left ventricle, don't you?
A. Yes.
Q. How do you explain that, high gain?
A. Could be turbulence or high gain.
Q. High gain. It's difficult to even see where the valve is, isn't it?
A. Yes, it's difficult to see the valve. The valve is probably right here.
Q. You see it there, but as we go across, it appears to be a continuous artifact all the way up into the left ventricle, does it not?
A. Yes.
Q. Frame eight, in that particular frame it appears that if there is aliasing, all of it is in the left ventricle, is it not?
A. Well, there is some in the left atrium as well. Both, both chambers.
Q. Would you consider this indicative of mitral regurgitation?
A. Not on this.
Q. All right. Next frame. Frame nine, we have aliasing, but most of it -- in fact, all of it is now in the left ventricle, is it not?
A. No, there is some aliasing in the left atrium as well.
Q. Show it to us, please.

A. Right here and here.
Q. Well, there is no aliasing that would be -- that is emanating from the valve itself, is there?
A. I can't tell.
Q. All right. Next frame. We still have aliasing in the left ventricle, but there is nothing really demonstrated with regard to the left atrium, is there, on frame 10?
A. I agree, right, there is nothing in the left atrium.
Q. Let's go to page 56. Is that page 56? What view is that, Doctor? It's cited by you.
A. Apical.
Q. Apical what?
A. Two-chamber.
Q. Does it appear to be that that particular page has been flipped?
A. Flipped?
Q. Flipped, such that the left side of the heart is demonstrated as one looks at the monitor on the left side of the page.
A. I don't think so.
Q. -- of the page, as opposed to the right side.
A. No, I don't think it's been flipped.
Q. Okay. In this particular case again you now have got a gain of 22 with a minimal Nyquist of 51, correct?
A. Yes.
Q. And you've got speckling all through the tissue, correct?
A. Yes, there is speckling in the tissue.
Q. You can't see the valve in that page, can you?
A. I can.
Q. Do you see what you contend to be regurgitant flow that lasts throughout most, if not all, of systole?
A. I think there is mitral regurgitation right here, right in here.
Q. Does it last? Do you want to play frames?
A. Well, if you want.
Q. When you looked at it, did you certify that you felt that it lasted throughout most, if not all, of systole?
A. Yes.
Q. Let's to go page 38, which is the still frame. Here again with regard to the still frame, Doctor, as a result of the noise and artifact you see aliasing all in the left ventricle as well, do you not?
A. Yes, I do.
Q. In fact, you really can't tell as one looks at this particular frozen frame exactly where the valve is, can you?
A. Can't tell exactly.
Q. That's page 38 that you cited. In this particular case, do you know what the LAA measurement was?
A. I didn't write -- I don't have it in front of me. I don't remember.
Q. And if I've asked you this, I apologize. Is it ever appropriate to attempt to take the left atrial area measurement at the beginning of systole or even in mid-systole?
A. Not mid-systole, no. It should be right before the valve opens.
Q. In systole? All right. Let's go to the aortic insufficiency. And you have certified to the court that you believe that there was FDA positive aortic insufficiency 30 percent, and you cited pages 8, 9, 13 and 16 from the peristomal long axis view, as well as still frames, pages 11, 12 and 14.

Let's go to -- we agreed that in all these frames we looked at, notwithstanding the excessive gain, the Nyquist was at best at a minimal level at 51?

Dr. Chen's criticisms of Dr. Jacob's opinions are devastating. Dr. Chen found:

> Dr. Jacob relies on real-time images of parasternal views on Pages 8, 9, 13, and 16 of the DICOM to support his conclusion that there is moderate AI present on this study. He relies on JH/LVOT measurements on Pages 11, 12, and 14 to reach a ratio of "approximately 30%." (Dr. Jacob also refers to an apical view on Page 65, but

---

A. Yes.
Q. Let's go to page eight. Doctor, can you think as we look at this particular page that you have cited to the court -- you have got a Nyquist of 41 and a gain of 18, and of course you see speckling in the tissue, do you not?
A. Yes, I do.
Q. Doctor, can you think of any rationale or reason, especially in a PLAX view, for ever having a Nyquist of only 41, a justification for it?
A. It depends on the patient, depends on the body habitus.
Q. This patient. Well, can we agree the PLAX view is the most superficial depth?
A. Yes.
Q. And here again we know that Nyquist -- would you disagree even at a Nyquist -- I mean, at a level of 19 centimeters one easily would be able to obtain a Nyquist level at least in the 50s?
A. I agree.
Q. Then can you give me any justification you can think of for ratcheting down a Nyquist of .41?
A. No.
Q. Doctor -- that's page eight, simply so that we go through. You have also cited page nine. Let me have page nine. Simply, here again, we have got a gain of 18 and a Nyquist of .41, correct?
A. Yes, sir.
Q. Page 16. Again, we have got a gain of 18 and the Nyquist now is up to the minimal level of 51, correct?
A. Right.
Q. Can you think of any reason why the depth could not have been decreased in the PLAX view such that one would get a higher Nyquist?
A. I didn't see the patient. I don't know. I can't answer that question, really.
Q. All right. Let's go to page 45 quickly. Again, I am going to have you look at the continuous wave. And we have already established the purpose of the continuous wave is to determine whether one is really dealing with a high velocity flow.
A. Right.
Q. And whether or not that flow, if any, lasted most of the cycle?
A. Right.
Q. With regard to Mr. Lindstrom.
A. Right.
Q. And that's from the apical five-chamber view, correct?
A. Yes.
Q. This continuous wave demonstrates neither a holodiastolic flow, nor a high velocity flow, does it?
A. Does not.

since the PLAX view is available on this study, the apical views are not relevant for assessment of AI according to the settlement criteria.) I have re-reviewed the study in its entirety, with particular attention to the referenced pages.

Page 13 is a still frame image and is not a real-time cine loop, as misidentified by Dr. Jacob. Pages 8 and 9 are parasternal views with an unacceptably low Nyquist velocity 41 cm/s[ec]) at an imaging depth of 19 cm and high color Doppler gain settings. Page 16 is the parasternal long axis view with a relatively low Nyquist velocity of 51 cm/s[ec] and high color Doppler gain settings, preventing a reliable assessment of the degree of AR. Even with the high color Doppler gain settings, there is a tiny broken AR jet, which is so tiny that the proximal portion of the jet just below the aortic valve is missing or drops-out (below color Doppler spatial resolution which is about 1 mm) during most of diastole. Therefore, AR is trace at most.

Dr. Jacob relies on real-time images on Pages 36, 56, and 60 of the DICOM to support his conclusion that there is moderate MR present on this study. He relies on RJA/LAA measurements on Pages 38, 40, and 61 to reach a ratio of 20%. I have re-reviewed the study in its entirety, with particular attention [to] these pages.

Page 60 is a still-frame image and is not a real-time cine-loop, as misidentified by Dr. Jacob. Pages 36 and 56 are apical views with excessively high color Doppler gain settings, producing excessive artifacts and exaggerating the MR jet size. Therefore, the degree of MR cannot be reliably evaluated.

Page 38 is an atypical 4-chamber view in between an apical 4- and 5-chamber view. On Page 38, which Dr. Jacob relies on for his measurement of moderate MR, there is an improper MR overtracing of an MR jet which

> is mixed with color cluster/artifacts in the LVOT. Page 40 is a slightly undertraced LAA by the technician.
>
> On Page 61, which Dr. Jacob relies on for his measurement of moderate MR, there is an improper overtracing of an "MR" jet which is mixed with color cluster or low velocity flow in the LV above the mitral valve. Due to the high color Doppler gain, this low velocity flow and color artifact is exaggerated and mixed with an MR jet.

The Court finds that Wyeth easily established that this echocardiogram was not conducted in a technically adequate manner such that reliable medical conclusions regarding the presence and severity of valvular regurgitation could be drawn from it. The color gains were outrageously high and the Nyquist limits inexplicably low. Moreover, no reasonable physician reviewing this echocardiogram could come to the conclusion that Lindstrom has either MMR or MAR.

W. GERI LOFTHOUSE

Lofthouse relies on a June 11, 2002 echocardiogram and report of Dr. Robert M. Applebaum. Dr. Applebaum found Lofthouse had MAR using CAS criteria -- JH/LVOT = 20%. Dr. Applebaum noted the study quality to be "fair."

The June 11, 2002 echocardiogram was reviewed by three (3) experts: Dr. Chen, Dr. Ong and Dr. Jacob. Both Drs. Ong and Chen found that this echocardiogram was not conducted in a technically adequate manner such that reliable medical conclusions regarding the presence and severity of valvular regurgitation could be drawn from it. According to Dr. Ong, "[t]here [were] excessive color gain settings and relatively low Nyquist limits settings, causing the appearance of color flow artifact and aliasing to be present." Dr. Chen concurred. The Cypress machine was used here and the color gain setting was 17. Both physicians agreed that Lofthouse did not have MAR based on their review of this echocardiogram. Dr. Chen's comments are emblematic of their findings: "Part A regarding technical inadequacy that makes assessment of degree of aortic regurgitation unreliable using the JH/LVOT ratio. In real-time images, there appears to be a tiny, non-continuous AR jet intermingled with artifacts, indicating trace AR at most. However, no measurements should be made on this study."

Dr. Jacob disagreed. In his view, "the echo [was] of diagnostic quality with appropriate gain and Nyquist settings...." Dr. Jacob found MAR in the PLAX views. Dr. Jacob agreed with the sonographer's measurements indicating a JH/LVOT of 15%-18%. On cross-examination, Dr. Jacob acknowledged he could not see the valve annulus in the frames where measurements were made and conceded that CW Doppler failed to confirm a holodiastolic phenomenon.[17]

---

[17] Dr. Jacob's cross-examination is set out in full below.

> Q. Let's go to Geri Lofthouse. Now, with regard to Mr. or Miss Lofthouse, you have cited two frames from the peristomal long axis view as demonstrating, in your judgment, aortic insufficiency of 15 to 18 percent.
>
> Let's look at page six, please. Doctor, here again we have got a minimal Nyquist of 51, correct?
>
> A. Yes.
>
> Q. And yet you have got a gain that is set at 17, such that you see speckles, stars, all in the soft tissue, correct?
>
> A. Yes.
>
> Q. And that again in your lab would not be acceptable, would it?
>
> A. No.
>
> Q. Now, even with this excessive gain and minimal Nyquist -- let me see if I can go quickly -- let's go to page eight, which is the frozen frame. And I apologize; I am jumping around, but I am trying to move through what are a lot of these.
>
> Here again, is this a measurement you would have relied upon? You've cited it in your Certification, page eight.
>
> A. No.
>
> Q. And the reason for that is that's not even a high velocity flow at all, is it?
>
> A. Right.
>
> Q. Let's go to page nine. Doctor, here again I am not sure what they are measuring, but can we agree that what is demonstrated on this second frame that you've cited again is not a high velocity flow? It's either dark blue or light blue, hardly mosaic?
>
> A. I think there is some high velocity flow, but I think the measurement is overmeasured.
>
> Q. You think the measurement is overmeasured?
>
> A. Right.
>
> Q. Well, can you tell me from looking at this particular -- number one, can you tell me where the valve is?
>
> A. Not exactly, no.
>
> Q. Well, isn't it important and don't you -- weren't you trained that before assessing the jet height one should be able to visualize the valve structure?
>
> A. Yes.
>
> Q. Otherwise, one doesn't know where one is in relationship to the orifice, correct?
>
> A. Right.
>
> Q. And on this particular frame you can't tell us that, can you?
>
> A. No.
>
> Q. And those are the only two frozen frames you have cited to the court?
>
> A. Right.
>
> Q. Page eight and nine.

Dr. Chen criticized Dr. Jacob's observations on Lofthouse and the Court agrees with him.

> Dr. Jacob relies on images in the PLAX view on Pages 6 and 7 of the DICOM to support his conclusion that there is mild AR present on this study. (Dr. Jacob also references an apical view, but this is not pertinent for assessment of JH/LVOT ratio according to the settlement criteria, because the PLAX view is available.) Dr. Jacob relies on measurements on Pages 8 and 9 in the PLAX view for his conclusion that the JH/LVOT ratio is 15-18%, but he does not provide any specific JH or LVOT measurements. I have re-reviewed the study in its entirety, with particular attention to the pages mentioned.
>
> Pages 6 and 7 are parasternal long axis views with excessively high color Doppler gain settings and relatively low Nyquist velocity of 51 cm/s[ec] at an imaging depth of 19 cm (although it can be imaged with a depth of 16 cm). High color Doppler gain settings produce excessive color artifacts and exaggerate the true regurgitant jet size, rendering this study unreliable for assessment of the degree of AR. On Page 8, the technician measured low velocity LVOT flow, not a true AR jet even though AR appears to be present. Due to the high color Doppler gain setting, Page 9 shows a cluster similar to an AR jet which is mixed with color artifacts. The technician improperly measured the "AR" jet by placing the cursor far beyond the color cluster borders.

The Court finds that Wyeth has established that this echocardiogram was not conducted in a technically adequate manner such that reliable medical conclusions regarding the presence and severity of valvular regurgitation could be drawn from

---

Let's go to page 25, which is the continuous wave. And again, Doctor, I realize that there is no test that's 100 percent, but that appears to be from the apical five-chamber, does it not?
A. Yes, it do.
Q. And here again, if the continuous wave on page 25 is to be believed, we neither have a high velocity jet nor -- we don't have anything there that would be suggestive of aortic regurgitation, do we?
A. No, we do not.

it. The color gain was set far too high. In any case, for the reasons set forth above, no reasonable physician could conclude that Lofthouse has MAR based on this echocardiogram.

X. PATSY MEDEL

Medel relies on a May 1, 2002 echocardiogram and report of Dr. Paul R. Chen. Dr. Chen found Medel had MMR using CAS criteria -- RJA/LAA = 20%. Dr. Chen noted "left atrial enlargement."

The May 1, 2002 echocardiogram was reviewed by three (3) experts: Dr. Schwartz, Dr. Ong and Dr. Lazar. Dr. Ong found that this echocardiogram was not conducted in a technically adequate manner such that reliable medical conclusions regarding the presence and severity of valvular regurgitation could be drawn from it. He found the color gain settings high in the apical views and a low Nyquist limit of 51 cm/sec. Drs. Schwartz and Lazar found the echocardiogram to be technically adequate though Dr. Schwartz complained about the relatively low Nyquist limit.

Both Drs. Ong and Schwartz found no significant mitral regurgitation. Both thought that the areas traced on the echocardiogram media were closing volume. Dr. Schwartz put it this way:

> THE WITNESS: There are a bunch of tracings. All of them are of closing volume. In this case to me real time it's the most revealing. You cannot look at these real time and say there's moderate MR.
> THE COURT: There's one or two --
> THE WITNESS: Frame. I mean, it's closing volume as we described many times.
> THE COURT: It looks like terribly over traced.
> THE WITNESS: No clinician would look at this and say that there's moderate MR. I think you could argue with this any MR or mild MR but certainly not moderate.

Dr. Lazar claimed Medel has MMR based on a LAA measurement of 16.8 cm^2 and two (2) RJA tracings -- one 4 cm^2 and the other 4.2 cm^2.

The Court has reviewed the echocardiogram. One of the LAAs traced is 19.33 cm^2 and the Court finds that LAA was undertraced. The Court finds that Dr.

Lazar's RJA tracings are significantly overtraced and also represent non-holosystolic phenomenon -- probably closing volume.

The Court finds that Wyeth has shown that no reasonable physician could find that Medel has MMR based on a review of this echocardiogram. The echocardiogram shows non-holosystolic events which probably represent closing volume. In any case, the RJA measurements of Dr. Lazar are significantly overtraced and, when properly traced and compared with the proper LAA measurement of somewhat over 19.33 cm^2, do not compute to a RJA/LAA $\geq$ 20%.

Y. LUCRETIA MEHRABAN

Mehraban relies on a December 10, 2002 echocardiogram and report of Dr. Scott L. Roth. Dr. Roth found Mehraban had MAR using CAS criteria -- JH/LVOT = 19%. Dr. Roth noted that this was a "technically adequate study."

The December 10, 2002 echocardiogram was reviewed by three (3) experts: Dr. Chen, Dr. Ong and Dr. Jacob. Both Drs. Ong and Chen found that this echocardiogram was not conducted in a technically adequate manner such that reliable medical conclusions regarding the presence and severity of valvular regurgitation could be drawn from it. Dr. Chen noted that "[l]ow Nyquist limit velocity (41 cm/s[ec]) and high color Doppler gain settings exaggerate regurgitant jet size on color Doppler flow mapping and render the study unreliable for assessment of valvular regurgitation." Dr. Ong concurred. A Cypress machine was used here with high 2-D gain settings and a color Doppler gain setting of 10. It is important to note that the Nyquist limit of 41 cm/sec was set at a probe depth of 16.2 centimeters. The Nyquist limit could have easily been set at 61 cm/sec on this machine.

Dr. Jacob claimed the gain settings were appropriate and the low Nyquist did not render the study non-diagnostic.[18]

---

[18] The Court adopts Dr. Chen's criticisms of Dr. Jacob's technical measurements of aortic regurgitation.

> As stated in my original report, this echocardiogram is not technically adequate due to an inappropriately low Nyquist limit setting of 41 cm/sec and extremely high color gain settings with excessive color speckling in the static tissues.
>
> Dr. Jacob relies on images in the PLAX view on Pages 7, 8, and 13 of the DICOM to support his conclusion that there is mild AR present on this study. (Dr. Jacob also references two apical views, but these are not pertinent for assessment of JH/LVOT ratio according to the settlement criteria, because the PLAX view is available.) Dr. Jacob relies on measurements on Pages 9, 11, 12,

The Court finds that Wyeth has satisfied its burden to show that this echocardiogram was not conducted in a technically adequate manner such that reliable medical conclusions regarding the presence and severity of valvular regurgitation could be drawn from it. The Nyquist limit of 41 cm/sec and the high gains render the echocardiogram useless in the diagnosis of valvular regurgitation.

Z. KAYLEEN MEIKLE

Meikle relies on an October 8, 2002 echocardiogram and report of Dr. Edward S. Katz. Dr. Katz found Meikle had MMR and MAR using CAS criteria -- RJA/LAA - 21%; JH/LVOT = 19%. Dr. Katz, however, noted that Meikle had "mild to moderate mitral regurgitation." Dr. Katz noted the study quality to be "fair."

The October 9, 2002 echocardiogram was reviewed by three (3) experts: Dr. Chen, Dr. Ong and Dr. Jacob. Dr. Chen found that this echocardiogram was not conducted in a technically adequate manner such that reliable medical conclusions regarding the presence and severity of valvular regurgitation could be drawn from it. According to him,

> [e]xcessively high color Doppler gain settings in the PLAX views exaggerate AR jet size and render the study unreliable for assessment of the degree of aortic regurgitation. There is also relatively low Nyquist limit velocity that exaggerate jet size on color Doppler.

The Court finds that there is high 2-D gain, high color Doppler gain and a marginal Nyquist limit of 51 cm/sec.[19]

> and 51 for his conclusion that the JH/LVOT ratio is 15-20%, but he does not provide any specific JH or LVOT measurements.
>
> I have re-reviewed the study in its entirety, with particular attention to the pages mentioned. I find that Pages 7, 8 and 13 are the PLAX view with unacceptably low Nyquist velocity of 41 cm/s[ec] at an imaging depth of 16.2 cm. In addition, color Doppler gain and 2-D gain settings are too high. On Pages 9, 11 and 12, there are JH measurements made by the technician. Due to the low Nyquist setting, these measurements are improper, making the JH/LVOT ratio unreliable for the assessment of the severity of aortic regurgitation. Finally, Page 51 is the apical long-axis view which is not pertinent for assessment of JH/LVOT ratio according to the settlement criteria, because the PLAX view is available.

[19] The marginal Nyquist could have been raised to 61 cm/sec by the sonographer on this Cypress machine.

Turning to the merits, both Drs. Ong and Chen found neither MMR nor MAR. Dr. Chen, on the MMR claim, noted:

> There is only mild mitral regurgitation by visual assessment and by measurement of RJA/LAA even with relatively low Nyquist velocity that enlarges MR jet. In light of the technical inadequacy noted in Part A, it is not appropriate to rely on measurements made on this study.

Dr. Ong concurred.[20] As to the MAR claim, Dr. Ong computed a JH/LVOT of 11% in the A3C view, though he noted no significant aortic regurgitation in the PLAX views.[21] Dr. Chen was more emphatic that no significant aortic

---

[20] During cross-examination, Dr. Ong was asked to trace Meikle's RJA. In two (2) tracings he arrived at 2.66 cm² and 2.75 cm² which were lower than the sonographer's 2.81 cm² RJA. These measurements all yielded a RJA/LAA < 20%.

[21] Dr. Ong noted that the PLAX views which were available failed to show MAR. His direct examination and cross-examination testimony by Wyeth is set forth in full.

> THE COURT: All right. Kayleen Meikle or Meikle, was her echocardiogram conducted in a technically adequate manner such that reliable medical conclusions regarding the presence and severity of valvular regurgitation could be drawn from it?
> THE WITNESS: Overall, yes. There were some views where the gain setting was high for that view, but I felt that it was possible to identify the regurgitant jets.
> THE COURT: All right. There was a mitral regurgitation claim made. Did you examine the parasternal long axis view -- forgive me -- the apical views in the echocardiogram to determine whether this Plaintiff had FDA positive mitral regurgitation?
> THE WITNESS: Yes, I did.
> THE COURT: What were your findings?
> THE WITNESS: The tracings, actually, exceeded the true edges, meaning, that it encompassed a lot of areas that did not include mitral regurgitation so it overestimated the jet.
> I looked at a number of tracings. I mentioned Page 36 and 38. And, in looking at the truest value, the ratio would be 19 percent at its worse. The other jets were actually less than that.
> THE COURT: All right. Could a reasonable physician with your skill sets reach a different conclusion, that is, could reach a conclusion that this person was FDA positive for mitral regurgitation?
> THE WITNESS: No, I don't believe so.
> THE COURT: All right. You've heard of inter-reader variability. That certainly is a phenomenon which is recognized in your business.
> Could that account for this matter crossing from 19 percent as you said to 20 percent?
> THE WITNESS: It could. It could. But this was the most generous view that I felt was also the most accurate way of measuring those views and I don't believe it can happen.
> THE COURT: So you believe that you gave this the most generous interpretation that you could?
> THE WITNESS: Yes.

THE COURT: All right. So be it.

There was an aortic regurgitation claim made. Did you examine the parasternal long axis view to determine whether that was available?

THE WITNESS: Yes, I did.

THE COURT: What did you find?

THE WITNESS: I found that a number of realtime images, Pages 9, 10 and 12, did not see significant aortic regurgitation but Page 14 did. It was difficult to assess it because of color gain settings in this group of views.

THE COURT: All right. Now, you made a measurement with calipers and found a JH of .4 and an LVOT of 3.5, although as you noted they were what are known as relative units.

There was no attempt to reduce them to actual millimeters or centimeters; is that correct?

THE WITNESS: That's correct, yes.

THE COURT: Why was that, Doctor?

THE WITNESS: The machine I was using did not have the calibrations that normally is found on the tape and so what we did was just use internal measurements within the machine itself.

THE COURT: And, I mean, the relative measurements. The theory is things equal to the same thing are equal to each other. So you could simply make your measurements because if there was any exaggeration in one area, it would exaggerate the other area and vice versa.

THE WITNESS: Right, right.

THE COURT: All right. You found 11 percent and that constitutes FDA positive aortic regurgitation, correct?

THE WITNESS: Yes.

* * * *

EXAMINATION BY MR. WHEELER

And we'll first address Miss Meikle where you were questioned by Mr. Easterby a moment ago.

Before we leave the question of the mitral claim in that case, am I correct, Dr. Ong, that based upon your recalculation done here in open court today that the maximum regurgitant jet area you could find based upon the frame referenced by Mr. Easterby would be 2.75 centimeters squared?

A. Yes.

Q And, by my math, based upon the left atrial area that was showed to you by Mr. Easterby, that would calculate to a regurgitant jet in comparison to the left atrial area of a quantification of about 18 percent, does that sound right to you?

A. It sounds --

THE COURT: That's about right.

A. It sounds right.

Q. And so the record will be clear, Dr. Ong, you made these calculations here in open court and privately in your own laboratory in the face of what you found to be a slightly high gain?

A. Yes.

Q. All right. Turning to Miss Meikle's aortic regurgitant claim, Dr. Ong, the Court asked you some questions this morning about whether or not the parasternal long axis view was available on this study and I believe you indicated that it was?

A. Yes, it was available.

Q. And I believe your testimony here today, Dr. Ong, is that those views of this study were diagnostic but did not show evidence of aortic regurgitation?

A. In the parasternal long axis view, I found only one page that showed some aortic regurgitation, but I could not verify it because of the gain settings.

regurgitation was seen. "[E]ven in the PLAX views with slightly lower color gain (though still too high), there is no definite or continuous AR jet. 'AR' jets measured by the technician are not real AR jets (one is even in systole on the EKG after QRS wave)."

Dr. Jacob disagreed that the echocardiogram was technically inadequate. He found the echocardiogram was of "diagnostic quality with appropriate gain and Nyquist settings." He concluded that Meikle has MMR with a RJA/LAA of 23%. He also concluded that Meikle has MAR with a JH/LVOT of 20%.[22]

> Q. And, so the record will be clear, Dr. Ong, the calculation that you made of aortic regurgitation of 11 percent was done in an apical view?
> A. That's correct, yes.
> Q. And you would not be able to tell the Court today on the PLAX views that were available that this Plaintiff did, in fact, have FDA positive aortic regurgitation, correct?
> A. Correct, yes.

[22] Dr. Chen's criticisms have resonance and the Court accepts them. They are set out below.

> As stated in my original report, this echocardiogram is not technically adequate to draw reliable medical conclusions regarding the severity of any regurgitation present, due to high gain settings giving the appearance of excessive speckles or noise. In addition, a relatively low Nyquist limit setting of 51 cm/sec exacerbates the exaggeration of the jet due to the high gain setting.
>
> Dr. Jacob relies on real-time images of the PLAX view on Page 14 of the DICOM to support his conclusion that there is mild AI present on this study. He relies on JH/LVOT measurements in PLAX images on Pages 13 and 15 to reach a ratio of 20%. (Dr. Jacob also refers to apical views on Pages 41, 44, and 45, but since the PLAX view is available on this study, the apical views are not relevant for assessment of AI according to the settlement criteria.) I have re-reviewed the study in its entirety, with particular attention to the referenced pages.
>
> Page 14 is a parasternal long axis view with high color Doppler gain settings that exaggerate regurgitant jet size, rendering any assessment of the degree of aortic regurgitation by JH/LVOT unreliable. On Page 13, the technician measured an amorphous color cluster which does not have a typical AR jet appearance. Page 15 is the technician's LVOT measurement which is slightly undermeasured.
>
> Dr. Jacob relies on real-time images on Pages 30, 31, 33, 35, 37, 56, 57, and 59 of the DICOM to support his conclusion that there is moderate MR present on this study. He relies on RJA/LAA measurements on pages 34, 36, 38, 40, and 58 to support his conclusion of a ratio of 20-23%. I have re-reviewed the study in its entirety, with particular attention to these pages.
>
> I find that Pages 30, 31, 33, 35, 37, 56, 57 and 59 are apical views with a relatively low Nyquist velocity of 51 cm/s[ec] at an imaging depth of 16.2 cm. On these Pages, the MR jet lasts 3-4 frames of 7-8 systolic frames, but the MR jet appears small and consistent with mild MR in real-time images.

The Court finds that Wyeth has met its burden and established that this echocardiogram was not conducted in a technically adequate manner such that reliable medical conclusions regarding the presence and severity of valvular regurgitation could be drawn from it. The 2-D and color gains were too high and the Nyquist limit was suspect. The Court also finds that no reasonable physician could conclude the Meikle has either MMR or MAR based on a review of this echocardiogram. As to Dr. Ong's measurement of 11% in the A3C view, the Court finds the PLAX view was available; and therefore was required under the CAS.

AA. COLLEEN MILCHAK

Milchak relies on a June 24, 2002 echocardiogram and report of Dr. Arthur Schwartzbard. Dr. Schwartzbard found Milchak had MAR using CAS criteria -- JH/LVOT = 15%. Dr. Schwartzbard noted that the study quality was "fair."

The June 24, 2002 echocardiogram was reviewed by three (3) experts: Dr. Chen, Dr. Ong and Dr. Jacob. Dr. Chen found that this echocardiogram was not conducted in a technically adequate manner such that reliable medical conclusions regarding the presence and severity of valvular regurgitation could be drawn from it. Dr. Chen reported that the "[c]olor Doppler gain setting was too high."[23] Dr. Ong agreed that "the color gain settings [were] high" but believed that FDA positive aortic regurgitation could be visualized on this echocardiogram. Dr. Ong measured the JH/LVOT = 18%.

Dr. Jacob found the echocardiogram to be "of diagnostic quality with appropriate gain and Nyquist settings." Dr. Jacob measured a JH/LVOT = 15%.[24]

> On still frame images on Pages 34, 36, 38 and 58, the MR jet is overtraced by the technician. Particularly, on Page 58, the technician overtraced the MR jet beyond the jet borders and included a region of PISA on the LV side of the mitral valve. If the MR jet is traced properly, the RJA is 2.59 cm² (Exhibit 11). I also retraced the MR jet on Page 34 yielding an RJA of 2.38 cm² (Exhibit 12). The LAA on Page 40 was improperly undermeasured by the technician and not measured at its maximal dimension. The maximal LAA, taken at end-systole, is 18.41 cm² on Page 29 (Exhibit 13), yielding an RJA/LAA of 12.9-14%. Therefore, the MR is mild on Ms. Meikle's echocardiogram.

[23] The gain setting on this Cypress machine was 17.

[24] Dr. Jacob acknowledged on cross-examination that the JH he measured was distal to the valve annulus which he could not visualize. Dr. Chen made that point in his reply certification which, in relevant part, is reproduced below.

> Dr. Jacob relies on real-time images of the PLAX view on Page 3 of the DICOM to support his conclusion that there is mild AI present on this study. He relies on JH/LVOT measurements on Pages 4, 5, and 6 to reach a ratio of "approximately 15%." I have re-reviewed the study in its entirety, with particular attention to the referenced pages. I find that Page 3 is a parasternal

The Court finds that Wyeth has failed in this case to establish that this echocardiogram was not conducted in a technically adequate manner such that reliable medical conclusions regarding the presence and severity of valvular regurgitation could be drawn from it. The Court reviewed this echocardiogram and agrees that it is of relatively poor quality, as are virtually all of the echocardiograms in issue here. However, crediting the testimony of Dr. Ong here, the Court finds that a reasonable physician could find that Milchak has MAR based on review of this echocardiogram.

BB. CASSONJA MILLER

Miller relies on an October 24, 2002 echocardiogram and report of Dr. Edward S. Katz. Dr. Katz found Miller had MMR using CAS criteria -- RJA/LAA = 34%. Dr. Katz noted there was "minimal left atrial enlargement" and the study quality was "fair."

The October 24, 2002 echocardiogram was reviewed by three (3) experts: Dr. Marino, Dr. Ong and Dr. Jacob. All three (3) physicians found the echocardiogram was technically adequate. Dr. Marino did find the quality of the echocardiogram was marginal.

> The color Doppler gain is set somewhat high on this study, as evidenced by the color sparkling in the tissue. Additionally, the Nyquist level is set at 51 cm/sec, which is borderline low. Although the study is still interpretable, the combination of a borderline low Nyquist level and a high color gain setting can exaggerate the severity of regurgitation, if any. As a result, any measurements on this study are suspect.

The Court notes that the Cypress machine was used with a high gain setting of 16. This was, at best, a marginal quality echocardiogram.

Both Drs. Ong and Jacob found that Miller has MMR. Dr. Ong noted that there were "multiple real-time and still-frame images available to substantiate this

---

long-axis view with excessively high color Doppler gain settings, preventing a reliable assessment of the degree of AR. On Pages 4-6, the technician improperly measured the JH. I find that in addition to the extremely high color Doppler gain settings with excessive color artifacts, the technician failed to measure the JH just below the aortic valve and placed the cursors beyond the purported jet edges.

(MMR) claim." Dr. Jacob also found multiple images supporting a RJA/LAA of 30%.

Dr. Marino disagreed. He claimed the "purported regurgitation ... [was] not holosystolic and is not true mitral regurgitation." He also argued that the purported jets that Jacob measured were overtraced.

The Court finds that Wyeth has failed to establish that this echocardiogram was not conducted in a technically adequate manner such that reliable medical conclusions regarding the presence and severity of valvular regurgitation could be drawn from it. The Court finds that this marginal quality echocardiogram could support a reasonable medical conclusion that Miller has MMR.

CC. MATT MONICA

Monica relies on an August 30, 2002 echocardiogram and report of Dr. Stanley S. Schrem. Dr. Schrem found Monica had MMAR using CAS criteria -- JH/LVOT = 32%. Dr. Schrem noted that the study quality was "fair." He also noted "mild left ventricular dilatation."[25]

The August 30, 2002 echocardiogram was reviewed by three (3) experts: Dr. Marino, Dr. Ong and Dr. Jacob. Both Drs. Ong and Marino found that this echocardiogram was not conducted in a technically adequate manner such that reliable medical conclusions regarding the presence and severity of valvular regurgitation could be drawn from it. Dr. Marino explained that:

> The Nyquist level is set inappropriately low at 41 cm/sec, making this study technically inadequate. A low Nyquist level can exaggerate the degree of any regurgitation that may be present and can also produce artifacts that could later be misinterpreted as regurgitation. Therefore, no medically reliable conclusions can be made from this study.

Dr. Ong concurred. The Cypress machine was used here and the color gain was set at 15. Both experts felt the echocardiogram was so technically flawed that no useful medical information could be gleaned from its review.

[25] Dr. Jacob claimed that Monica has MMR with a RJA/LAA = 30%. The record clearly indicates that no MMR claim was made in the first place.

Dr. Jacob disagreed. He found the study was of diagnostic quality. For the reasons already discussed in this Letter Opinion, the Court rejects Dr. Jacob's opinion as not credible.

The Court finds that Wyeth has easily satisfied its burden to show that this echocardiogram was not conducted in a technically adequate manner such that reliable medical conclusions regarding the presence and severity of valvular regurgitation could be drawn from it. The Nyquist limit of 41 cm/sec is outrageously low[26] and the color Doppler gain setting was far too high. No meaningful medical information can be gleaned from this echocardiogram.

DD. ALFONSO MONSIVAIS

Monsivais relies on an October 15, 2002 echocardiogram report of Dr. Charles F. Dahl. Dr. Dahl found Monsivais had MAR using CAS criteria -- JH/LVOT = 20%. Dr. Dahl noted "left ventricular hypertrophy."

The echocardiogram was reviewed by three (3) experts: Dr. Marino, Dr. Ong and Dr. Jacob. All three (3) physicians found the echocardiogram was technically adequate. Both Drs. Marino and Ong noted that the color gain was high. Dr. Marino observed

> [t]he Nyquist level is set at 51 cm/sec which is borderline low. At times, the color Doppler gain is set excessively high (i.e. pages 8 and 15), as evidenced by the color sparkling in the tissue. Although the study is interpretable, the combination of the borderline low Nyquist setting and the high color gain setting can exaggerate the degree of regurgitation, if any, making any measurements on this study suspect.

The Cypress machine was used here and the gain setting was high at 17.

Both Drs. Ong and Jacob determined that Monsivais has MAR. Dr. Ong measured a JH of .3 cm and a LVOT of 2.7 cm, yielding a JH/LVOT of 11.1%.[27] Dr. Jacob measured JH/LVOT ratios between 12-15%.

---

[26] There was absolutely no justification for a Nyquist limit of 41 cm/sec where the probe depth was 16 centimeters. Obviously, the Nyquist could have been set to 61 cm/sec if the sonographer had chosen to do so.

[27] Dr. Ong noted this was an average of two (2) measurements that he made. He could not tell the parties what the individual constituents of the average were.

Dr. Marino disagreed. In his view, "[t]he purported regurgitation is so small, that I would never measure it. By eyeball, it is clearly trivial and is certainly not mild. Additionally, the purported JH measurements are overtraced to include non-aliased flow and black signal." However, on cross-examination he conceded that medical professionals could reasonably diagnose whether Monsivais has MAR.[28]

The Court finds that Wyeth has failed to demonstrate that no reasonable medical opinion that Monsivais has MAR could be made from the echocardiogram here. The technical quality of this echocardiogram is marginal, but the three (3) experts here found that reliable medical opinions could be based on its review.

---

[28] Dr. Marino's testimony on this point is reproduced below.

> Q. In this case, Doctor, Dr. Jacob testified in his certification and I believe in his deposition that he found a Singh ratio between 12 and 15 percent for this particular patient, correct? And I am assuming you read Dr. Jacob's --
> A. Yes, I did. Yes, I did. I cannot remember off the top of my head what he said it was, any percentage.
> THE COURT: You can look at any of these documents. Do you have it?
> THE WITNESS: I think I do.
> THE COURT: If you have it, go to it. And I don't know how anybody can remember all of it.
> Q. Page 10 he said --
> A. He said 12 to 15. Let me see. Yes, 12 to 15 percent.
> Q. And I believe Dr. Ong found a JH over LVOT of 11 percent. Do you see that, Doctor, do you have that in front of you?
> A. Yes.
> Q. Isn't it true that for this particular Plaintiff that inter-reader variability would account for the difference in opinion between you, Dr. Jacob and Dr. Ong?
> A. There could be.
> Q. Meaning that Dr. Ong and Dr. Jacob in making their determinations were behaving in a medically reasonable fashion?
> A. Well, I think they would had to have considered it was over gain but they could of.
> Q. Well, Doctor, like you I think they indicated that this study was technically adequate, correct?
> A. Yes.
> Q. So the question again is, they could in making their determinations at least in your opinion have been behaving in a medically reasonable fashion, true?
> A. Well, I would not consider it reasonable to call it that level.
> Q. Right, I understand that's your opinion for your personal view. The question is a little bit different.
> You agree that because of inter-reader variability they could be behaving in a medically reasonable fashion in disagreeing with you?
> A. I think were the gains not that high, one could say that.
> Q. But this study is technically adequate in your own admission, correct?
> A. It's technically adequate but it is over gained.

EE. ANN MORGAN

Morgan relies on an October 17, 2002 echocardiogram and report of Dr. Stanley S. Schrem. Dr. Schrem found Morgan had MMR using CAS criteria -- RJA/LAA = 20%. Dr. Schrem noted "mild left atrial dilation" and observed the study quality was "fair."

The October 17, 2002 echocardiogram was reviewed by three (3) experts: Dr. Marino, Dr. Ong and Dr. Dahl. Dr. Ong found that this echocardiogram was not conducted in a technically adequate manner such that reliable medical conclusions regarding the presence and severity of valvular regurgitation could be drawn from it. The color gain was set very high. Dr. Marino found the same problems although he judged the echocardiogram "interpretable."

> The color Doppler gain setting is so high, as evidenced by the color sparkling in the tissue, that this study is almost technically inadequate. Additionally, the Nyquist is set at 51 cm/sec in the apical views, which is borderline low. Although the study is still interpretable, the combination of the borderline low Nyquist setting and the high color gain setting can exaggerate the severity of regurgitation, if any, making the measurements on this study suspect.

The Cypress machine was used here and the gain was set at an incredible 22.

Both Drs. Ong and Marino found no evidence of significant mitral regurgitation. Dr. Ong noted:

> Real-time images (pages 9, 50) show no evidence of significant MR. Page 33 demonstrate some degree of MR, which appears to follow the contour of the interatrial septum. RJA measurements (pages 31, 32, 34-37, 39) surround color flow artifact and not the actual MR jet. A measurement on Page 38 included the ventricular aspect of flow.

Dr. Dahl disagreed, finding the technical quality to be adequate and judging Morgan to have MMR with a RJA/LAA = 22% (RJA = 3.47 cm^2; LAA = 15.96 cm^2).

The Court finds that Wyeth has satisfied its burden to show that this echocardiogram was not conducted in a technically adequate manner such that reliable medical conclusions regarding the presence and severity of valvular regurgitation could be drawn from it. But even if one could put that aside, the RJA measurement by Dr. Dahl is vastly overtraced. Dr. Dahl, in essence, conceded this but excused the measurement of non-alias blood in the right position of the left atrium claiming that this was an eccentric jet moving to the left. His effort to compensate for this by overmeasuring the right side is not medically reasonable.[29]

---

[29] Dr. Dahl's testimony on this point is set out below.

> Q. Okay, Doctor, the RJA you cite to in your certification was 3.4 centimeters squared, correct?
> A. That's correct.
> Q. Is this the source of that measurement?
> A. It is.
> Q. And Doctor, how do you measure or how do you calculate the size of an RJA when you have a jet that is hugging the septum like that? Do you do anything different or just --
> A. No, you still calculate it the same. It's the problem with that method of measuring MR, but it happens to be the main method used in this proceeding.
> JUDGE WALSH: But Doctor, if this was truly an eccentric jet traveling along the left boundary of the left atrial wall, you would never expect to see aliasing and, in fact, there is no aliasing in the entire right side of that view.
> THE WITNESS: It would be a surprise, I agree. Although you might have a jet that goes in more than one direction, but in this view, you do not see -- except for maybe right there, aliasing in some of the rest of that jet. On the other hand, the jet does not capture the jet as it goes further down in some of the other frames, further down the septum.
> JUDGE WALSH: I know, but you can't compensate by,
> basically, tracing nonaliased blood in the right side where you would have no clinical suspicion of evidence of mitral
> insufficiency, could you?
> THE WITNESS: Say that again, if you had no -- we know
> there's some mitral insufficiency.
> JUDGE WALSH: Well, you say that, and I understand what you're driving at, but the -- the display of that mitral insufficiency, according to you is confined to the left atrial wall on the left side of the four chamber apical view. Here you're tracing the entire right side, which has absolutely no aliased blood. I mean at a very low Nyquist, the velocity of the flow away from the transducer is less than 51 centimeters per second, true?
> THE WITNESS: For a portion of it is. Again, you could argue there's aliasing right there, some in here. And you have the laminar flow in there, I agree.
> JUDGE WALSH: I'd be a lot more comfortable, Doctor, if you drew your line along here, which is basically -- and I'll point for the record. Right along here. Even that might be an overestimation, but -- I mean you have no warrant for including the blood at along the right side of the left atrium there, do you?
> A. Well, there is some flow there and it is laminar, though, it's not high velocity, most of it. On the other hand, it has to be said on the other hand that the full jet going along the atrial septum is also not captured on this frame.

Moreover, the evidence is overwhelming that this is not a holodiastolic phenomenon. In short, Wyeth has satisfied the Court that no reasonable physician could find Morgan has MMR based on review of this echocardiogram.

FF. LENORE NAGLE

Nagle relies on a July 17, 2002 echocardiogram and report of Dr. Robin S. Freedberg. Dr. Freedberg found Nagle had MAR using CAS criteria -- JH/LVOT = 17%. Dr. Freedberg noted that the study quality was "good."

The July 17, 2002 echocardiogram was reviewed by three (3) experts: Dr. Marino, Dr. Saric and Dr. Jacob. All three (3) physicians found the echocardiogram to be technically adequate though both Drs. Marino and Saric complained about the high color gains and marginal Nyquist limit of 51 cm/sec. Dr. Marino observed:

> At times, the color Doppler gain is set too high, as evidenced by the color sparkling in the tissue. Additionally, the Nyquist level is borderline low at 51 cm/sec. Although the study is still interpretable, the combination of a high color gain setting and a borderline low Nyquist level can exaggerate the degree of regurgitation, if any, making the measurements on this study suspect.

Dr. Saric concurred as to the color gain settings. The Cypress machine was used here and the gain setting was 19. The Nyquist limit was set artificially low since the probe depth of 16.2 cm permitted a Nyquist in the 60s.

Both Drs. Saric and Jacob concluded that Nagle has MAR. Dr. Saric measured a JH of .238 cm and a LVOT of 1.845 cm, yielding a JH/LVOT of 12.9%. While he noted that his measurements were exaggerated because of the high color gain, in Dr. Saric's view, "reasonable cardiologists [could] ... disagree [as] to whether this is trace or mild AR...." Dr. Jacob was of the view that aortic

---

JUDGE WALSH: But you can't compensate by a wall jet by, basically, assuming that nonaliased flow in an area where you shouldn't clinically see a regurgitant jet is, in fact, a regurgitant jet. That's my point. Fair point.
THE WITNESS: Again, the technician drew this. I didn't.
But I also point out that in other frames, but it's not drawn, but the jet goes further down the septum.

regurgitation was seen in the PLAX view and the A3C view. According to Dr. Jacob, the JH/LVOT = 12-15%.

Dr. Marino disagreed. His disagreement was based mostly on his observation that Nagle's regurgitation was not holodiastolic. He put it this way.

> There is no holodiastolic aliased flow, and therefore no true aortic regurgitation is present on this study. Additionally, the purported JH measurements are overtraced to include non-aliased flow, and, at times, black signal. Spectral Doppler through what appears to be the aortic valve confirms the absence of high velocities that are characteristic of true aortic regurgitation.

The Court finds that Wyeth has failed to establish that no reasonable physician could conclude that Nagle has MAR based on a review of this echocardiogram. While Dr. Marino made valid points about the non-holodiastolic nature of the observed jet, there is sufficient evidence to support the conclusion that Nagle has MAR.

GG. CONSTANCE NUTE

Nute relies on an October 5, 2002 echocardiogram and report of Dr. Scott L. Roth. Dr. Roth found that Nute had MMR and MAR using CAS criteria -- RJA/LAA = 36%; JH/LVOT = 22%. Dr. Roth noted that this was a "[t]echnically adequate study."

The October 5, 2002 echocardiogram was reviewed by three (3) experts: Dr. Marino, Dr. Saric and Dr. Jacob. All three (3) physicians found the echocardiogram to be technically adequate though, according to both Drs. Saric and Marino, "just barely." Dr. Marino summarized those physicians' criticisms as follows:

> At times the color Doppler gain setting is excessively high, rendering most of the pages on this study technically inadequate. However, there are still a few interpretable pages on this study. The Nyquist level is set at 51, which is borderline low. The combination of the borderline low Nyquist level and the high color gain

> setting can exaggerate the severity of regurgitation, if any, making any measurements on this study suspect.

The Cypress machine was used and gains between 8 and 18 were observed.

Both Drs. Saric and Marino found no MMR as was claimed. Dr. Marino noted:

> The purported regurgitation is present only during the last third of systole and is therefore not true mitral regurgitation. Additionally, the transducer is placed at an angle that makes the left atrium appear to be smaller than it actually is. Although the sonographer traces two purported jets, the measured flow labeled "B" on the study is not contiguous with the valve and therefore should not be measured. The purported RJA measurements (labeled "A" on the study) are overtraced to include black signal and non-aliased flow. Spectral Doppler through the mitral valve confirms the absence of holosystolic high velocities that are characteristic of true mitral regurgitation.

Even with a foreshortened left atrial area, Dr. Saric measured the RJA/LAA = 12.4%.

Dr. Jacob saw it differently. He found Nute's echocardiogram to be of "diagnostic quality" with the MMR at approximately 30%. He conceded that the jet observed was seen in only two (2) frames of systole but believed that was due to the heart's movement and not the apparent lack of a holosystolic jet. He did concede that CW Doppler failed to support his MMR claim.

As to the MAR claim, both Drs. Saric and Marino found it to be unsubstantiated. According to Dr. Marino,

> [b]y eyeball, the purported regurgitation is too trivial to measure, and is certainly not mild. Additionally, the purported JH measurements are overtraced to include non-aliased flow. Spectral Doppler through the aortic valve confirms the absence of holodiastolic high

> velocities that are characteristic of true aortic regurgitation.

Dr. Saric concurred that the jet was not more than trivial, even given the high gain settings.

Dr. Jacob again disagreed. In his view, Nute has MAR but his measurements were made in the A3C view. When measuring the PLAX view, Dr. Jacob conceded that no significant aortic regurgitation was seen.

The Court finds that Wyeth has demonstrated that this marginal echocardiogram does not support a claim of either MMR or MAR. The MMR claims fails because the LAA is undermeasured and the RJA is overmeasured. The technically flawed echocardiogram shows the LAA in a foreshortened view. Moreover, the MAR claim fails as well. The measurements were improperly taken in the A3C view. The PLAX view showed nothing beyond trivial aortic regurgitation.

HH. COLLEEN ORTIZ

Ortiz relies on a November 22, 2002 echocardiogram and report of Dr. Robin S. Freedberg. Dr. Freedberg found Ortiz had MMR using CAS criteria -- RJA/LAA = 22%. Dr. Freedberg found the study quality to be "good."

The November 22, 2002 echocardiogram was reviewed by three (3) experts: Dr. Goldman, Dr. Saric and Dr. Dahl. All three (3) physicians judged the echocardiogram to be technically adequate.

Both Drs. Saric and Dahl determined that Ortiz has MMR. Dr. Saric noted that "RJA/LAA is consistent with moderate MR. Also, MR is holosystolic on spectral Doppler images on pages 45 & 47. I have provided the court with jpeg images of these measurements." Dr. Dahl concurred although he had a larger RJA of 4.28 cm^2 and a smaller LAA of 16.15 cm^2, yielding a RJA/LAA = 27%.

Dr. Goldman differed. According to him, "[t]here is no sustained holosystolic flow throughout the cardiac cycle on the echocardiogram. Additionally, continuous wave Doppler (pages 44, 45 and 47) shows no holosystolic signal of mitral regurgitation."

The Court finds that Wyeth has failed to establish that no reasonable physician could conclude that Ortiz has MMR based on review of this echocardiogram. While Dr. Goldman raised a serious issue as to whether the jet observed here is holosystolic, there is enough information in the echocardiogram to support at least a reasonable disagreement as to whether Ortiz has MMR.

II. DOROTHY PARKS

Parks relies on a December 3, 2002 echocardiogram and report of Dr. Edward S. Katz. Dr. Katz found Parks had MMAR using CAS criteria -- JH/LVOT = 25%. Dr. Katz found the study quality to be "fair."

The December 3, 2002 echocardiogram was reviewed by three (3) experts: Dr. Marino, Dr. Saric and Dr. Jacob. Dr. Marino found that this echocardiogram was not conducted in a technically adequate manner such that reliable medical conclusions regarding the presence and severity of valvular regurgitation could be drawn from it. Specifically, he noted

> [t]he color Doppler gain setting is excessively high, as evidenced by the color sparkling in the tissue. Additionally, the Nyquist level is set at 51 cm/sec, which is borderline low. The combination of the excessive color gain setting and the borderline low Nyquist setting can exaggerate the severity of regurgitation, if any, and can also result in color artifacts that may be misinterpreted as regurgitation, rendering this study technically inadequate. As a result, no medically reliable conclusions concerning the presence or severity of aortic regurgitation, if any, can be made from this study. Additionally, no JH measurements are made on this study.

Dr. Saric agreed that the gain settings were high, but found that the echocardiogram was technically adequate. The Cypress Machine was used here and the gain setting was 12. Dr. Jacob found the echocardiogram to be of "diagnostic quality" though he conceded that the Nyquist limit was 51 cm/sec.

Both Drs. Saric and Marino found that the PLAX view was available, though Dr. Saric observed that the high gain made identification of any aortic jets difficult. Dr. Saric proceeded to the A3C views but failed to document MAR,

finding a JH of .1755 cm and a LVOT of 2.1 cm which computes to a JH/LVOT = 8.35%. Dr. Marino found no aortic regurgitation though he noted that the high color gains made quantification unreliable.

Dr. Jacob disagreed. He found the echocardiogram to be of "diagnostic quality" although he noted the Nyquist limit was 51 cm/sec. It could have been 61 cm/sec since the probe depth was 16.2 cm. In Dr. Jacob's view, the PLAX view was non-diagnostic and he proceeded to the A3C and A5C views. He claimed the JH/LVOT in those views to be approximately 20%. Dr. Jacob conceded that his opinion was largely based on A5C views[30] which are not approved views under the CAS and also conceded that the CW Doppler failed to support his position.

---

[30] Dr. Jacob's testimony on these points is set out below.

> Q. That if the peristomal long axis view is available, that is the view to be utilized, to the exclusion of the apical views?
>
> * * * *
>
> A. My understanding is that we should use the peristomal long axis view for this study.
> Q. And it's here and we were seeing it, and it was well -- it was Dopplerized with color, correct?
> A. Yes. But it is very technically difficult.
> Q. Yes, sir. Now, I am going to look quickly -- in fact, what you measured from, and I can go through them quickly. Page 29, that's the apical five-chamber view, right?
> A. Yes.
> Q. That's a short axis view, correct?
> A. Short axis?
> Q. You don't know?
> A. No, I am saying short axis? Apical five.
> Q. Yes.
> A. Right, okay.
> Q. Is that considered short axis to you or long axis?
> A. Long.
> Q. Apical five-chamber, page 30, that's an apical five-chamber as well, correct?
> A. Yes. In each one of these you see aortic regurgitation.
> Q. Yes, sir. And without -- I can go through them -- the other pages you cited, they are all apical five-chamber as well?
> A. Okay, right.
> Q. Doctor -- and if we discussed it, I apologize to you. Apical five-chamber is not considered a reliable view in order to assess the severity, if any, of aortic regurge, is it?
> A. Well, I think in this case here, obviously there is aortic regurgitation that is seen on this view. If I was reading this study, I would say that there is at least mild aortic regurgitation here, based on this view.
> MR. RAMSAY: Non-responsive. Move to strike. If you would reread my question, please.
> (Whereupon, the reporter read back the requested question.)
> A. I would use --
> Q. Would you answer my question first.

The Court finds that Wyeth has satisfied it that no reasonable physician could determine, based on review of this echocardiogram, that Parks has MAR. The PLAX and A3C views fail to support a diagnosis of MAR and the A5C view is an inappropriate view. In any case, the CW Doppler does not show a holodiastolic event.

JJ. NIKKI PAYNE

Payne relies on a July 18, 2002 echocardiogram and report of Dr. Scott L. Roth. Dr. Roth found Payne had MMR using CAS criteria -- RJA/LAA = 22%. Dr. Roth noted that this was a "[t]echnically adequate study."

The July 18, 2002 echocardiogram was reviewed by three (3) experts: Dr. Marino, Dr. Saric and Dr. Dahl. All three (3) physicians found the echocardiogram to be technically adequate.

Both Drs. Marino and Saric found that Payne does not have MMR. According to Dr. Saric, the "RJA/LAA ratio is consistent with mild MR." Dr. Saric measured the RJA at 3.326 cm^2 and the LAA at 19.829 cm^2, giving a RJA/LAA of 16.77%. Dr. Marino agreed that any mitral regurgitation would be no more than mild. In his view, "[t]here is a flash of color in early systole, but it is not holosystolic and therefore it is not true mitral regurgitation. Additionally, the purported RJA measurements are overtraced to include blue, low velocity flow.

A. I think it can be used. Okay? I think in this study it is diagnostic of aortic regurgitation.
Q. Okay. Let's go to the -- you didn't cite the continuous wave on this one either, did you?
A. No.
Q. Is that because it did not support your position that we had, in fact, a high velocity, holodiastolic?
A. I don't remember for sure. There is a lot. Do you want to look at it?
Q. Page 27. Now, the apical five-chamber view is the appropriate view to utilize spectral Doppler, correct?
A. Yes.
Q. And that is what we have there. And very quickly, page 27, the continuous wave simply does not support a position that one has a high velocity or a holodiastolic regurgitant jet, correct?
A. Well, there is some aortic regurgitation there, but you cannot tell -- it's not high velocity.
Q. Let me go back to my basic definitions. Doctor, isn't high velocity a requisite component of any type of backward flow for it to be considered a regurgitant jet?
A. Yes, it has to be high velocity. This is not diagnostic, this particular.
Q. This demonstrates, if any, nothing that is high velocity, correct?
A. Right.

Spectral Doppler through the mitral valve confirms the absence of holosystolic high velocities."

Dr. Dahl found that Payne showed a RJA of 3.8 cm² and a LAA of 18.85 cm² which computes to 20%. However, during cross-examination Dr. Dahl conceded the RJA was overmeasured. In his view, a RJA of 3.57 cm² was medically reasonable. He ultimately made several measurements but their average, using a LAA of 18.85 cm², was less than 20%.[31]

---

[31] Dr. Dahl's testimony on this point is set out below.

> Q. Let's go to Page 29. Doctor, you cite a RJA of 3.8, correct?
> A. Let me look.
> Q. Let's go to Page 46. You cite, Doctor, in your affidavit to 3.8, correct?
> A. Yes.
> JUDGE WALSH: You don't endorse this tracing? I mean, this tracing is science fiction.
> A. The other one we had is clearly better, undoubtedly.
>
> * * * *
>
> Q. Doctor, we've seen two still frame tracings, one at 3.86, I think it was, and one at 3.57 here on Page 29, correct?
> A. Correct.
> Q. Did you look at them together? I'm trying to understand, which ones you relied upon or how you came out at 3.8?
> A. I don't recall any more than what we see here. I may have used the other one. As I sit here, I certainly would agree that this is a better tracing.
> Q. And let's look at Page 32.
> MR. RAMSAY: I'm sorry; what page?
> MR. EASTERBY: Page 32. He cites an [sic] LAA of 18.5.
> Q. And Doctor, is this where you got your LAA from?
> A. Yes.
> Q. Doctor, I meant to ask you at the beginning, are you familiar with the concept of interreader variability?
> A. I am.
> Q. And I've asked this question of several of the doctors.
> Do you have an understanding as to what is generally accepted amongst cardiologists as a percentage quantifying interreader variability?
> A. What percentage would I expect --
> Q. Amongst two cardiologists looking at the same thing, how much would their tracings differ?
> A. Probably 10 to 20 percent.
> Q. Fair enough. For Ms. Payne, Doctor, did you diagnose FDA-positive mitral regurgitation in a medically reasonable fashion utilizing the material applicable in this litigation?
> A. Yes.
> JUDGE WALSH: I don't think so. Let's make sure we're on the same page here. I again, want to give the doctor a full opportunity to -- we take the tracing at 3.57 over an 18.85 centimeter square LAA, you don't meet the criteria.
> MR. EASTERBY: He cites a 3.8 in the certification, your Honor.
> JUDGE WALSH: He does, but the 3.8 to commendably to him, he stepped away from, and it's bogus.
> Q. Well, let's look at a still frame, Page 30 --

While the Court finds Dr. Dahl commencibly candid, it also finds that, though close, no reasonable RJA/LAA measurement carries Payne beyond the 20% threshold.

The Court finds that the three (3) physicians here agreed that no reasonable physician could find that Payne has MMR based on a review of this echocardiogram. For that reason, the Court finds that Wyeth has established that no reasonable physician could find Payne has MMR based on this echocardiogram's review.

JUDGE WALSH: I know Mr. Ramsay, you'd prefer I didn't say anything. I'm a factfinder and I want to give the doctor every chance he has if he feels that we're leading him into -- outside the paths of righteousness, I want him to be able to correct it, but I think he's correct. I think 3.57 is a reasonable RJA measurement and this is a reasonable LAA measurement. I mean, a little bit of guessing on the left flank of the left atrial wall, but I think it's a reasonable surmise given the 2-D image.
MR. EASTERBY: My calculation is that yields 18.93 percent.
JUDGE WALSH: All right. Well, we're not close enough for government work here.
MR. EASTERBY: Let's go back to Page 29.
Q. And Doctor, discussing the concept of interreader variability that we've just discussed, do you think it would be possible, medically reasonable, for a cardiologist to trace that slightly higher than 3.57 centimeters?
A. It's possible, yes.
JUDGE WALSH: And it's just as likely, if not more likely, that the right border at the lower border is over-traced, but I say all side and done, this is not an unreasonable tracing. I mean, whether you should trace it or not is another story, but this is not an unreasonable tracing, and even if I were to accept the concept of interreader variability, which I do, you can't get over the bar doing that. So --
MR. EASTERBY: Well, the same token as the last plaintiff, Judge, I guess we'll at the break just try to --
JUDGE WALSH: I'll give you a chance. I'll give you a chance to look. I'm not trying to turn out the lights if I'm wrong. All right.
BY MR. EASTERBY:
Q. Let's go back to Page 32. This is the LAA, Doctor, measured towards the end of systole, correct?
A. Correct.
Q. Do you feel it would be possible to trace that, again, using the concept of interreader variability in a slightly different fashion and still be medically reasonable?
A. Probably so.

KK. JEAN PERKINS

Perkins relies on a November 18, 2002 echocardiogram and report of Dr. Stanley S. Schrem. Dr. Schrem found Perkins had MAR using CAS criteria -- JH/LVOT = 18%. Dr. Schrem found the study quality to be "fair."

The November 18, 2002 echocardiogram was reviewed by three (3) experts: Dr. Marino, Dr. Saric and Dr. Jacob. All three (3) physicians found the echocardiogram to be technically adequate, though both Drs. Saric and Marino believed the color Doppler gain was set too high. The Cypress machine was used here and the gain was set at 16.

Both Drs. Saric and Marino found no MAR in the PLAX view. According to Dr. Marino, "[a]t times, the color Doppler gain is set too high, as evidenced by the color sparkling in the tissue. Although the study is interpretable, a high color gain setting can exaggerate the severity of aortic regurgitation, if any, making any measurements on this study suspect." Dr. Saric did measure the JH at .1315 cm and the LVOT at 2.168 cm, yielding a JH/LVOT = 6.06%. Dr. Saric confirmed that the "JH/LVOT was consistent with less than mild AI."

Dr. Jacob disagreed. In his view, the gain settings were "appropriate" though on cross-examination he acknowledged that it was "elevated." Dr. Jacob measured the JH/LVOT in both the PLAX and A3C views and found a JH/LVOT = 15%. He did not identify where he actually made this measurement but it appeared on cross-examination that the measurement as made in the A3C views. The PLAX view was available and showed no significant aortic regurgitation. Moreover, the CW Doppler failed to confirm an envelope suggesting a holodiastolic aortic jet. Review of this echocardiogram convinces the Court there is no MAR present in the available PLAX view. The Court also agrees that no support exists for a holodiastolic jet through CW Doppler.

The Court finds that Wyeth has satisfied its burden and has shown that no reasonable physician could conclude, based on a review of this echocardiogram, that Perkins has MAR.

LL. MARGARET PITTS

Pitts relies on an August 1, 2002 echocardiogram and report of Dr. Paul R. Chu. Dr. Chu found that Pitts had MMR using CAS criteria -- RJA/LAA = 27%. No RJA or LAA measurements were provided.

The August 1, 2002 echocardiogram was reviewed by three (3) experts: Dr. Schwartz, Dr. Saric and Dr. Jacob. Both Drs. Saric and Jacob found that this echocardiogram was not conducted in a technically adequate manner such that reliable medical conclusions regarding the presence and severity of valvular regurgitation could be drawn from it. Drs. Saric and Jacob believed the Nyquist limit was set at 45 cm/sec. In addition, the gain was high on this Cypress machine at between 12 and 17. Dr. Saric noted that about eight (8) seconds of this echocardiogram was set at 51 cm/sec; he evaluated this section of the media. Dr. Saric managed to measure a RJA of 3.11 cm^2 and a LAA of 21.65 cm^2, yielding 14.36%. Dr. Schwartz felt the echocardiogram was of such poor quality that no meaningful information could be gained from its review.

Dr. Jacob disagreed. According to him, the Nyquist was set at 50 cm/sec. The Court disagrees. The media makes it clear that virtually all of the echocardiogram was performed using a Nyquist limit under 50 cm/sec.

According to Dr. Jacob, he measured a RJA/LAA between 25% and 30%, although he failed to identify any specific measurements. On cross-examination, he could not identify any measurements either. A review of Dr. Jacob's testimony on cross-examination makes it clear that whatever measurements he relied on were made at 45 cm/sec.

The Court finds that Wyeth has established that this echocardiogram was not conducted in a technically adequate manner such that reliable medical conclusions regarding the presence and severity of valvular regurgitation could be drawn from it. The Nyquist limit was set at impermissibly low levels. The Court adds that the high gain further complicated any review of this echocardiogram. In the few frames which had Nyquist limits above 50 cm/sec, there was insufficient evidence for a reasonable physician to conclude that Pitts has MMR based on review of this echocardiogram.

MM. LORRAINE PRIETTO

Prietto relies on an October 3, 2002 echocardiogram and report of Dr. Marcus Braun. Dr. Braun found Prietto had MMR using CAS criteria -- RJA/LAA = 30%. No RJA or LAA data are provided. Dr. Braun judged this echocardiogram to be "technically adequate."

The October 3, 2002 echocardiogram was reviewed by three (3) experts: Dr. Vasey, Dr. Saric and Dr. Jacob. All three (3) physicians found the echocardiogram

to be technically adequate though both Drs. Vasey and Saric judged the color gain to be too high. Both Drs. Saric and Vasey determined that Prietto had no more than mild mitral regurgitation. Dr. Vasey reported:

> The planimetered areas of purported mitral regurgitation are taken out of context and include primarily non-aliased flow. Continuous loops of the mitral valve show no significant mitral regurgitation (pages 31 and 32). Continuous wave Doppler through the mitral valve shows only brief non-holosystolic mitral regurgitation (pages 40-44). There is only transient mitral regurgitation that is trace in severity, at most.

Dr. Saric concurred. Dr. Saric measured a RJA of 1.622 cm^2 and a LAA of 16.517 cm^2, yielding a RJA/LAA = 9.82%.

Dr. Jacob found that Prietto has MMR but failed to provide any measurements or percentage quantification. Dr. Jacob acknowledged that the CW Doppler did not support his MMR claim. Moreover, review of the media convinces the Court there is no evidence that anything seen is holosystolic.

The Court has reviewed the media and considered the testimony of all three (3) experts. There is no evidence supporting a MMR claim here. The echocardiogram is of marginal quality because of the high gains. There is no evidence that any phenomenon observed here is holosystolic. Finally, the CW Doppler makes it clear that whatever is observed is fleeting and insignificant. Accordingly, Wyeth has satisfied the Court that no reasonable physician could conclude that Prietto has MMR based on a review of this echocardiogram.

NN. DEBORAH RENAUD

Renaud relies on an August 30, 2002 echocardiogram and report of Dr. Stanley S. Schrem. Dr. Schrem found Renaud had MMR using CAS criteria -- RJA/LAA = 30%. There was also a finding of MAR but that claim was conceded by the plaintiff. Though Dr. Schrem simply noted "moderate mitral regurgitation," the sonographer's worksheet provided measurements averaging 30% with a LAA = 10.11 cm^2. Dr. Schrem noted that the echocardiogram quality was "good."

The August 30, 2002 echocardiogram was reviewed by three (3) experts: Dr. Vasey, Dr. Saric and Dr. Jacob. All three (3) physicians found the

echocardiogram to be technically adequate. A Cypress machine was used with a gain setting of 15.

Both Drs. Saric and Vasey determined that Renaud did not have MMR. Dr. Saric traced a RJA of 2.599 cm^2 and a LAA of 17.113 cm^2, for a RJA/LAA = 15.19%. Dr. Vasey concluded that the LAA was measured in early systole, thus substantially underestimating its true area. Moreover, according to Dr. Vasey, the RJAs were substantially overtraced by including low velocity flow.

Dr. Jacob disagreed. According to him, several pages in the media show MMR although he provides no measurements. Dr. Jacob conceded that the LAA should be measured in late systole when the left atrium is at its greatest volume. That was not done here.

The Court believes Wyeth has demonstrated that the LAA was significantly underestimated and the RJAs were overtraced. It adopted Dr. Vasey's criticisms of Dr. Jacob's findings as its own.

> Dr. Jacob relies on real-time images on Pages 19, 38, 40 and 45 of the study to demonstrate moderate mitral regurgitation. Dr. Jacob also relies on measurements on Pages 20, 21, 22 and 39 for his conclusion that there is moderate mitral regurgitation on the study, but he does not provide any specific RJA or LAA measurements, or ratios. Additionally, Dr. Jacob relies on a measurement on Page 41; however, he cites the "jet is overestimated" in his opinion. Dr. Jacob does not provide any opinions regarding Ms. Renaud's level of aortic regurgitation; therefore, I assume Dr. Jacob concedes that Ms. Renaud does not have FDA Positive aortic regurgitation.
>
> I have re-reviewed the echocardiogram in its entirety. Page 18 is a continuous loop of the apical four-chamber with a Nyquist level of 61 cm/sec. at a depth of 16.2 cm. A frame by frame analysis of a portion of the systolic cycle shows no holosystolic mitral regurgitation; frames 1-3 are the only three frames (out of 11 total systolic frames) that demonstrate any flow above the mitral valve. Based on the closed position of the mitral valve leaflets, the aforementioned transient flow is not true mitral

> regurgitation. Pages 19, 38 and 40 are still frame images of purported mitral regurgitation, 3.18 cm², 3.64 cm² and 3.46 cm², respectively. Each of these purported regurgitant measurements were measured in early systole and included predominantly low velocity blue flow and black signal (and were overtraced). Similarly, Page 20 is a still frame image of purported mitral regurgitation (1.96 cm²) measured in early systole and overtraced, including low velocity flow. Regardless, this purported RJA measurement would not yield an RJA/LAA ratio greater than 20% [even considering a LAA of 10.11 cm²]. Page 21 is a left atrial measurement of 10.11 cm² measured in early systole, rather than at end-systole when it is at its maximal dimension, thereby underestimating the true left atrial area by a substantial margin. Dr. Jacob apparently relies upon measurements on Pages 22 and 41; however, no color flow mapping is displayed on either page. Page 39 is a continuous loop of the apical two-chamber view with an excessive color flow gain. Regardless, no mitral regurgitation is visualized. Finally, Page 45 is a still frame image of purported mitral regurgitation (2.14 cm²) in the apical long-axis view. The purported RJA is measured in early systole and encompasses entirely low velocity blue and black flow, and is in no way indicative of actual mitral regurgitation. (Footnote omitted.)

The Court finds that Wyeth has established that no reasonable physician could conclude that Renaud has MMR based on a review of the echocardiogram here.

OO. CAROL RICHMAN

Richman relies on a November 5, 2002 echocardiogram and report of Dr. Charles F. Dahl. Dr. Dahl found Richman had MAR using CAS criteria -- JH/LVOT = 20%. No JH or LVOT was provided in the report.

The November 5, 2002 echocardiogram was reviewed by three (3) experts: Dr. Vasey, Dr. Saric and Dr. Jacob. Both Drs. Saric and Vasey found that this echocardiogram was not conducted in a technically adequate manner such that reliable medical conclusions regarding the presence and severity of valvular

regurgitation could be drawn from it. Both the Nyquist limits were set too low (46 cm/sec) and the color Doppler gains were set too high. Dr. Saric noted:

> Nyquist limit was set too low [at] 46 cm/sec and color gains were too high in all FDA relevant views. These settings exaggerate the amount of color on the screen thus making any regurgitant jet larger than it truly is. Therefore, the study methodology does not conform to the recomme[n]dation of the American Society of Echocardiography regarding both the Nyquist limit & color gain settings ("Stadand [sic] technique is to use a Nyquist limit of 50-60 cm/sec, and color gain that just eliminates random color speckle from non-moving regions." p. 788 J Am Soc Echocardiog 2003:16:777-802).

Dr. Vasey concurred also noting that no aortic regurgitation was seen in the PLAX views.

Dr. Jacob disagreed. While he conceded that this was "a technically difficult study," Dr. Jacob believed that a diagnosis of MAR could be made.[32]

---

[32] Dr. Jacob's testimony on cross-examination is reported below. The Court rejects his opinion as not credible.

> Q. Page 16. With regard to Ms. Richmond, you indicate it was a technically difficult study with appropriate gain and low end Nyquist setting.
>
> First let's go -- but you are telling the court -- when you say the PLAX was non-diagnostic, what you really mean is that in the peristomal long axis view, while it was available, you did not see what you felt to be either any aortic regurgitation or certainly any significant aortic regurgitation; isn't that true?
>
> MR. EASTERBY: Object to form. That misstates the statement in his Affidavit. It says it's non-diagnostic.
>
> MR. RAMSAY: That is what I just said.
>
> Q. When you said it was non-diagnostic, you mean by that you couldn't see any aortic insufficiency in the PLAX view, correct?
>
> A. Right. Can we see it? Can we see the study?
>
> Q. Sure. I will show it to you. Isn't that what you mean when you non-diagnostic?
>
> A. Right.
>
> Q. All right. And then you say they are seen in apical views?
>
> A. Right.
>
> Q. So, you utilized apical views, correct?
>
> A. Right.
>
> Q. All right. Let's first go to the PLAX view, page four. Doctor, when one looks at page four, first we are dealing again with the -- with a hurdle of a very high gain, 17, and a Nyquist of 46, correct?
>
> A. Correct.

Q. Hear again, in the PLAX that's the most superficial department one utilizes in performing an echo, correct?
A. Yes.
Q. I am not going to ask you about that. You are telling me you think that 46 is an appropriate Nyquist?
A. In some patients.
Q. This patient?
A. Not right here it is not, not on this view right here, non-diagnostic.
Q. Well, the Nyquist you say is not appropriate?
A. In this view right here that I am looking at, no.
Q. Okay. Well, certainly in this view with a low Nyquist, one would be more likely to see some exaggeration of aortic regurgitation jet, not some diminution of regurgitation jet, if, in fact, it exists, correct?
A. Right.
Q. And we don't see any in this entire PLAX view, do we?
A. No, I don't see any.
Q. So, you decided not to utilize this PLAX view, correct?
A. True.
Q. And decided to go instead to the apical views?
A. True.
Q. All right. Let's -- fine. And we have got page four which is a PLAX. Let's go to page five. Doctor, I think you can see that again we are hampered with a high -- a low, low Nyquist of 46 and a high gain, correct?
A. Correct.
Q. And you can see speckling in the tissue, can't you?
A. Yes.
Q. Here again, this is a second PLAX view. Once again, you did not utilize it because, frankly, in your review of it you did not find what you felt was significant aortic insufficiency or any aortic insufficiency, correct?
A. I didn't -- right, that's correct.
Q. So, you went to the apical views?
A. Right.
Q. Let's go to -- well, let's just go to the pages that you have directed the court to with regard to Ms. Richmond. You directed the court to apical views 24, 27 and 34. Page 24, please.
Doctor, that's the apical five-chamber view, isn't it?
A. Yes.
Q. Do you have an understanding that apical five-chamber views are impermissible under the Settlement Agreement for the purposes of assessing aortic insufficiency?
A. Well, what I understand is the parasternal long axis view is the view that is acceptable.
Q. Yes, sir, but even if one doesn't have a PLAX, one then goes to the apical three-chamber view, not the five-chamber, correct?
A. Right.
Q. The five-chamber is the most unreliable of the apical views for the assessment of AR?
A. I agree.
Q. But you chose the apical five-chamber on page 24. Page 27. That is another five-chamber, isn't it?
A. Yes.
Q. 34, page 34, the last page you cited to Judge Walsh. Another five-chamber, isn't it?
A. Yes.

The Court disagrees. For the reasons set out in II B of this Letter Opinion, the low Nyquist limits and high color gains doom this echocardiogram from the outset. The Court finds that Wyeth has easily satisfied it that this echocardiogram was not conducted in a technically adequate manner such that reliable medical conclusions regarding the presence and severity of valvular regurgitation could be drawn from it. Moreover, no MAR is seen in the PLAX views.

PP. KATHY ROBERTSON

Robertson relies on a July 31, 2002 echocardiogram and report of Dr. Charles F. Dahl. Dr. Dahl found Robertson had MAR using CAS criteria -- JH/LVOT = 20%.

The July 31, 2002 echocardiogram was reviewed by three (3) experts: Dr. Vasey, Dr. Saric and Dr. Jacob. All three (3) physicians found this study could be interpreted but both Drs. Saric and Vasey found that the color Doppler gains were "excessive." According to Dr. Saric, "[t]he study [was] barely interpretable...."

Both Drs. Saric and Vasey found no aortic regurgitation in the PLAX views. In the words of Dr. Vasey, "[e]ven with the excessive color flow gain, no aortic insufficiency is visualized in the parasternal long axis view. Continuous wave Doppler through the aortic valve in the five-chamber view shows no true aortic insufficiency signal."

Dr. Jacob disagreed. In his view, the "echocardiogram performed on Ms. Robertson was of diagnostic quality with appropriate gain ... settings." Dr. Jacob determined the PLAX views to be non-diagnostic and proceeded to the apical views. He quantified the aortic regurgitation in the A5C which is not an approved view. The Court accepts Dr. Vasey's criticisms of Dr. Jacob's approach.

Q. If we can, quickly let's go to page 37. Again, you did not cite to the court the continuous wave or the spectral Doppler, did you?
A. No.
Q. And the reason you did not, and I am now showing the court page 37, is that the continuous wave Doppler does not support any position that there exists aortic regurgitation, either a high velocity jet or any phenomenon that lasts throughout the diastolic cycle, does it?
A. It doesn't, but it's not technically adequate.
Q. Yes, sir. I understand your position there, but that's what we have got and it doesn't show it, does it?
A. No.

> I have re-reviewed the study in its entirety. The parasternal long axis view was available and adequately visualized on Ms. Robertson's echocardiogram. Pages 11 and 12 show color flow mapping in the parasternal long axis view with an excessive color flow gain setting. Despite this technical limitation, no aortic regurgitation is visualized in the parasternal long-axis view. These parasternal long axis continuous loops had a Nyquist setting of 51 cm/sec. at a depth of 13.5 cm. Additionally, continuous wave Doppler through the aortic outflow tract shows no aortic insufficiency signal (Page 30).
>
> Dr. Jacobs's inappropriately relied upon the apical five-chamber view (Pages 29 and 31), which cannot be used for quantitative assessment of aortic regurgitation according to the settlement criteria. These apical five-chamber continuous loops had a Nyquist setting of 51 cm/sec. at a depth of 16.2 cm. Additionally, Dr. Jacob inappropriately relied upon the apical three-chamber view (Pages 42, 43, 44 and 45) to assess the purported aortic regurgitation.* The apical three-chamber view is only allowed under the settlement criteria if the parasternal long axis view is not available. Therefore, the availability of the parasternal long-axis view precludes any assessment of the apical views.
>
> * Pages 44 and 45 show two purported aortic regurgitant measurements, 0.48 cm and 0.54 cm respectively, in the apical three-chamber view. The purported aortic insufficiency that is measured is highly eccentric and appears not to pass through the aortic valve leaflets centrally.

The Court finds that Wyeth has established that no reasonable physician could rely on this marginal echocardiogram to conclude that Robertson has MAR. The PLAX views are available and show no aortic regurgitation. The A5C views used by Dr. Jacob are not approved views for purposes of the CAS. Finally, the A3C views do not document aortic regurgitation for the reasons stated by Dr. Vasey.

QQ. TRYNA ROSS (STALLINGS)

Ross relies on a September 4, 2002 echocardiogram and report of Dr. Edward S. Katz. Dr. Katz found Ross had MMR using CAS criteria -- RJA/LAA = 30%. Dr. Katz noted that the study quality was "fair."

The September 4, 2002 echocardiogram was reviewed by three (3) experts: Dr. Goldman, Dr. Sherrid and Dr. Jacob. All three (3) physicians found the echocardiogram was technically adequate, though Dr. Goldman noted "[t]he color Doppler gain setting was excessive...."

Both Drs. Sherrid and Goldman determined that the observed phenomenon was not holosystolic. In the words of Dr. Sherrid, it was a "trivial short transient puff of mitral regurgitation." Both experts noted that CW Doppler confirmed "the early systolic nature of this regurgitation."

Dr. Jacob disagreed. As he often did in these proceedings, Dr. Jacob made no measurements and did little or nothing to identify the views specifically used in forming his conclusions that Ross has MMR. Dr. Jacob admitted on cross-examination that he did nothing more than declare that Ross has MMR. When he was asked to review the pages on the echocardiogram he claimed showed MMR, he could not do so and the CW Doppler supported the finding that no holosystolic phenomenon was observed.

The Court finds that Dr. Jacob's opinion here is entitled to no weight. It is nothing more than a net opinion. *Buckelew v. Grossbard*, 87 N.J. 512 (1981). The Court further finds that Wyeth has established that no reasonable physician could conclude that Ross has MMR based on a review of this echocardiogram.

RR. PATRICIA I. ROTHE

Rothe relies on a September 5, 2002 echocardiogram and report of Dr. Edward S. Katz. Dr. Katz found Rothe had MMAR using CAS criteria -- JH/LVOT = 36%. Dr. Katz noted that the study quality was "fair."

The September 5, 2002 echocardiogram was reviewed by three (3) experts: Dr. Vasey, Dr. Sherrid and Dr. Jacob. All three (3) physicians found the echocardiogram to be technically adequate, though both Drs. Sherrid and Vasey noted that "the color flow gain [was] high."

Both Drs. Sherrid and Vasey found essentially no aortic regurgitation in the PLAX view with Dr. Vasey reporting none and Dr. Sherrid finding only a "trivial transient puff." Dr. Vasey reported "[n]o aortic regurgitation is visualized in the parasternal long axis view. Additionally, the purported aortic insufficiency is measured in the apical five-chamber view. Continuous wave Doppler through the aortic valve shows only a very faint signal."

Dr. Jacob disagreed. Nevertheless, Dr. Jacob claimed Rothe has "FDA positive levels of AR." No measurements were provided, not even a percentage. Moreover, the claimed measurement was made in the A5C view, an unapproved view.

The Court finds that Wyeth has demonstrated that no reasonable physician could claim that Rothe has MAR, much less MMAR, based on this echocardiogram. The echocardiogram is of marginal quality. Review of the PLAX and A3C views do not show aortic regurgitation as claimed. CW Doppler shows no envelope consistent with true aortic regurgitation.

SS. LORRI M. SHELDON

Sheldon relies on an October 2, 2002 echocardiogram and report of Dr. John E. Lassetter. Dr. Lassetter found Sheldon had MMR and MMAR using CAS criteria -- RJA/LAA = 30%; JH/LVOT = 35%. Wyeth did not challenge the aortic regurgitation claim; the challenge proceeded as to the MMR claim only.

The October 2, 2002 echocardiogram was reviewed by three (3) experts: Dr. Vasey, Dr. Sherrid and Dr. Jacob. All three (3) physicians found the echocardiogram to be technically adequate though just "barely" according to Dr. Sherrid.

Both Drs. Sherrid and Vasey found only transient mitral regurgitation. According to Dr. Sherrid,

> BY JUDGE WALSH: All right. With respect to the mitral regurgitation claim, did you examine the apical views to determine whether this particular individual had moderate mitral regurgitation or FDA positive mitral regurgitation in an apical view based on the criteria?
> THE WITNESS: Yes, I did.
> THE COURT: And what did you find, Doctor?
> * * * *

> THE WITNESS: That there was just a transient puff of mitral regurgitation. On Page 40, there is no mitral regurgitation. On Page 51, the loop showed just transient trivial mitral regurgitation. Page 52 showed a transient mid systolic puff of mild mitral regurgitation. On Page 43, the CW Doppler shows transient mitral regurgitation.
> THE COURT: All right. Now, Doctor, based on a review of this echocardiogram, could a reasonable physician with similar skill sets to you conclude that this individual had FDA positive mitral regurgitation?
> THE WITNESS: No.

Dr. Vasey concurred. Neither felt that the brief phenomenon was not significant enough to measure.

Dr. Jacob disagreed but again provided no measurements or even percentages demonstrating MMR. There apparently were two (2) frames showing some indication of regurgitation but otherwise no regurgitation was seen in either color or CW Doppler.

The Court finds that Wyeth has demonstrated that no significant mitral regurgitation is seen in this echocardiogram. The Court finds that no reasonable physician could find that Sheldon has MMR based on review of this echocardiogram.

TT. JULIE SHINER

Shiner relies on a July 18, 2002 echocardiogram and report of Dr. Robert M. Applebaum. Dr. Applebaum found Shiner had MAR using CAS criteria -- JH/LVOT = 24%. Dr. Applebaum noted that the study quality was "fair."

The July 18, 2002 echocardiogram was reviewed by three (3) experts: Dr. Vasey, Dr. Sherrid and Dr. Jacob. Both Drs. Sherrid and Vasey found that this echocardiogram was not conducted in a technically adequate manner such that reliable medical conclusions regarding the presence and severity of valvular regurgitation could be drawn from it. According to both doctors, the color gain was far "too high." Both Drs. Sherrid and Vasey agreed that even with the technical flaws present, it was evident that no more than trivial aortic regurgitation was present. Dr. Vasey noted that CW Doppler failed to show any significant aortic regurgitation.

Dr. Jacob disagreed. But as has happened in other cases, Dr. Jacob provides no measurements not even percentages in support of his position. On cross-examination, he could not tell the questioner whether he made any independent measurements or simply adopted those made by the sonographers. He claims that the gain setting was "appropriate" which the Court rejects as incredible. Finally, he conceded that the CW Doppler showed no holodiastolic phenomenon which one would expect to see if there was aortic regurgitation. Dr. Jacob claimed the CW Doppler was off axis which the Court also rejects as not credible.

The Court finds that Wyeth has shown that this echocardiogram was not conducted in a technically adequate manner such that reliable medical conclusions regarding the presence and severity of valvular regurgitation could be drawn from it. The gains were simply too high. Moreover, Wyeth has shown that review of this flawed echocardiogram reveals little or no aortic regurgitation. No reasonable physician could find that Shiner has MAR based on a review of this echocardiogram.

UU. INGA SHURTZ

Shurtz relies on a July 16, 2002 echocardiogram performed by Dr. Charles F. Dahl. Dr. Dahl found Shurtz had MAR using CAS criteria -- JH/LVOT = 10%.

The July 16, 2002 echocardiogram was reviewed by three (3) experts: Dr. Stern, Dr. Sherrid and Dr. Dahl. By stipulation dated May 16, 2005, the parties agreed to a disposition consistent with the decision of the independent expert, Dr. Sherrid.

Dr. Sherrid found the echocardiogram to be technically adequate. He concluded that there is, at best, trivial aortic regurgitation in the PLAX views.

Based on the stipulation of the parties and the conclusion of Dr. Sherrid, the Court is satisfied that Wyeth has established that there is no aortic regurgitation seen in the PLAX view.

VV. EVA SIDES

Sides relies on an October 3, 2002 echocardiogram performed by Dr. Marcus Brann. Dr. Brann found Sides had MMAR using CAS criteria -- JH/LVOT = 32%.

The October 3, 2002 echocardiogram was reviewed by three (3) experts: Dr. Stern, Dr. Sherrid and Dr. Jacob. By stipulation dated May 16, 2005, the parties agreed to a disposition consistent with the decision of the independent expert, Dr. Sherrid.

Dr. Sherrid found that the echocardiogram was not conducted in a technically adequate manner such that reliable medical conclusions regarding the presence and severity of valvular regurgitation could be drawn from it. He indicated that the gain was "too high." Dr. Sherrid also noted that he did not conduct measurements because there was only a "[t]rivial whiff" of aortic regurgitation.

Based on the stipulation of the parties and the conclusion of Dr. Sherrid, the Court is satisfied that Wyeth has established that no reasonable medical opinion that Sides was FDA positive could be based on this echocardiogram.

WW. CAROL A. SMITH

C. Smith relies on a November 14, 2002 echocardiogram and report of Dr. David A. Rawling. Dr. Rawling found C. Smith had MMAR using CAS criteria -- JH/LVOT = 47%. Dr. Rawling noted that the study quality was "fair to good."

The November 14, 2002 echocardiogram was reviewed by three (3) experts: Dr. Schwartz, Dr. Sherrid and Dr. Dahl. Dr. Schwartz found that this echocardiogram was not conducted in a technically adequate manner such that reliable medical conclusions regarding the presence and severity of valvular regurgitation could be drawn from it. According to him,

> [t]he depth is set too deep and the zoom function is not employed, rendering the cardiac image too small (particularly in the PLAX view), thus making accurate measurements of the JH or LVOT impossible. In addition, the color Doppler examination of the PLAX views is deficient and insufficient for diagnostic purposes.

Drs. Sherrid and Dahl found the echocardiogram to be technically adequate.

Both Drs. Sherrid and Schwartz found that there was no aortic regurgitation observed in the PLAX views.

Dr. Dahl agreed but found the PLAX views were not diagnostic. Dr. Dahl measured a JH/LVOT = 21% in one of the A3C views. However, the measurement probably was made more than one (1) centimeter from the valve annulus making the measurement suspect. In any case, one cannot visualize the aortic annulus, making measurement of any jets a hazardous undertaking. The Court has reviewed this echocardiogram and the testimony of the experts. It agrees with Dr. Schwartz that Dr. Dahl's conclusion that C. Smith has MAR is not supported by this echocardiogram. Dr. Schwartz noted:

> To the extend that anything can be gleaned from this study, the color Doppler that is recorded on the parasternal long axis view does not show any significant aortic insufficiency. The apical views show a trivial amount of aortic insufficiency, which cannot be accurately measured for a JH/LVOT ratio.
>
> Dr. Dahl cites 9:12:17, which is in the PLAX view, as showing mild aortic insufficiency, but there is no aortic insufficiency seen at this time marker or at any other point in the parasternal long axis view.
>
> In addition, Dr. Dahl cites 9:13:58, which he calls the apical 4-chamber view, as show[ing] mild aortic insufficiency. First, the apical 4-chamber view does not show the aortic valve and therefore cannot be used to diagnose aortic insufficiency. Second, this is not the apical 4-chamber view; it is the apical 5-chamber view. And lastly, it is both inappropriate and impermissible to determine the severity of aortic insufficiency based on the apical 5-chamber view.
>
> Dr. Dahl next cites 9:25:54, which he calls the apical 2-chamber view, as showing mild aortic insufficiency. Like the apical 4-chamber, the apical 2-chamber view does not show the aortic valve and therefore cannot be used to diagnose aortic insufficiency. Also, this time marker does not show the apical 2-chamber, but rather the apical 3-chamber, which tends to exaggerate the severity of aortic insufficiency. The image quality at this point in the study remains poor. Moreover, the flow seen

> at this time marker is well below the valve and therefore cannot be used to quantify aortic insufficiency.
>
> The continuous wave Doppler is also consistent with a small amount of aortic insufficiency given the faintness of the spectral envelope, especially when examining all of the available cycles. Dr. Dahl contends that the pressure half-time demonstrates mild aortic insufficiency. However, the pressure half-time value calculated is inaccurate given the faintness of the spectral envelope. Moreover, as stated earlier, the pressure half-time is inferior to color Doppler date, and in this case, is completely inconsistent with that data.

The Court finds that Wyeth has satisfied its burden and shown that no reasonable physician could find C. Smith has MAR, much less MMAR, based on a review of this echocardiogram.

XX. DEBORAH J. SMITH

D. Smith relies on a June 11, 2002 echocardiogram performed by Dr. John E. Lassetter. Dr. Lassetter found D. Smith had MAR using CAS criteria. The technician's worksheet indicates that D. Smith had MMAR -- JH/LVOT = 39.1%.

The June 11, 2002 echocardiogram was reviewed by three (3) experts: Dr. Stern, Dr. Sherrid and Dr. Jacob. By stipulation dated May 16, 2005, the parties agreed to a disposition consistent with the decision of the independent expert, Dr. Sherrid.

Dr. Sherrid found that the echocardiogram was not conducted in a technically adequate manner such that reliable medical conclusions regarding the presence and severity of valvular regurgitation could be drawn from it. He observed that the "[a]liasing velocity lowered in mid study to 46 cm/sec." As previously noted by the Court, standard practice is to use a Nyquist limit (aliasing velocity) of at least 50/60 cm/sec. *ASE Standards* at 777-778.

Based on the stipulation of the parties and the conclusion of Dr. Sherrid, the Court is satisfied that Wyeth has established that no reasonable medical opinion that D. Smith was FDA positive could be based on this echocardiogram.

YY. KERRY M. SMITH

K. Smith relies on a November 6, 2002 echocardiogram performed by Dr. Charles F. Dahl. Dr. Dahl found K. Smith had MAR using CAS criteria -- JH/LVOT = 18%.

The November 6, 2002 echocardiogram was reviewed by three (3) experts: Dr. Stern, Dr. Sherrid and Dr. Jacob. By stipulation dated May 16, 2005, the parties agreed to a disposition consistent with the decision of the independent expert, Dr. Sherrid.

Dr. Sherrid found the echocardiogram to be technically adequate. He concluded that it was medically reasonable to diagnose K. Smith with MAR in the PLAX view. Dr. Sherrid measured a JH/LVOT = 12% in the PLAX view.

Based on the stipulation of the parties and the conclusion of Dr. Sherrid, the Court finds that Wyeth has failed to establish that no reasonable physician could conclude that K. Smith has MAR based on this echocardiogram. The echocardiogram is technically adequate and Dr. Sherrid's review confirms that a reasonable physician could conclude that K. Smith has FDA positive aortic regurgitation based on a review of this echocardiogram.

ZZ. RENE D. SMITH

R. Smith relies on an October 1, 2002 echocardiogram performed by Dr. Charles F. Dahl. Dr. Dahl found R. Smith had MMAR using CAS criteria -- JH/LVOT = 30%.

The October 1, 2002 echocardiogram was reviewed by three (3) experts: Dr. Stern, Dr. Sherrid and Dr. Jacob. By stipulation dated May 16, 2005, the parties agreed to a disposition consistent with the decision of the independent expert, Dr. Sherrid.

Dr. Sherrid found the echocardiogram to be technically adequate. He concluded that it was medically reasonable to diagnose R. Smith with MAR in the PLAX view. Dr. Sherrid measured a JH/LVOT = 15% in the PLAX view.

Based on the stipulation of the parties and the conclusion of Dr. Sherrid, the Court finds that Wyeth has failed to establish that no reasonable physician could conclude that R. Smith has MAR based on this echocardiogram. The

echocardiogram is technically adequate and Dr. Sherrid's review confirms that a reasonable physician could conclude that R. Smith has FDA positive aortic regurgitation based on its review.

AAA. DONNA SPENCER

Spencer relies on a September 4, 2002 echocardiogram performed by Dr. Edward S. Katz. Dr. Katz found that Spencer had MAR using CAS criteria -- JH/LVOT = 20%.

The September 4, 2002 echocardiogram was reviewed by three (3) experts: Dr. Stern, Dr. Sherrid and Dr. Jacob. By stipulation dated May 16, 2005, the parties agreed to a disposition consistent with the decision of the independent expert, Dr. Sherrid.

Dr. Sherrid found that the echocardiogram was not conducted in a technically adequate manner such that reliable medical conclusions regarding the presence and severity of valvular regurgitation could be drawn from it. He indicated that the gain was "much too high." This high gain setting precluded him from conducting any measurements. According to Dr. Sherrid, this was an "inadequate study [that] should not have been read."

Based on the stipulation of the parties and the conclusion of Dr. Sherrid, the Court is satisfied that Wyeth has established that no reasonable medical opinion that Spencer was FDA positive could be based on this echocardiogram.

BBB. BEVERLY WELLS

Wells relies on a November 7 (sic) [20], 2002 echocardiogram and report of Dr. Raymonda Rastegar. Dr. Rastegar found Wells had MMR using CAS criteria -- RJA/LAA - 23%. Dr. Rastegar noted that the study quality was "fair."

The November 20, 2002 echocardiogram was reviewed by three (3) experts: Dr. Teichholz, Dr. Sherrid and Dr. Jacob. Dr. Teichholz found that this echocardiogram was not conducted in a technically adequate manner such that reliable medical conclusions regarding the presence and severity of valvular regurgitation could be drawn from it. The gain settings on this Cypress machine were 21 -- extremely high. Dr. Sherrid found the echocardiogram was technically adequate as did Dr. Jacob, though Dr. Jacob conceded that gain was "high."

Both Drs. Sherrid and Teichholz agreed that the echocardiogram supports at most a finding of mild mitral regurgitation. Dr. Sherrid noted:

> There is an early puff of mitral regurgitation but this is transient and does not extend into mid or late systole. This is consistently seen on all pages 9, 10, 12, 59, 61. Page 25 is a misleading four frame loop of early systole which is not at all representative of the rest of systole. The CW Doppler on page 48 shows just early systolic MR. Overall, mild MR.

Dr, Teichholz concurred as follows:

> The sonographer did not trace the RJA correctly, tracing mostly low velocity laminar blue flow, and including what is likely noise caused by the high gain settings. Even with the technical inadequacies on this echocardiogram, at most minimal to mild mitral regurgitation is seen.

Dr. Jacob was left to disagree. Again, while he claimed Wells has MMR, he provided no measurements or even percentages. On cross-examination, he conceded that the phenomenon he claimed to be MMR was seen only in early systole.

The Court finds that Wyeth has established that no reasonable physician could, based on the review of this marginal echocardiogram, find that Wells has MMR. The claimed MMR occurs very early in systole and is not holosystolic. Moreover, as noted by Dr. Teichholz:

> All of the real time loops cited by Dr. Jacob demonstrate excessive gain and speckling throughout the color sector and extensive color in the cardiac chambers in the absence of demonstrable flow patterns. See Pages 9 and 10 which are in the PLAX view, and Pages 33, 41, 45, 58 and 61 which are in apical views. In these loops, the flow patterns are often affected by the high gain and do not make physiologic sense, which is further evidence of the unreliability of these images. Also, much of the mosaic and blue patterns seen on the images occurs

above the plane of the mitral valve, which is likely a product of the high gain settings.

The freeze frames cited by Dr. Jacob include large areas of noise resulting from the improper gain settings as follows:

- Pages 34 and 42 - These "jets" are surrounded by laminar red flow, which does not make physiologic sense. Also, there is mosaic and blue color occurring above the plane of the mitral valve, which is also not readily explainable and seems to be a product of the high gain settings.
- Page 46 - There is mosaic and blue color occurring above the mitral valve.
- Page 59 - This "jet" does not have a typical jet appearance, with the majority of the mosaic color occuring along the lateral wall rather than centrally. Also, the left atrium surrounding the "jet" includes laminar red areas, which is not physiologically plausible. There are areas of laminar blue in the left ventricle in the absence of demonstrable flow as well.
- Pages 35 and 36* - These are frames where tracings of RJA have been performed. The tracing includes some laminar blue areas at the bottom of the "jet." Also, although excluded from the tracing, the mosaic and blue color occurring above the plane of the mitral valve is not readily explainable and seems to be a product of the high gain settings.
- Page 44 - This is another frame with a tracing of RJA. The tracing includes laminar blue areas at the "jet" tip. This "jet" has laminar red areas next to it which does not make physiologic sense.

---

* Dr. Jacob actually cites measurements on Pages 25 and 26, which are of the [PLAX] view. I presume he intended to cite[] the[] RJA measurements on Pages 35 and 36.

- Page 47 - This is a tracing of RJA where the "jet" traced does not have a typical jet appearance. The mosaic pattern is on the lateral sides of the chamber, when typically the highest flow would occur centrally. The RJA tracing includes some areas above the mitral valve annulus and also includes areas of laminar blue and black at the bottom of the "jet."

CCC. TAMMIE ZACCARIA

Zaccaria relies on a November 4, 2002 echocardiogram and report of Dr. Charles F. Dahl. Dr. Dahl found Zaccaria had MAR using CAS criteria -- JH/LVOT = 15%.

The November 4, 2002 echocardiogram was reviewed by three (3) experts: Dr. Homma, Dr. Sherrid and Dr. Dahl. All three (3) physicians found that this echocardiogram was technically adequate though Dr. Homma noted the color gain was "somewhat excessive." A Cypress machine was used here with a gain setting of 20 in the PLAX views and 17 in the apical views.

Both Drs. Sherrid and Homma found little or no aortic regurgitation in either the PLAX or A3C views. Dr. Homma noted that "[a]lthough a trace AR is seen in apical views and measured, parasternal long axis view is available and no holodiastolic jet consistent with AR is demonstrated in this view." Dr. Sherrid concurred.

Dr. Dahl disagreed. He noted that

> AR is not well seen in the PLAX view on this study. It is however seen in real time in the apical 2 chamber view on page 42 (frames 13-17) and is holodiastolic. Measurements performed on pages 43-45 were not representative of the jet height. My measurements demonstrated a JH of .3 with [an] LVOT of 1.86 to yield a Singh ratio of 16%, which is mild AI.

The Court has reviewed this echocardiogram and agrees with Dr. Homma's criticisms which it adopts as its own.

> The color flow Doppler gain is high on some pages, especially in the parasternal long-axis view. Even with the high gain, there is no holodiastolic jet consistent with aortic insufficiency seen in the parasternal long-axis view. There is trace aortic insufficiency seen in the apical long-axis view.
>
> Dr. Dahl contends that aortic insufficiency is well visualized in the apical 2-chamber view on page 42 at frames 13-17. However, there is no color flow Doppler on page 42 of this study. [Dr. Homma noted that Dr. Dahl's pagination might be in error.] Moreover, it is very difficult to diagnose aortic insufficiency using the apical 2-chamber view since the aortic valve is not visualized in this view. Dr. Dahl may have been referring to either pages 43 or 44, which show the apical 3-chamber or apical long-axis view. However, there is no obvious aortic insufficiency seen on page 43. On page 44, there is at most trace aortic insufficiency, which is not consistently seen.
>
> In rejecting the measurements made on the study, Dr. Dahl re-measured the purported aortic insufficiency and found a JH of .3 cm and a LVOT of 1.86 cm. Of note, Dr. Dahl cites pages 43-45 as containing measurements; however, this is not the case, these being found on pages 45-47. Dr. Dahl does not indicate where he made his new measurement, which makes it difficult for me to comment on his measurement. Additionally, the measurements on pages 45-47 are inappropriate because in each case, the measurement is conducted during the isovolumic contraction phase. The mitral valve is closed, and diastole has already ended. Therefore, the signal measured by the sonographer is not an appropriate sample for assessing aortic insufficiency. (Footnote omitted.)

The Court finds that Wyeth has established that no reasonable physician could determine, based on this marginal echocardiogram, that Zaccaria has MAR.

IV

For the reasons set forth in this Letter Opinion, the following dispositions on Wyeth's eligibility challenges are made.

	Plaintiff	**Docket No.**	**Disposition**
1	Araiza, Patricia	L-3154-04	Granted
2	Ashman, Melody	L-3155-04	Granted
3	Bagwell, Donna	L-3181-04	Granted
4	Christensen, Fayann	L-3160-04	Granted
5	Ellison, Debra	L-2348-04	Granted
6	Fillmore, Marie	L-3157-04	Granted
7	Frame, Nancy	L-3090-04	Granted
8	Frederickson, Carol	L-3097-04	Granted
9	Greider, Robert	L-3115-04	Granted
10	Harden, Janette	L-3053-04	Granted
11	Harris, Nancy	L-3176-04	Granted
12	Hays, Oria	L-3075-04	Granted
13	Henry, Ryann	L-3093-04	Granted
14	Herold, Cherie	L-3099-04	Granted
15	Horne, Lisa A.	L-3246-04	Granted
16	Horspool, Glen R.	L-3255-04	Denied
17	Jackson, Jemma	L-3183-04	Granted
18	Johnson, Gary C.	L-3072-04	Granted
19	Keleshian, Ani	L-3114-04	Granted
20	Lamb, Gregoria	L-3198-04	Granted
21	Lindsay, Michelle	L-3202-04	Granted
22	Lindstrom, Robert J.	L-3092-04	Granted
23	Lofthouse, Geri	L-3098-04	Granted
24	Medel, Patsy	L-3172-04	Granted
25	Mehraban, Lucretia	L-3177-04	Granted
26	Meikle, Kayleen	L-3185-04	Granted
27	Milchak, Colleen	L-3188-04	Denied
28	Miller, Cassonja	L-3126-04	Denied
29	Monica, Matt	L-3130-04	Granted
30	Monsivais, Alfonso	L-3132-04	Denied
31	Morgan, Ann	L-3134-04	Granted
32	Nagle, Lenore	L-3139-04	Denied

33	Nute, Constance	L-3247-04	Granted
34	Ortiz, Colleen	L-3257-04	Denied
35	Parks, Dorothy	L-3268-04	Granted
36	Payne, Nikki	L-3282-04	Granted
37	Perkins, Jean	L-3285-04	Granted
38	Pitts, Margaret	L-3204-04	Granted
39	Prietto, Lorraine	L-3233-04	Granted
40	Renaud, Deborah	L-3267-04	Granted
41	Richman, Carol	L-3273-04	Granted
42	Robertson, Kathy	L-3280-04	Granted
43	Ross (Stallings), Tryna	L-3274-04	Granted
44	Rothe, Patricia I.	L-3276-04	Granted
45	Sheldon, Lorri M.	L-3173-04	Granted
46	Shiner, Julie	L-3187-04	Granted
47	Shurtz, Inga	L-3207-04	Granted
48	Sides, Eva	L-3195-04	Granted
49	Smith, Carol A.	L-3197-04	Granted
50	Smith, Deborah J.	L-3200-04	Granted
51	Smith, Kerry M.	L-3205-04	Denied
52	Smith, Rene D.	L-3208-04	Denied
53	Spencer, Donna	L-3214-04	Granted
54	Wells, Beverly	L-3152-04	Granted
55	Zaccaria, Tammie	L-3223-04	Granted

An Order reflecting these dispositions is enclosed with this Letter Opinion.

Very truly yours,

Charles J. Walsh, J.S.C.

CJW/len
Encl.