SUPERIOR COURT OF NEW JERSEY

CHARLES J. WALSH
JUDGE

BERGEN COUNTY JUSTICE CENTER
HACKENSACK, NJ 07601-7689
(201) 527-2690

SUPERIOR COURT BERGEN COUNTY
FILED
DEC 09 2004
DEPUTY CLERK

December 9, 2004

Anand Agneshwar, Esq.
Cara Petersen, Esq.
Geoffrey Michaels, Esq.
Sarah Cravens, Esq.
Sarah Brackney, Esq.
Jeff Britt, Esq.
Arnold & Porter
555 Twelfth Street NW
Washington, DC 20004-0106

Esther E. Berezofsky, Esq.
Mark R. Cuker, Esq.
Alexandra Gecz, Esq.
Williams, Cuker & Berezofsky
210 Lake Drive East
Cherry Hill, NJ 08002

Anita Hotchkiss, Esq.
Daniel K. Winters, Esq.
Porzio, Bromberg & Newman
100 Southgate Parkway
P.O. Box 1997
Morristown, NJ 07962

Barry Sugarman, Esq.
Pamela Gold, Esq.
Greg Shaffer, Esq.
Wilentz, Goldman & Spitzer
90 Woodbridge Center Drive
Suite 900, Box 10
Woodbridge, NJ 07095

John G. Wheeler, Esq.
Mitchell, McNutt & Sams
105 S. Front Street
Tupelo, MS 38804

Mitchell M. Breit, Esq.
Jeffrey Messinger, Esq.
Milberg, Weiss, Berdhad, Hynes
& Lerach
One Pennsylvania Plaza
New York, NY 10119-0165

Thomas Herten, Esq.
Terry Bottinelli, Esq.
Herten, Burstein, Sheridan, Cevasco,
Bottinelli, Litt, Toskos & Harz
25 Main Street
Hackensack, NJ 07601

Marc Bern, Esq.
Chris LoPalo, Esq.
Napoli, Kaiser, Bern & Assoc.
1 Greentree Centre, Suite 201
Marlton, NJ 08053

Robert D. Gholson, Esq.
Gholson & Orr
P.O. Box 6523
Laurel, MS 39441-6523

J. Robert Ramsay, Esq.
Ramsay & Hammond
106 Madison Plaza
P.O. Box 16567
Hattiesburg, MS 39404

Mario D'Angelo, Esq.
Hariton & D'Angelo
3500 Sunrise Highway
Suite T207
Great River, NY 11739

Thomas Sims, Esq.
Baron & Budd
The Centrum
3102 Oak Lawn Avenue, Suite 1100
Dallas, TX 75219-4281

Michael Farkas, Esq.
Seeger Weiss
One William Street
New York, NY 10004

Avram J. Blair, Esq.
Williams Bailey Law Firm
8441 Gulf Freeway
Suite 600
Houston, TX 77017

RE: IN RE: DIET DRUG LITIGATION
Master Docket No. BER-L-13379-04MT

JANNA ANDRADE v. WYETH, INC.
Docket No. BER-L-1502-04MT

PATRICIA ARIAZ v. WYETH, INC.
Docket No. BER-L-2329-04MT

TERRELL ARONSPEER v. WYETH, INC.
Docket No. BER-L-2318-04MT

TERRY BAILEY-SWAGER v. WYETH, INC.
Docket No. BER-L-1381-04MT

REGINA BARASSI v. WYETH, INC.
Docket No. BER-L-2390-04MT

KATHY BARRON v. WYETH, INC.
Docket No. BER-L-2306-04MT

SHERRI BELL v. WYETH, INC.
Docket No. BER-L-1402-04MT

KAREN BENSON v. WYETH, INC.
Docket No. BER-L-2398-04MT

ALFRED BLANCHARD v. WYETH, INC.
Docket No. BER-L-2417-04MT

LEANDRA BLOCK v. WYETH, INC.
Docket No. BER-L-2419-04MT

HERB BOER v. WYETH, INC.
Docket No. BER-L-2425-04MT

MARGARET BORDIERI v. WYETH, INC.
Docket No. BER-L-2430-04MT

MARY BRAUN v. WYETH, INC.
Docket No. BER-L-2399-04MT

SUSAN BUREK v. WYETH, INC.
Docket No. BER-L-1498-04MT

TERRI BURGESS-BRYANT v. WYETH, INC.
Docket No. BER-L-1499-04MT

TROY BURKS v. WYETH, INC.
Docket No. BER-L-1489-04MT

ULYSSES BURNS v. WYETH, INC.
Docket No. BER-L-1393-04MT

CATHY BUTCHER v. WYETH, INC.
Docket No. BER-L-2429-04MT

DENTON CANTWELL v. WYETH, INC.
Docket No. BER-L-2434-04MT

RAVEN CHADWELL v. WYETH, INC.
Docket No. BER-L-2415-04MT

DOLORES COLLINSWORTH v. WYETH, INC.
Docket No. BER-L-2459-04MT

L.V. COLSTON v. WYETH, INC.
Docket No. BER-L-1523-04MT

DIANE CORVEY v. WYETH, INC.
Docket No. BER-L-964-04MT

MARINA DeROSA v. WYETH, INC.
Docket No. BER-L-1517-04MT

VINCENT DINGILLO v. WYETH, INC.
Docket No. BER-L-1370-04MT

ALEXIS ESTREMERA-BRETT v. WYETH, INC.
Docket No. BER-L-1524-04MT

ROBERT GILDERSLEEVE v. WYETH, INC.
Docket No. BER-L-1376-04MT

ROBERT GORDON v. WYETH, INC.
Docket No. BER-L-1526-04MT

CHERYL GREENE v. WYETH, INC.
Docket No. BER-L-1395-04MT

YVONNE HARDNETT v. WYETH, INC.
Docket No. BER-L-970-04MT

DOROTHY JEKEL v. WYETH, INC.
Docket No. BER-L-1401-04MT

SARAH LARSON v. WYETH, INC.
Docket No. BER-L-1433-04MT

BEVERLY PADRATZIK v. WYETH, INC.
Docket No. BER-L-1448-04MT

CYNTHIA READ v. WYETH, INC.
Docket No. BER-L-1458-04MT

ANGELA REYNOLDS v. WYETH, INC.
Docket No. BER-L-1455-04MT

LYNETTE RICKMAN v. WYETH, INC.
Docket No. BER-L-1413-04MT

JOYCE RINGO v. WYETH, INC.
Docket No. BER-L-1412-04MT

WILLIAM ROACH v. WYETH, INC.
Docket No. BER-L-1098-04MT

LUPE ROBLES v. WYETH, INC.
Docket No. BER-L-5949-03MT

WILLIAM ROWE v. WYETH, INC.
Docket No. BER-L-1410-04MT

DEBRA RUBIN v. WYETH, INC.
Docket No. BER-L-368-04MT

YSOLA RUIZ v. WYETH, INC.
Docket No. BER-L-967-04MT

DONALD SCHAEFER v. WYETH, INC.
Docket No. BER-L-1464-04MT

STEVEN SIGNORE v. WYETH, INC.
Docket No. BER-L-1454-04MT

RON SMITH v. WYETH, INC.
Docket No. BER-L-1438-04MT

DALVE SMITH v. WYETH, INC.
Docket No. BER-L-1519-04MT

PHYLISS TAYLOR v. WYETH, INC.
Docket No. BER-L-1462-04MT

YOLANDA WALKER v. WYETH, INC.
Docket No. BER-L-1383-04MT

GLENANN YAHNKE v. WYETH, INC.
Docket No. BER-L-1478-04MT

Dear Counsel:

This matter is before the Court on applications by Wyeth Corporation, as the successor to American Home Products Corporation ("AHP") and each of its former subsidiaries, affiliates and divisions (collectively "Wyeth" or "defendants") challenging the eligibility of forty-nine (49) plaintiffs to exercise opt-outs from the Nationwide Class Action Settlement ("CAS"). These plaintiffs are: Janna Andrade ("Andrade"); Patricia Ariaz ("Ariaz"); Terrell Aronspeer ("Aronspeer"); Terry Bailey-Swager ("Bailey-Swager"); Regina Barassi ("Barassi"); Kathy Barron ("Barron"); Sherri Bell ("Bell"); Karen Benson ("Benson"); Alfred Blanchard ("Blanchard"); Leandra Block ("Block"); Herb Boer ("Boer"); Margaret Bordieri ("Bordieri"); Mary Braun ("Braun"); Susan Burek ("Burek"); Terri Burgess-Bryant ("Burgess-Bryant"); Troy Burks ("Burks"); Ulysses Burns ("Burns"); Cathy Butcher ("Butcher"); Denton Cantwell ("Cantwell"); Raven Chadwell ("Chadwell"); Dolores Collinsworth ("Collinsworth"); L.V. Colston ("Colston"); Diane Corvey ("Corvey"); Marina DeRosa ("DeRosa"); Vincent Dingillo ("Dingillo"); Alexis Estremera-Brett ("Estremera-Brett"); Robert Gildersleeve ("Gildersleeve"); Robert Gordon ("Gordon"); Cheryl Greene ("Greene"); Yvonne Hardnett ("Hardnett"); Dorothy Jekel ("Jekel"); Sarah Larson ("Larson"); Beverly Padratzik ("Padratzik"); Cynthia Read ("Read"); Angela Reynolds ("Reynolds"); Lynette Rickman ("Rickman"); Joyce Ringo ("Ringo"); William Roach ("Roach"); Lupe Robles ("Robles"); William Rowe ("Rowe"); Debra Rubin ("Rubin"); Ysola Ruiz ("Ruiz"); Donald Schaefer ("Schaefer"); Steven Signore ("Signore"); Ron Smith ("R. Smith"); Dalve Smith ("D. Smith"); Phyliss Taylor ("Taylor"); Yolanda Walker ("Walker"); and Glennann Yahnke ("Yahnke").

The Court conducted its third evidentiary hearing on Wyeth's challenges which began on November 16, 2004 and concluded on November 22, 2004. During that period, the Court heard testimony or considered depositions given by: Martin E. Goldman, M.D. ("Dr. Goldman"); Charles Gibbs Vasey, M.D. ("Dr. Vasey"); Sanjiv Kaul, M.D. ("Dr. Kaul"); Jason Lazar, M.D. ("Dr. Lazar"); Muhamed Saric, M.D. PhD ("Dr. Saric"); Mark V. Sherrid, M.D. ("Dr. Sherrid"); Arthur Millman, M.D. ("Dr. Millman"); William F. Lassetter, M.D. ("Dr. Lassetter"); Howard Cohen, M.D. ("Dr. H. Cohen"); Roger Billhardt, M.D. ("Dr. Billhardt"); James Colasacco, M.D. ("Dr. Colasacco"); Nael Skop, M.D. ("Dr. Skop): Thomas Knox. M.D. ("Dr. Knox"); Gerald I. Cohen, M.D. ("Dr. G. Cohen"); Chunguang Chen, M.D. ("Dr. Chen"); Peter S. Rahko, M.D. ("Dr. Rahko"); Aasha S. Gopal, M.D. ("Dr. Gopal"); and Kenneth Ong, M.D. ("Dr. Ong"), all of whom were cardiologists. The Court also considered the testimony of Frank Miele ("Miele"), an engineer and physicist, given during the previous two (2) eligibility hearings. Much of the direct testimony of each of these witnesses

was presented through affidavits, certifications or reports which were adopted during the course of the evidentiary hearing. In addition, the Court considered the contents of several treatises which were recognized in the proceedings as reliable under **N.J.R. Evid.** 803 (c)(18), including: Harvey Feigenbaum, **ECHOCARDIOGRAPHY** (5th Ed. 1994) ("Feigenbaum Text"); Arthur Weyman, **PRINCIPLES AND PRACTICES OF ECHOCARDIOGRAPHY** (2nd Ed. 1994) ("Weyman Text"); Novin C. Nanda, **ATLAS OF COLOR DOPPLER ECHOCARDIOGRAPHY** (1989); J.P. Singh, et al., *Prevalence and Clinical Determinants of Mitral, Tricuspid, and Aortic Regurgitation (The Framingham Heart Study)*, 83 *Am. J. Cardiology* (1999) ("Singh"); and *The Task Force on Valvular Regurgitation Recommendation for Evaluation of the Severity of Native Valvular Regurgitation with Two-dimensional and Doppler Echocardiography ("ASE Standards"), J. Am. Soc. Echocardiography*, 16: 777 (2003).

The Court previously discussed the standards to be used in assessing these eligibility challenges. *In Re: Diet Drug Litigation*, BER-L-7718-03 (Law Division April 13, 2004) ("*Eligibility Standards Opinion*") (slip op. at 31-36). Each plaintiff seeking to exercise an intermediate opt-out ("IOO") or back end opt-out ("BEOO") is required by the CAS to establish that he or she is FDA Positive by a qualifying echocardiogram. FDA Positive, as defined, contains two (2) standards. First, the quantitative measurements that constitute FDA Positive heart valve regurgitation are as follows:

> Aortic Valve – Mild or greater regurgitation, defined as regurgitant jet diameter in the parasternal long-axis view (or in the apical long-axis view, if the parasternal long-axis view is unavailable), equal to or greater than ten percent (10%) of the outflow tract diameter (JH/LVOT).
>
> Mitral Valve – Moderate or greater regurgitation, defined as regurgitant jet area in any apical view equal to or greater than twenty percent (20%) of the left atrial area (RJA/LAA).

CAS § I.22.b.

The CAS also requires that specific criteria be used in determining whether these levels of valvular regurgitation are present. Singh at 897-98.

Second, the CAS requires the echocardiograms be performed and evaluated by "qualified medical personnel" in accordance with the methodology set forth in two (2) referenced texts – The Feigenbaum Text and the Weyman Text. *Eligibility Standards Opinion* (slip op. at 12-16).

This Court already has determined that "Wyeth [may] disqualify an IOO or BEOO if it establishes that the performance and/or evaluation of the echocardiogram (at issue) was medically unreasonable as a matter of law. Stated another way, Wyeth [may] . . . disqualify . . . [an] IOO or BEOO if it can show that . . . [an] expert's conclusions respecting the echocardiogram supporting the opt-out could not 'reliably flow from the facts known to the expert and the methodology used.'" *Eligibility Standards Opinion* (slip op at 31) (citations omitted).

For the reasons which follow, the Court finds that Wyeth has satisfied the Court that the echocardiograms supporting claims of plaintiffs: Patricia Ariaz, Terrell Aronspeer, Terry Bailey-Swager, Regina Barassi, Kathy Barron, Sherri Bell, Karen Benson, Alfred Blanchard, Leandra Block, Herb Boer, Margaret Bordieri, Mary Braun, Susan Burek, Terri Burgess-Bryant, Troy Burks, Ulysses Burns, Cathy Butcher, Raven Chadwell, Dolores Collinsworth, Diane Corvey, Marina DeRosa, Vincent Dingillo, Alexis Estremera-Brett, Robert Gildersleeve, Robert Gordon, Yvonne Hardnett, Dorothy Jekel, Beverly Padratzik, Cynthia Read, Angela Reynolds, Lynette Rickman, Joyce Ringo, William Roach, Lupe Robles, William Rowe, Debra Rubin, Ysola Ruiz, Donald Schaefer, Steven Signore, Ron Smith, Phyliss Taylor, Yolanda Walker, and Glennann Yahnke have not been performed and/or interpreted in a medically reasonable manner. Accordingly, the Complaints filed by these plaintiffs are dismissed and those plaintiffs are returned to the Class. The Court, however, finds that Wyeth has failed to support its eligibility challenge as to plaintiffs: Janna Andrade, Denton Cantwell, L.V. Colston, Cheryl Greene, Sarah Larson, and Dalve Smith. Accordingly, Wyeth's motion to dismiss will be denied as to them. The findings of fact and conclusions of law supporting these determinations are reported below.

I

A.

In order to determine whether Wyeth's challenges have merit, one has to understand the underlying medical conditions claimed by these plaintiffs and the tools used to detect and treat those conditions. Mild aortic and moderate mitral

regurgitation are the two (2) medical conditions that permit either an IOO or BEOO. These conditions involve the backward or reverse flow of blood through defective valves during the heart's pumping cycle.

The heart consists of four (4) chambers: the right atrium, the right ventricle, the left atrium and the left ventricle. The right atrium receives deoxygenated blood from the body and ejects that blood into the right ventricle through the tricuspid valve; the right ventricle then pumps that blood across the lungs through the pulmonic or pulmonary valve for oxygenation. The oxygenated blood, in turn, is received by the left atrium, which ejects blood into the left ventricle through the mitral valve. The left ventricle then pumps that oxygenated blood into the aorta through the aortic valve, and from there to the rest of the body. The heart chambers are connected by valves that open to allow blood to pass through and then close to prevent significant backflow. This process ensures the proper directional flow of blood through the heart.

The chambers of the heart fill and empty in a two-phase cardiac cycle that comprises diastole - - the filling cycle, and systole - - the emptying cycle. For our purposes, we are concerned with the active contraction of the left ventricle and pumping of blood into the aorta through the open aortic valve during systole. Throughout this phase the mitral valve is closed to prevent backward flow or regurgitation from the left ventricle into the left atrium. We are also interested in the other phase of the cardiac cycle -- diastole -- which occurs when blood enters the left ventricle through the open mitral valve. During this phase the aortic valve is closed to prevent leakage or regurgitation from the aorta back into the left ventricle.

Healthy heart valves rarely prevent all regurgitation. When these valves are closed there may be a minimal amount of leakage -- trace regurgitation. Moreover, during routine valve closure, blood caught between the valve leaflets is displaced backward resulting in some blood backflow. This backward displacement of blood is considered part of the closing process, and is not regurgitation. According to Weyman, "true" mitral regurgitation "should last throughout most or all of systole." Weyman Text at 429. A brief or non-sustained jet of mitral regurgitation is an indication that the regurgitation is usually less than mild. The same source teaches that "true" aortic regurgitation should continue "throughout diastole." *Id.* at 529. Aortic regurgitation that is brief or non-sustained is usually less than mild.

Normally blood flows at a uniform velocity in a forward direction. This normal blood flow is laminar. Regurgitant flow, on the other hand, produces a jet

of mixed velocities which is turbulent. It is this turbulent flow which is one of the focuses of echocardiography.

According to Singh, the degree of valvular regurgitation or valvular insufficiency is classified as trace, mild, moderate, or severe. Trace aortic regurgitation and trace and mild mitral regurgitation are common in the general population and are considered normal findings. Singh at 900.

B.

Echocardiography is a principal technique used to evaluate the heart, including its function, structure and the flow of blood through it. The underlying principle involved in echocardiography is the use of high frequency sound waves. A transducer is placed on the patient's chest wall which emits sound waves that bounce off of the heart's structures, and that information is translated into moving images of those structures on a screen. There are several different techniques available in echocardiography. The technique relevant here is Doppler echocardiography. "Doppler echocardiography is based on the change in frequency of a sound wave that occurs when it strikes a moving target – in this case the red blood cells." Weyman Text at 143.

Color flow Doppler is used to display the movement of blood flow through the heart by assigning different colors depending upon the direction and velocity of the blood flow. By convention, laminar blood flowing towards the transducer is depicted in shades of red, and laminar blood flowing away from the transducer is depicted in shades of blue; darker shades indicating slower velocity and lighter shades higher velocity. *See* Feigenbaum Text at 33. Turbulent blood flow is depicted in a "mosaic," multi-colored pattern, thus displaying the different velocities and directions of the blood in the area under study. The absence of blood flow is depicted by black on color flow Doppler. Thus, in Doppler echocardiography blood flow is represented as discrete color areas (jets) in real time, superimposed on two-dimensional images of the heart's structure.

The quality of an echocardiogram depends on a number of factors including: the patient's body; the technical skill of the physician or sonographer performing the study; the equipment used and its settings; and, the physician's interpretation and measurements. The proper performance of an echocardiogram in the cases before this Court must follow the guidelines set forth in the Weyman and Feigenbaum Texts.

Settings on the echocardiographic equipment can have a substantial impact on the quality of the images and the accuracy of the recordings. Two (2) key settings on the equipment are referred to as the Nyquist limit and gain setting. The Nyquist limit establishes the maximum velocity of laminar blood flow that can be detected in a monochromatic fashion (solid color).[1] When the velocity of the blood flow exceeds the pre-set Nyquist limit the color depicting the blood flow "wraps around" so that if the flow is laminar it appears to be flowing in the opposite direction. Turbulent blood flow in such circumstances appears as a "mosaic," multi-colored pattern. If the Nyquist limit is set too low, the velocity of normal blood flow may exceed a low Nyquist setting and will appear as turbulent regurgitation, even though it is actually normal non-regurgitant flow. Additionally, when the Nyquist limit is set too low it will exaggerate the degree of any regurgitation present by including normal blood flow velocity in the turbulent regurgitant jet area. Virtually all the experts who testified here agree that a higher Nyquist limit generally leads to a more reliable echocardiogram. A recent consensus report by the American Society of Echocardiography stressed the importance of an appropriate Nyquist limit.

> Numerous technical, physiologic and anatomic factors affect the size of the regurgitant area and therefore alter its accuracy as an index of regurgitation severity. Jet size is affected by instrument factors, especially pulse repetition frequency (PRF) and color gain. Standard technique is to use a Nyquist limit (aliasing velocity) of 50/60 cm/sec, and a color gain that just eliminates random color speckle from non-moving regions. Jet area is inversely proportional to PRF, and *substantial error can be introduced with use of higher or lower settings* than the nominal settings to which echocardiographers have become accustomed.

ASE Standards at 777-778 (emphasis added).

A color Doppler gain setting is another important variable in the echocardiographic system. If the gain on echocardiographic equipment is set too

[1] As the Feigenbaum Text at 29 notes: "The major disadvantages of pulsed Doppler is that the velocity one can measure is limited. The pulsed system inherently has a pulsed repetition frequency or PRF. The PRF determines how high a Doppler frequency the pulse system can detect.... The inability of a pulsed Doppler system to detect high-frequency Doppler shifts is known as "aliasing." The upper limit of frequency that can be detected with a given pulsed system is known as the "Nyquist" limit or number. This limit is defined as one half the pulse repetition frequency or PRF. *See* Miele Certification at ¶¶ 16, 17, 31 and 32.

high, the image may be artificially increased and may also present "background noise" or "speckling," seriously degrading the quality of the echocardiogram and making it difficult to assess true regurgitation. Weyman Text at 240-241 and 258. As Weyman teaches, the "detection of the Doppler frequency shift is critically dependent on the signal/noise ratio, and every effort must be made to maximize this relationship." Weyman Text at 256. To do so, Weyman suggests that:

> Ideally, as in imaging studies, one begins with a high gain setting to be sure that all of the signal present is appreciated. The gain is then gradually decreased to a point where the signal is optimally displayed and the associated noise and mirroring artifacts ... are at a minimum.

Weyman Text at 258.

Another important technical aspect of echocardiographic acquisition relates to the angle the transducer is placed relative to the heart when images are recorded. If those images are not acquired in the appropriate angle or plane, the amount of regurgitation and the sizes of the chambers of the heart may appear larger or smaller than they really are. Again, Weyman teaches that "doppler frequency shifts are maximal when the sound beam is parallel to the flow vector (i.e., aligned parallel to the path of blood flow in the vessel of interest).... The Doppler beam, therefore, is ideally aligned parallel, rather than perpendicular, to flow because larger frequency shifts are easier to detect and the output is less subject to random fluctuation." Weyman Text at 256.

FDA Positive heart valve regurgitation involving the aortic valve requires that two (2) measurements be made: (1) the height of the jet of aortic regurgitation

("JH"); and (2) the height of the left ventricular outflow tract ("LVOT").[2] The JH measurement is the linear width of the jet of aortic regurgitation as it leaks backward into the left ventricle. Feigenbaum tells us that this measurement must be made as close as possible to the point of origin of that jet on the ventricular side of the aortic valve. Feigenbaum Text at 283. Otherwise, the measurement will be exaggerated by the spray or "nozzle effect" that occurs when high velocity liquid (regurgitant blood) is ejected through a narrow orifice into a lower pressure chamber (the left ventricle in diastole). *Id.* at 283. The LVOT is the region of the left ventricle below the aortic valve. These two (2) measurements are then expressed as a ratio, JH/LVOT. Current technology utilizes digitally calibrated calipers or cursors, which can measure the linear width of the JH and LVOT on a frozen frame or image using a digitally calibrated caliper or cursor, from commercially available software packages.

The definition of FDA Positive mitral regurgitation also requires two (2) measurements to be made: (1) the regurgitant jet area, or "RJA"; and (2) the left atrial area, or "LAA." Unlike the linear width measurements made of the JH and LVOT, the RJA and LAA are area measurements. Again these measurements are expressed as a ratio, RJA/LAA, in assessing the degree of mitral regurgitation. These measurements of the RJA and LAA can be done while the sonographer is

[2] The same diagram illustrating how this measurement is actually made is displayed in the Feigenbaum Text at 285, Fig. 6-101, and the Weyman Text at 534. The illustration as it appears in Weyman is reproduced below.

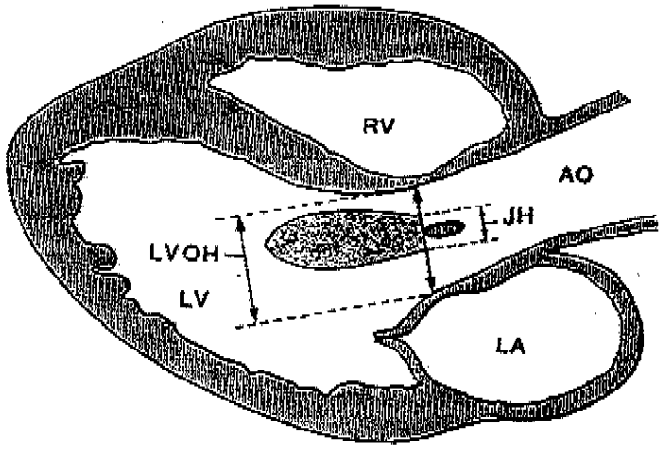

Fig. 19–61. The measurement of regurgitant jet height. Regurgitant jet height (JH) is measured at the aortic valve level in the parasternal long axis view. AO = aorta; LA = left atrium; LV = left ventricle; LVOH = left ventricular outflow tract height; RV = right ventricle. (From Perry GJ, et al.: Evaluation of aortic insufficiency by Doppler color flow mapping. J Am Coll Cardiol 9:952, 1987. Reprinted with permission from the American College of Cardiology.

acquiring the study, or off-line, and are referred to as tracings or planimetry when using the technology just described.

II

A.

The Court considered the qualifications of the experts as required by **N.J.R. EVID.** 702. *Kemp ex rel Wright v. State*, 174 N.J. 412, 427 (2002). Overall, the Court found the experts called by Wyeth and the plaintiffs to be well qualified, or at least qualified, in the areas offered.

The Court finds Drs. Goldman, Kaul, Chen and Vasey well qualified in the field of echocardiography. Dr. Goldman is a Professor of Medicine at the Mt. Sinai School of Medicine in New York and has taught at that medical school for over twenty (20) years. Dr. Goldman has written extensively in the field of echocardiology and holds positions as a director of the American Society of Echocardiography ("ASE"), one of the bodies seeking to promote advances in the field of echocardiography, as well as several of its committees. He is the immediate past President of the New York Echocardiography Society. Dr. Kaul is currently a Professor of Medicine and Biomedical Engineering at the University of Virginia where he holds an endowed chair. He also is the Director of the Cardiovascular Imaging Center at the same institution. Dr. Kaul has published extensively, has held numerous editorial board positions at leading cardiology journals in the United States and has been a board member of the ASE. Dr. Chen is a Clinical Professor of Medicine at the Mt. Sinai School of Medicine in New York and is the Director of Cardiac Non-Invasive Laboratory at the Newark Beth Israel Medical Center. He has published extensively in the field of echocardiography and is a Level III echocardiographer. Dr. Vasey, too, has strong credentials in the field of echocardiography. He presently serves on the board of the ASE, as well as its operating committees. Copies of the curricula vitae of these four (4) physicians are part of the hearing record.

The plaintiffs, too, produced qualified witnesses. Dr. Lazar is a board certified cardiologist with Level III echocardiographic training. He is currently an Echocardiography Attending Physician at New York Hospital in Queens and the Director of Non-Invasive Cardiology and Associate Director of Cardiovascular

Training at the Medical Center at SUNY-Brooklyn (Downstate Medical Center).[3] Dr. Lassetter is a Level II cardiologist in private practice in Utah. He is board certified in internal medicine, cardiology and interventional cardiology. Dr. Colasacco claims Level III echocardiographic training and is engaged in private practice in Amityville, New York. He is board certified in internal medicine and cardiology. Dr. G. Cohen is the Director of Non-Invasive Cardiology at St. John Hospital and Medical Center in Detroit, Michigan. He has published in the field of echocardiography and is board certified in internal medicine and cardiology. Dr. H. Cohen is in private practice in Chicago, Illinois. He claims Level III training in echocardiography but has not sat for any boards on this subject. Dr. Knox is a Level II echocardiologist and is a Clinical Instructor at the University of Connecticut School of Medicine. Dr. Skop is in private practice in Paoli, Pennsylvania. He is board certified in internal medicine and cardiology. Dr. Billhardt is in private practice in Chicago, Illinois. He is board certified in internal medicine and cardiology and claims Level III echocardiographic training. He has not sat for any boards on this subject, however. Dr. Rahko is an Associate Professor of Medicine at the University of Wisconsin Medical School. He has published in the field of echocardiography and serves as a reviewer for several medical journals. The curricula vitae of these experts also are included as part of the record.

The expert cardiologists appointed by the Court under the terms of the *Eligibility Standards Opinion* also are well qualified. Dr. Saric is presently the Director of the Echocardiography Laboratory at the University of Medicine and Dentistry of New Jersey and has Level III echocardiographic training. In addition to his M.D. degree and board certifications in cardiology and echocardiography, Dr. Saric holds a PhD in medical sciences from New York University. Dr. Sherrid is presently the Director of the Echocardiography Laboratory at St. Luke's Roosevelt Hospital Center and serves as an Associate Professor of Clinical Medicine at the Columbia University College of Physicians and Surgeons. He is the President of the New York Echocardiography Society. Dr. Gopal is the Director of Echocardiography at St. Francis Hospital, Roslyn, New York and is an Associate Professor of Medicine at SUNY (Stonybrook, New York). She is a Level III echocardiographer and has published in the field of echocardiography. Dr. Ong is the Associate Chief of Cardiology and the Director of the Cardiac Non-

[3] Mr. Miele provided general information about the laws of physics governing echocardiography and the equipment used in its practice during the Group I and II hearings. He also provided specific information on Nyquist limits and the effect of transducer angles on color Doppler. As noted later in this Letter Opinion, the Court found Mr. Miele quite knowledgeable in these areas and the Court has referred to is submission in this Letter Opinion. Mr. Miele's resume is part of the record.

Invasive Imaging Laboratory at the Brooklyn Hospital Center. He is a Level III echocardiographer and has published in the field of echocardiography. Dr. Millman is the Chief of Cardiology at Trinitas Hospital in Elizabeth, New Jersey. He has had extensive experience in echocardiography and teaches cardiology fellows from the Seton Hall Graduate School of Medical Education. The curricula vitae of these experts also are part of the record.

B.

As in the past, the Court's decisions in these individual eligibility cases are based largely on the quality of the echocardiograms. The initial reports of physicians with respect to virtually all these challenged echocardiograms have significantly overstated the pathology observed and/or claimed that the echocardiograms were of good diagnostic quality. Accordingly, as in the eligibility hearings on the Group 1 and Group 2 plaintiffs (*see Armstrong et al v. Wyeth, Inc.*, (BER-L-7024-03MT) and *Comparato v. Wyeth, Inc., et al* (BER-L-332-04) Letter Opinions dated August 4, 2004, slip op. at 10-12 and dated September 22, 2004, slip op. at 14-15), the plaintiffs' experts spent much of their time seeking to excuse and explain these overstatements and/or the poor technical quality of the echocardiograms. In Alfred Blanchard's case, for example, Dr. Lassetter concluded in his Affidavit that Blanchard's echocardiogram was "of diagnostic quality with appropriate settings for interpretation" and supported the conclusions of one of the reviewers that Blanchard had moderate aortic regurgitation. But, during the Eligibility Hearing, Dr. Lassetter admitted that the quality of the echocardiogram supporting his conclusion was less than ideal.

> JUDGE WALSH: Hold it, hold it, before you do that, how would you characterize the gain here, Doctor?
> THE WITNESS: I think the gain is relatively high, but you can see an aortic regurgitant jet there.
> JUDGE WALSH: I'd say it's very high.
> Do you disagree --
> THE WITNESS: That's the subjective differences in looking at echocardiograms in trying to make a decision. My subjective view of this is that it is technically marginal, but it is interpretable.
> JUDGE WALSH: It looks to me like most of the color is in the tissue.
> THE WITNESS: Some of the color is in the tissues.

JUDGE WALSH: And you can't even tell a principal difference between the color reflected in the tissue and that in the valve space.

Isn't that a fair characterization looking at this?

THE WITNESS: In some frames, that is correct, but in the frames that I'm referring to where it shows the direction of an aortic regurgitant jet, sir, I would submit to you that there is aortic regurgitation present here.

JUDGE WALSH: If I were to characterize the quality of this echocardiogram as horrible, would you agree with that?

THE WITNESS: I call it technically marginal.

In other instances, Nyquist limits of 41 cm/sec, well below the Nyquist limits outlined in the *ASE Standards* at 777-778 (50-60 cm/sec) and in the Weyman Text at 245 (60-90 cm/sec), appear in echocardiograms supporting the opt-outs. In the face of such obvious deviations from proper echocardiographic practice, other plaintiffs' experts were left to opine that the clear capacity that this low Nyquist limit to inflate any observed regurgitant jet were overwhelmed by angle effects where views were taken in the parasternal long-axis view ("PLAX").

In many instances, the techniques used in acquiring the echocardiographic images fell so far below appropriate practice as to make the data reported and conclusions made by plaintiffs' experts virtually worthless in either diagnosis or treatment. With respect to the forty-nine (49) plaintiffs included in this Letter Opinion, the experts appointed by the Court concluded that with respect to forty-three percent (43%) of them, the echocardiograms were so technically inadequate that reasonable medical conclusions could not be drawn from them.

Plaintiffs were aware that the qualifying echocardiograms in issue would be used to support the opt-outs sought. As will be seen, however, in the forty-nine (49) cases reviewed here, many of the submitted echocardiograms were of such poor quality or were interpreted in a manner so plainly at odds with good medical practice that they cannot, as a matter of law, support those plaintiffs' claims to qualify as FDA Positive. Overall, the experts appointed by the Court opined in an astounding eighty-nine point eight percent (89.8%) of the cases that the FDA Positive mitral or aortic regurgitation determinations made by plaintiffs' experts were not medically reasonable.

The findings with respect to the forty-nine (49) plaintiffs follow in the next section of this Letter Opinion. Where credibility determinations are made here, they are reflected in the findings reported below.

III

A. JANNA ANDRADE

Andrale relies on a May 22, 2002 echocardiogram performed by Associates in Cardiology, Ltd. and a report by Dr. Neal Ruggie. Dr. Ruggie found that Andrade had moderate aortic regurgitation ("MMAR") using CAS criteria -- JH/LVOT = 29%.

The May 22, 2002 echocardiogram was reviewed by three (3) experts: Dr. Chen, Dr. Saric and Dr. Lazar. Both Drs. Chen and Saric found that the claimed MMAR diagnosis was unsupported after their review of the echocardiogram in the PLAX. Dr. Chen found only "a tiny, noncontinuous AR jet stream." Dr. Chen believed that the JH was not measured "just below the valve" and the jet was not "fully developed." Moreover, Dr. Chen claims that the jet was measured obliquely -- not a true PLAX view. Even so, Dr. Chen finds the JH/LVOT to be 5.8%.[4] Dr.

---

[4] Dr. Chen's major complaint as to Andrade was the measurement of JH and LVOT.

> Q. Let's go to the next slide and is this another jet that you measured?
> A. Yeah, this is another jet you can see real clear. I tried to go frame by frame to look at the jet where available and clear and big, so I tried to measure everything. By eyeball, it's similar, but sometimes when you measure it, it comes out a little bit different. And so this again is aortic valve, and you can see the jet proximal part just a little bit, but you can still say pretty close so it measures 1.6, and it's probably why a little bit bigger because little bit more downstream, but it's still tiny.
> Q. When you say "proximal part of the jet," what are you referring to?
> A. That means it's just below the aortic valve, like this valve here.
> JUDGE WALSH: And what was the jet height on that?
> THE WITNESS: This one is 0.16. We got 0.12 something, 1.3, 1.6.
> Q. Let's go to the next frame.
> A. And then you measure aortic outflow tract. So in this case, I play frame by frame to see what really LVOT is. Sometimes AVOT can be misleading -- if you see still frame, you can have some problem. But if you play frame by frame, you can see very clear. This part of AVOT, you see the aortic valve close, but this part is pretty clear, but this part is aortic annulus has some blooming artifact.
> JUDGE WALSH: Brooming artifact.
> THE WITNESS: B-L-O-O-M-I-N-G, so if you -- sometimes if gain was high or some machinery setting, it's structured to have a brighter signal and can have artifact cause bloom, like flower.

Saric concurs that the PLAX views do not support a finding of MMAR. According to Dr. Saric, the technician at Associates in Cardiology, Ltd. measured the JH/LVOT as .18/2.27 or 7.9%. Dr. Saric's own measurements indicate that the JH/LVOT is 8.4%. None of these measurements support even mild aortic regurgitation ("MAR").

Dr. Lazar disagrees with these two (2) experts and claims that Andrade has MAR putting the JH/LVOT at 11% (the actual measurements indicated a JH of .3 and a LVOT of 2.2 which computes to 13.6%). He does concede that the echocardiogram does not support a diagnosis of MMAR. Dr. Lazar was challenged on the question of whether the aortic jet was holodiastolic and whether the jet was measured within one (1) centimeter of the valve plane, *see ASE Standards* at 780, but he maintained his opinion in the face of these challenges.

While the Court believes Drs. Chen and Saric are correct and the JH/LVOT when measured properly yields a percentage of less than 10%, it cannot say that Wyeth has convinced it that no medically reasonable conclusion could be otherwise. Accordingly, the Court finds that Wyeth has failed to satisfy it that Dr. Lazar's conclusion that Andrade has MAR is medically unreasonable.

B. PATRICIA ARIAZ

Ariaz relies on a September 3, 2002 echocardiogram and report by Dr. Robin S. Friedberg. Dr. Friedberg found that Ariaz had moderate mitral regurgitation ("MMR") using CAS criteria -- RJA/LAA = 23%. Dr. Friedberg noted that the quality of the echocardiogram was "good."

The September 3, 2002 echocardiogram was reviewed by three (3) experts: Dr. Goldman, Dr. Saric and Dr. Lassetter. Dr. Saric found that the color gain settings on this study were "often so high that color speckles fill almost the entire color box." Moreover, the study was conducted at a minimally acceptable Nyquist limit of 51 cm/sec. Based on this, Dr. Saric concluded that the study lacked the technical rigor which would permit reliable medical conclusions to be drawn from

---

And you can have artifact and so that's probably the case. So if you measure the aortic, the left ventricular outflow tract just below annulus, so in this case, it measures 2.35.

Q. And is that FDA-positive regurgitation when you put the percentages together?

A. No.

JUDGE WALSH: It's about 5 percent more or less.

A. Yeah, really looking by eye and you measure, I think either way.

it. Dr. Goldman agreed that the study was poorly done because "[t]he color Doppler gain was set high, but the study was interpretable." Dr. Goldman found there was "no sustained holosystolic flow throughout the cardiac cycle," and that any claimed mitral regurgitation appeared to be backflow.

Dr. Lassetter came to a different conclusion. He found that Ariaz has MMR based on his finding that a representative RJA of 4.07 cm^2 and a LAA of 14 cm^2 = 29%. However, he conceded during his testimony that many of the views he claimed supported a diagnosis of MMR were actually of other cardiac valves, specifically the tricuspid. He also conceded that Ariaz's purported MMR occurred during early systole when one would expect to see backflow. Generally, MMR should be present in most or all of systole. Weyman Text at 429.

The Court has reviewed the echocardiogram and accepts Dr. Saric's conclusion that the high color gain which distorts any observed jets and creates artifact makes this echocardiogram so technically deficient that no reasonable medical conclusion can be drawn from it. To the extent that it can be read with any reliability, the Court accepts Dr. Goldman's conclusion that any observed phenomenon was backflow rather than mitral regurgitation.

Virtually all the experts agree that high color gain makes any quantitative measurements difficult or impossible to make. Hence, any quantitative conclusion such as that made by Dr. Lassetter is not medically responsible under these circumstances. For these reasons, the Court finds that Wyeth has established that Ariaz's echocardiogram was not performed in a technically adequate fashion and no quantitative conclusions can be drawn from it.

C. TERRELL ARONSPEER

Aronspeer relies on an October 17, 2002 echocardiogram and a report by Dr. Marcus Braun. Dr. Braun found that Aronspeer (incorrectly identified as Speer on the report) had MAR using CAS criteria -- JH/LVOT = 24%. Dr. Braun observed that "this [was] a technically adequate study."

The October 17, 2002 echocardiogram was reviewed by three (3) experts: Dr. Goldman, Dr. Saric and Dr. Lassetter. Both Drs. Saric and Goldman found the study was technically adequate but in the words of Dr. Saric, "[t]he quality of this study is questionable as the gain settings are so high that the color fills almost the entire Doppler box." Dr. Goldman also commented on the color gain but felt the echocardiogram was interpretable. Drs. Saric and Goldman found that the

echocardiogram did not demonstrate Aronspeer had MAR. When Dr. Saric measured the JH/LVOT ratio, he reported 8.7% but noted "[e]ven this JH/LVOT ratio is likely generous given the high color gain settings." Dr. Goldman did not even attempt calculating a ratio finding that "[t]here is no sustained turbulent holodiastolic flow throughout the cardiac cycle."

Dr. Lassetter concluded that Aronspeer had MMAR using a JH/LVOT ratio of 31%. Dr. Lassetter conceded that he erroneously noted several pages from Aronspeer's echocardiogram were taken in the PLAX when, in fact, they were taken from the Apical 5 chamber view (a non-approved view -- the Apical 3 chamber view is the long axis view referred to in the CAS). At first, he attributed the mistake to a typographical error but in the context of his Affidavit it was plainly more than that. He also conceded that the aortic jet he described as MMAR was not holodiastolic on the echocardiogram in the approved PLAX view. He sought to minimize this obvious fact by claiming without support that the jet was eccentric. He acknowledged that the Weyman Text teaches that aortic regurgitation is "a high velocity turbulent diastolic flow originating just below the aortic valve immediately after valve closure and generally continuing throughout diastole." Weyman Text at 529. But, again, he sought to minimize this by claiming this finding is generally seen only in ideal clinical practice.

There is no support for Dr. Lassetter's conclusion that MMAR is present here. In the PLAX view, it is evident from the echocardiogram that there is no sustained jet. When one adds to this the analytical difficulties evident on the tape, there is no credible evidence supporting even an MAR diagnosis. Accordingly, the Court finds that Wyeth has established that no reasonable physician reading this marginally acceptable echocardiogram could conclude Aronspeer has MAR.

D. TERRY BAILEY-SWAGER

Bailey-Swager relies on a December 17, 2002 echocardiogram and a report by Dr. Jason Lazar dated April 7, 2003. Dr. Lazar found that Bailey-Swager had MMR using CAS criteria -- RJA/LAA = 22%.

The December 17, 2002 echocardiogram was reviewed by three (3) experts: Dr. Vasey, Dr. Saric and Dr. Lazar. Dr. Saric found the Nyquist limit to be low though "appropriate" at 51 cm/sec but said "the study is difficult to interpret because of relatively high color gain settings." Nevertheless, Dr. Saric found that "there is barely any aliased jet of mitral regurgitation in any of [the] apical views." Dr. Vasey did not have any complaints about the technical quality of the

echocardiograms but, like Dr. Saric, concluded that "[t]he purported mitral regurgitation included entirely ... non-aliased, low velocity flow."

Dr. Lazar was of a different view although his Echocardiogram Review and Assessment contains virtually no information supporting his MMR diagnosis. The few frames reported in his Echocardiogram Review and Assessment were not relied upon during his testimony. During his direct examination on November 16, 2004, he admitted that the RJAs placed by the technician were overtraced but still concluded that the RJA/LAA ratio was greater than 20%. On cross-examination, he further admitted that he had difficulty identifying a holosystolic flow and virtually all the RJA measurements he pointed to were in early systole, when backflow is to be expected.

The Court believes that no reasonable echocardiologist could conclude that the RJA identified by Dr. Lazar was a true aortic jet. The echocardiogram quality was marginal and the RJA seen by Dr. Lazar was in early systole. When confronted during cross-examination, Dr. Lazar could not show any consistent presence of a mitral jet during most or all of systole. The Court concludes that Wyeth has established that no reasonable echocardiologist could find that Bailey-Swager has MMR based on this echocardiogram.

E. REGINA BARASSI

Barassi relies on a September 30, 2002 echocardiogram and report by Dr. Stanley S. Schrem. Dr. Schrem found that Barassi had both MAR and MMR using CAS criteria -- JH/LVOT = 25%; RJA/LAA = 20%. Dr. Schrem reported that the study quality was "poor."[5]

The September 30, 2002 echocardiogram was reviewed by three (3) experts: Dr. Goldman, Dr. Saric and Dr. Lassetter. Dr. Saric found that the echocardiogram was not conducted in a technically adequate manner so that reliable medical conclusions could be drawn from it. Specifically, Dr. Saric observed that "[c]olor gains on this study are often so high that color speckles fill almost the entire color box." Dr. Goldman concurred though he found that the echocardiogram could be interpreted. He observed that "[t]he color Doppler gain was set high and the Nyquist limit varied between 46-51 cm/sec. Those frames with a Nyquist limit of 46 cm/sec are not interpretable." Dr. Goldman concluded that a diagnosis of MAR

[5] The technician's measurements both as to MAR and MMR differed somewhat from those of Dr. Schrem.

and/or MMR is inappropriate since the jets seen were neither holosystolic nor holodiastolic.

Dr. Lassetter, who claims Level II echocardiography training, testified that Barassi had both MAR and MMR. He conceded that the alleged MAR and MMR were not seen throughout most or all of the appropriate cardiac cycle but excused this by observing that "[b]ecause the heart is constantly in motion and potentially moving in and out of plane during an echo exam and given the inherent limitations in technical capabilities … there are no absolutes."[6]

The Court finds that Wyeth has established that this echocardiogram was of such poor quality that no medically reasonable conclusions could be drawn from it. The gain settings and Nyquist limit used here tend to both inflate and camouflage the true extent of the aortic and mitral jets. Considering these distortions, the Court finds that Wyeth has established that the minimum criteria for either MAR

---

[6] Dr. Lassetter's testimony during the eligibility hearing makes it clear that neither during the examination for mitral nor aortic regurgitation were the jets present during most or all of the cardiac cycle.

> Q. On Ms. Barrassi [sic], she's both mitral and aortic regurgitation as FDA positive in your affidavit; right?
> A. Yes, that is correct.
> Q. Let's talk about mitral regurgitation first.
> You repeat your language about mitral regurgitation only typically lasting throughout most or all of systole; right?
> A. Yes, I do.
> Q. And Ms. Barrassi [sic] didn't have late systolic mitral regurgitation that you say Weyman discusses; did she?
> A. I don't believe so, no, sir.
> Q. And she didn't have diastolic mitral regurgitation that you say Weyman discusses; did she?
> A. No, sir.
> Q. In fact, she only had early systolic mitral regurgitation; right?
> A. Early to mid.
> Q. But, let's talk about the aortic regurgitation.
> Now, you cite Page 8 as visualizing aortic regurgitation, the parasternal long axis view; right?
> A. Not the best, but it is present there, yes.
> Q. You actually cite that one; right?
> A. Yes, because it is present there. It's just not the best representation of it there.
> Q. There's no holodiastolic aortic regurgitation on that page; is there?
> MR. BLAIR: Can we put it up?
> A. I will submit that there is aortic regurgitant jet visualized in more than one frame in more than one time point in diastole, but this is a poor representation, but it is a representation of aortic regurgitation, but if you want to specifically state whether it's a best holosystolic demonstration of aortic regurgitation, it is not.

or MMR could not and have not been met based on this technically inadequate echocardiogram.

F. KATHY BARRON

Barron relies on an echocardiogram and report apparently both dated August 24, 2002 by Dr. Richard P. Brown. Dr. Brown found that Barron had MMAR using CAS criteria -- JH/LVOT = 27%. Dr. Brown commented that the quality of this echocardiogram was "good."

The August 24, 2002 echocardiogram was reviewed by three (3) experts: Dr. Chen, Dr. Saric and Dr. Lassetter. Drs. Saric and Chen concluded that both the low Nyquist limit and the high gain setting made this echocardiogram impossible to interpret. Dr. Saric observed that "[t]he Nyquist limit on this study was set at 41 cm/sec while color gains were often so high that color speckles filled almost the entire color box." Dr. Chen commented that "[t]he color Doppler gain is set too high and the Nyquist limit is set too low (41 cm/sec), making it impossible to make a reliable assessment of regurgitation." No efforts were made by either physician to conclude that regurgitation existed, let alone quantifying it.

Dr. Lassetter concluded that the echocardiogram was of adequate quality, excusing the 41 cm/sec Nyquist limit by opining that "Nyquist settings in the 40's are acceptable for Doppler interpretation." While he cited the Weyman and Feigenbaum Text for this proposition, no specific references were made and the Court finds these Texts do not support this assertion.[7]

---

[7] Dr. Lassetter acknowledged that he has never seen an echocardiogram with a Nyquist limit in the 30's that was interpretable.

> JUDGE WALSH: No, before we do that, Doctor, just tell me in your own words why the Nyquist limit of 41 is an acceptable setting where you're examining a patient in these circumstances?
> THE WITNESS: The intent of the Nyquist limit is to try and eliminate artifact.
> However, you have to take into consideration not only the depth but the density of the tissue through which the sound waves and the Doppler waves are traveling. And the lower the Nyquist limit can penetrate through denser and deeper tissue in order to demonstrate otherwise difficult to visualize regurgitant jet. Therefore, if the images of quality that you can see a regurgitant jet without other artifactual findings there, and you can confirm the jet by other modalities, the Nyquist limit in the 40s can be acceptable. That is where the visual interpretation of a physician, not merely just an image, can confirm or disprove the presence of regurgitation.
> JUDGE WALSH: How about the 30s?
> THE WITNESS: 30s?
> JUDGE WALSH: Yes, how about a Nyquist in the 30s?

The Court is satisfied that Wyeth has established that this echocardiogram was not performed in a technically adequate way and hence no reasonable medical conclusions could be drawn from it. The gain and Nyquist limits here distort and enlarge any pathology and artifact camouflages any possible pathology making any quantitative conclusions offered here medically unreasonable.

G. SHERRI BELL

Bell relies on an April 26, 2002 echocardiogram by Dr. Curtis S. Burnett. Dr. Burnett found that this echocardiogram "demonstrated trivial aortic insufficiency - AI jet was less than or equal to 18% of the left ventricular outflow tract jet [sic] height." While it appears that Dr. Burnett performed an analysis where the JH/LAA formula was used, it is impossible to conclude whether the CAS criteria were met because Dr. Burnett appeared to apply criteria different from those used by Singh. The worksheet prepared by the technician performing the echocardiogram indicates that she did use the JH/LVOT formula but no figures are readable from the Exhibit supplied.

The April 26, 2002 echocardiogram was reviewed by three (3) experts: Dr. Chen, Dr. Saric and Dr. Lazar. All three (3) experts concluded that the echocardiogram was conducted in a technically appropriate manner. Dr. Saric found that the "AI jet is not present in all recorded cardiac cycles. In those in which AI exists, the jet is very small ..." and was over-measured. Dr. Saric measured the jet and found it to be 4.6% by CAS criteria. Dr. Chen found trace aortic regurgitation and observed that "[t]he purported AI 'jet' is tiny and not continuous, or holodiastolic. Additionally, the JH was not measured just below the valve and measured beyond the jet edges." According to Dr. Chen, neither the JH nor LVOT were measured from proper angles. Dr. Chen measured the non-continuous jet and found it to be 6.7%.

Dr. Lazar concluded that Bell had MAR by CAS criteria measuring a JH of .38 and an LVOT of 2.1 or 18.1%. Dr. Lazar admitted the jet he identified was oddly shaped but decided that it was eccentric.[8]

THE WITNESS: I have never seen an echo that required a Nyquist limit in the 30s that was interpretable.
JUDGE WALSH: What's the difference between 41 and 39 from a clinical standpoint as a Nyquist?
THE WITNESS: I don't have an example to be able to answer that question.
JUDGE WALSH: All right.

[8] Dr. Lazar testified as follows in this regard:

JUDGE WALSH: Bell is an aortic regurgitation.

And the claim is approximately 18 percent when JH is measured against LVOT; correct, Doctor?

THE WITNESS: Yes.

JUDGE WALSH: Those are your measurements; you made them. The time stamp for the measurement is 1:24:00:12. So, let's cut to the chase.

1:24:00:12; and this is Sherri Bell.

[BY MR. BERN]: Q. This is 1:24:00, Doctor. Just tell us when.

THE WITNESS: Could we go up a little bit, advance just a little bit? Or -- you know what? Can we go back a little bit? I'm sorry.

JUDGE WALSH: We can do either.

MR. WHEELER: Your Honor, let the record reflect we're going frame by frame.

JUDGE WALSH: We are going frame by frame.

Is that like day by day.

MR. WHEELER: Somewhat close, your Honor.

THE WITNESS: I was -- sorry.

JUDGE WALSH: Go ahead.

THE WITNESS: I wasn't requesting to review the video frame by frame. I think we just needed to sync it to --

JUDGE WALSH: We're not sure where you need to sync it to. What counsel is doing, I think, is permissible, I suppose, which is saying the time going by on the tape, which is the actual official transcript -- although, I much trust our stenographer as to the tape.

And that's how they learn their craft, Doctor. It's like you calling out numbers on your echocardiograms. So, let's get to wherever we have to get.

Is this it?

THE WITNESS: Yes.

[BY MR. BERN]: Q. So, this is 1:24:00:13?

A. Yes.

Q. Would you just describe the jet that we're looking at, which you have diagnosed as FDA-positive regurgitation -- aortic.

A. Yes. That's a greenish jet right at the valve plane. You see the valve very clearly. It's a greenish jet. It's eccentric.

And, if I may, it's directed anteriorly. One could sort of wrestle with where to make the measurement. I would be very conservative and make it from here to about here, right at the valve plane. The outflow tract is well seen to be delineated between here and here.

JUDGE WALSH: Isn't this on [sic] odd jet for a situation where you would expect to see very high velocity backflow given the different gradients?

THE WITNESS: The answer is, you know, the shape of the jet is not the usual, but the fact that it's an eccentric jet, I think, accounts for that.

And eccentric jets could be very, very tricky, because you're seeing them in certain planes, and their shapes often look to be atypical, if you will.

I think, you know, one -- what I tend to do with these is -- you know, one can say, Gee, it's from this upper border to this lower border. And I think that's a gross overestimate.

I think a much tighter estimate would be right here -- and you see the valve plane -- to right over here, excluding that bit of purple that I'm seeing.

So, I think the way to -- the fact that it's eccentric doesn't negate the fact that it's aortic insufficiency. What I think it does, it leaves some obscurity as to the measurement.

And, again, my style is to try to cut the edges and measure it as conservatively as possible.

Dr. Chen, however, refutes Dr. Lazar's conclusion that this blob shaped phenomenon is an aortic jet:

> Q. Dr. Chen, on the third page of this report, what percentage of aortic regurgitation or what JH LVOT numbers does Dr. Lazar find?
> A. He found JH .38 and LVOT 2.1. That's basically the same.
> Q. The same? So that would also, under the settlement agreement, if correct, would be FDA-positive regurgitation?
> A. According to what he measured.
> Q. Have you reviewed this echocardiogram?
> A. Yes.
> Q. And based on your review of this echocardiogram, do you believe it's medically reasonable to diagnose this individual with FDA-positive aortic regurgitation?
> A. No.
> Q. Why not? Can you explain why?
> A. Because the jet that is shown on the frame, 12240012 is not aortic regurgitant jet.
> Q. Let's put that frame up and it's Defense Exhibit 3181 and we have it as graphic SV-1?
> JUDGE WALSH: Just so I understand it, you're telling us that the jet which was claimed to be a regurgitant jet is not? That's not, is that right?
> THE WITNESS: It's not a jet.
> Q. And this is a frame that Dr. Lazar and the originally [sic] echocardiogram pointed out, could you explain to the court why this is not an aortic regurgitant jet? And you can stand up if you want.
>
> * * * *
>
> THE WITNESS: As you can see here, this jet, and this, I would say, is the proposed jet. This color, you can see

---

JUDGE WALSH: I think you measured this at 18 percent, if my math is correct. I think it was 3 -- .38 and 2.1. So, when you do the math, it's 18 percent.

THE WITNESS: Yeah. I think roughly this would be just a little less than 1/5. But I think it is not, you know, over 1/3.

just orientation is this aortic valve here is ascending aorta and is the sinus or aortic root.
MR. AGNESHWAR: Can you say that a little slower for the court reporter?
A. You can see in the aortic valve probably here, but not very clear so usually aortic valve is inserted into aortic annulus, this here, and you can see part of this color is just laid over the aortic valve, but more importantly, it's not a jet, as I mentioned before. The regurgitant jet has a teardrop appearance, and this jet, this jet I don't know how to describe it. I can call it ill-shaped.
JUDGE WALSH: Looks like a blob.
THE WITNESS: A blob. We usually describe it as ill-shaped. Ill, I-L-L, so it's basically an amorphous [sic] shape. I would not believe it as a jet, and you can see in real-time, probably we'll get some better idea.
JUDGE WALSH: I guess what you're saying, if I get the drift, is no aortic jet basically comes out like a blob. They, basically, start and splay out as the jet is being driven by pressure in the aorta.
A. Exactly.
JUDGE WALSH: Back into the left ventricle.

* * * *

A. They either go to central, through the center of LVOT, left ventricular outflow tract, or sometimes jet infringes on the valve, but it still goes down to LVOT or left ventricular cavity.
JUDGE WALSH: In other words, it can either be central through the left ventricle or it can be eccentric [sic], meaning it bends up, but at its inception, it's arrow shaped.
THE WITNESS: Right, yeah.
JUDGE WALSH: I get the picture.

The Court has reviewed the echocardiogram and the testimony of Drs. Lazar and Chen. It finds that no reasonable cardiologist could conclude that the phenomenon identified by Dr. Lazar was an aortic regurgitant jet. Drs. Saric and Chen did identify small non-continuous aortic jets but both concluded that no medically reasonable echocardiologist could find these jets satisfy the CAS criteria for MAR. Consequently, the Court concludes that Wyeth has satisfied its burden

of showing that it is not medically reasonable to find that Bell has MAR based on this echocardiogram.

H. KAREN BENSON

Benson relies on an August 15, 2002 echocardiogram and report of Dr. Arthur Schwartzbard. Dr. Schwartzbard reported that Benson had MAR but no measurements satisfying CAS criteria were provided. Dr. Schwartzbard found Benson had MMR using the CAS criteria -- RJA of 4 cm^2; LAA of 18 cm^2. The Court calculated this percentage as 21.3%. Dr. Schwartzbard found the quality of the echocardiogram to be "good."

The August 15, 2002 echocardiogram was reviewed by three (3) experts: Dr. Goldman, Dr. Saric and Dr. Lassetter. Both Drs. Saric and Goldman found that this echocardiogram was not conducted in a technically adequate manner such that reliable medical conclusions could be drawn from it. Dr. Saric found that the Nyquist limit in the PLAX views was set at 41 cm/sec and the color gains were well outside the *ASE Standards*. As to the apical views and potential mitral regurgitation, Dr. Saric found the Nyquist limit of 51 cm/sec low but technically acceptable. Nevertheless, the "color gains were still too high." Dr. Goldman was equally critical, finding that in his experience "a Nyquist level of 41 cm/sec is not interpretable." Dr. Goldman also opined that to the extent anything could be gleaned from this echocardiogram "the purported mitral regurgitation appears to be backflow" and "no aortic regurgitation is visualized in the parasternal long axis view."

Dr. Lassetter, on the other hand, found Benson's echocardiogram "to be of diagnostic quality." Dr. Lassetter found Benson to have MMAR and MMR. In Dr. Lassetter's words:

> Mitral regurgitation is demonstrated in this echo ... as required by the Settlement Agreement protocol including the apical 4 and apical 2 chamber views. This is demonstrated in real time as well as in still planimetered frames and occurs during systole as specified by Singh. The settings were appropriate and the study was of diagnostic quality. The flow is both blue and yellow and mosaic in color as allowed by Singh. The mosaic color of the jet indicates its velocity is beyond what could be described as backflow. Given the velocity, location,

> duration and presence of the regurgitant jet during systole, this cannot be backflow which is defined by Weyman as blood pool immediately behind the valve of short duration and low velocity due to closure of the mitral leaflets....
>
> The aortic regurgitation on the echocardiogram was visualized in the parasternal long axis view and also in the apical 5 chamber view [an unapproved view]. The AR jet was in diastole close to the origin of the valve, tracking backward into the left ventricle. The jet was red and yellow and mosaic in color. The jet color, location, and timing of this jet is consistent with the criteria for aortic regurgitation as stated in the Singh article: "AR was considered to be present if red, yellow or mosaic signals (blue in the parasternal long axis) were seen originating from the aortic valve and spreading into the left ventricle during diastole." (Singh at 898-899). Utilizing software available to me that allows planimetry off-line, I measured the JH at .79 cm and the LVOT diameter at 2.13 cm. Utilizing the JH/LVOT formula required for quantifying these echos, I determined the percentage to be 37%. This measurement would place Ms. Benson's aortic regurgitation in the moderate range.

The Court finds Wyeth has established that no medically reasonable judgments as to the extent of Benson's valvular disease could be made from this grossly inadequate echocardiogram. The Court rejects Dr. Lassetter's unsupported conclusions that there are essentially no technical standards governing the conduct of echocardiograms and that their interpretation always is a matter of medical judgment.[9]

---

[9] In this regard, Dr. Lassetter's opinion, in the Court's view, is both clearly stated and clearly wrong.

> Q. Now, you are aware that the 2003 AFC Guidelines suggests Nyquist settings of 50 to 60; are you not?
> A. Yes.
> Q. Does the Nyquist setting in the 40s always render echocardiograms uninterpretable?
> A. No.
> Q. Is the Nyquist settings something that should be particularized to each patient?
> A. Yes.

I. ALFRED S. BLANCHARD

Blanchard relies on an echocardiogram dated August 1, 2002 and two (2) reports. One report is by Dr. Charles F. Dahl. Dr. Dahl found that Blanchard had MAR using the CAS criteria -- JH/LVOT = 15%. No comments were made about the quality of the echocardiogram. The second report is by Dr. Dale R. Stemple. Dr. Stemple found Blanchard to have MMAR although from the report it is impossible to determine whether CAS criteria were used.

The August 1, 2002 echocardiogram was reviewed by three (3) experts: Dr. Goldman, Dr. Saric and Dr. Lassetter. Both Drs. Saric and Goldman found the technical quality of this echocardiogram to be troubling. Dr. Saric reported that "[t]hroughout the study, color gains were set too high and ... [during portions of the study the] Nyquist limit was set to 46 cm/sec." Dr. Goldman found that the study was poorly done and "[t]he Nyquist limit varied between 46 cm/sec and 51 cm/sec in the parasternal long axis view. Additionally, the color Doppler gain was excessive. A low Nyquist setting can produce artifacts that can then be misinterpreted as regurgitation. In my experience, a Nyquist level of 46 cm/sec is not interpretable." As to the question of whether Blanchard had MAR, Dr. Saric found the "[e]ven with such high color gain setting, I could not unequivocally identify a sustained AI jet in many cardiac cycles." Dr. Goldman also dismissed the MAR claims, finding that "[n]o aortic regurgitation is visualized in the parasternal long axis view."

Dr. Lassetter concluded otherwise. He found Blanchard's echocardiogram "to be of diagnostic quality with appropriate settings for interpretation." Dr. Lassetter determined Blanchard's "percentage to be 30% using a JH of 0.61 and an LVOT of 2.01 which would place Mr. Blanchard's aortic regurgitation in the moderate range according to Singh criteria."

Dr. Lassetter's conclusion, however, is based on only one (1) loop and three (3) still frames that do not come from this loop.[10] While he claimed that MMAR is present, he conceded that the jet is not holodiastolic. Dr. Lassetter explains, but without any support, that this is actually an eccentric jet which is lost on the echocardiogram because of the limitations of color Doppler mapping:

Q. Is it sound medical practice to disregard as non-diagnostic all images retained with Nyquist in the 40s?
A. No.

[10] Dr. Lassetter incorrectly identifies the August 1, 2002 echocardiogram as taken on July 10, 2002.

MR. MICHAEL: Let's put up Page 27 ... of Defense Exhibit 3097.

* * * *

Okay, Doctor, where is the valve, the aortic valve on that frame -- on that loop?

A. The aortic valve appears to be in the middle of the triangle.

Q. And there's not a holodiastolic aortic regurgitant jet present in this loop, is there?

A. I actually believe that there is a holodiastolic jet there, but, again, the cardiac cycle moves that heart in and out of that plane. And you can connect the dots and see representations of that in frames that continue throughout diastole. It is an eccentrically directed jet towards the anterior mitral valve leaflet, but originating from the center of the aortic valve.

Q. I stated that poorly, Doctor.

There's not color flow Doppler images of an aortic regurgitant jet throughout most or all of diastole; is there?

A. It is not in every single frame, but it is in frames that are consec -- not necessarily consecutive and continuous, but are -- how do I say this -- mostly represented throughout diastole there.

Dr. Goldman's testimony and review of the echocardiogram demonstrates that Dr. Lassetter's contentions in his affidavit are not medically reasonable.

Q. Turning to Mr. Blanchard.

A. Yes, sir.

Q. Aortic regurgitation case?

A. Yes, sir.

Q. And did you agree --

A. No, sir

Q. Did you believe that Dr. Stemple-Dahl's or Dr. Lassetter's opinion of FDA-positive aortic were medically reasonable?

A. No, sir.

Q. And let's put up -- this is Page 27 of ... Defendant's Exhibit 3097. And Doctor, this is seen in the parasternal long axis view of the echocardiogram. And I'd like you

to walk us through it and see if there's a sustained aortic regurgitant jet on there.

A. Again, the gain is extremely high. You're a borderline Nyquist limit.

* * * *

Go forward. Again, you get this big blast of color, can't see anything.

Next. Again, blast of color.

Next, please. Next, please. Next, please. And in this, again, nothing behind the valve. This is still diastole, so no turbulent flow behind the valve.

Next please. Again, next. Next, please. Tiny jet.

Next, please. Again, nothing.

Next, please. Next, please. Next. Again, nothing. Nothing. Next. Nothing. Nothing. Nothing. Next. Next. Systole.

So for the majority of the cycle, there wasn't anything seen in diastole.

Q. So not medically reasonable to say that that's an aortic regurgitant jet?

A. No aortic regurgitation was present.

In the Court's view, Wyeth has established that Blanchard's echocardiogram was not performed in a technically adequate manner and no reliable medical conclusions can be drawn from its review. This is particularly important here when the phenomenon which Dr. Lassetter identifies as a jet fades in and out of the echocardiogram when played in real time and frame by frame. The question of whether the jet identified by Dr. Lassetter is real or artifact simply cannot be reliably addressed with this poorly performed echocardiogram. In short, no medically reasonable conclusions can be drawn from this echocardiogram.

J. LEANDRA BLOCK

Block relies on a December 4, 2002 echocardiogram and report of Dr. Stanley S. Schrem. Dr. Schrem found that Block had MMR using CAS criteria -- RJA/LAA = 31%. Dr. Schrem found that the study quality was "fair."

The December 4, 2002 echocardiogram was reviewed by three (3) experts: Dr. Goldman, Dr. Saric and Dr. Lassetter. Both Drs. Saric and Goldman found that the echocardiogram was not conducted in a technically adequate manner such

that reliable conclusions regarding the presence and severity of valvular regurgitation could be drawn from it. Dr. Saric observed that the "Nyquist limit on this study was set at 46 cm/sec in all relevant apical views while color gains were often so high that color speckles filled almost the entire color box." Dr. Goldman concurred and observed that "[t]he Nyquist limit was set too low (46 cm/sec) in the apical views and the color Doppler gain was set too high to make a reliable assessment of regurgitation, if any. Only one image (frame 8) had a Nyquist limit of 51 cm/sec, yet the color Doppler gain was still very high."

Dr. Lassetter concludes otherwise. In his view, Block's echocardiogram was "of diagnostic quality with appropriate settings for interpretation." Dr. Lassetter found MMR based on an RJA/LAA of 34%.

All three (3) experts have testified that high color gains and low Nyquist limits tend to increase the perceived size of any jet. This is particularly true in the apical view where the transducer is almost parallel to the red blood cells. The Court finds that any conclusions as to whether Block has mitral regurgitation, and its degree, cannot be reasonably based on this technically flawed echocardiogram.

The Court finds that Wyeth has established that Block's echocardiogram was performed in such a technically inadequate way that no reliable conclusions can be made. The gain settings and Nyquist limits make the isolation of a regurgitant jet from artifact no more than guesswork.

K. HERB BOER

Boer relies on a July 26, 2002 echocardiogram and report by Dr. Hossein Amirani. Dr. Amirani found that Boer had MAR using CAS criteria -- JH/LVOT = 15%. Dr. Amirani noted that this was a "[t]echnically difficult two-dimensional echocardiogram with poor quality images obtained."

The July 26, 2002 echocardiogram was reviewed by three (3) experts: Dr. Kaul, Dr. Saric and Dr. Lassetter. Both Drs. Saric and Kaul concluded that the echocardiogram was not conducted in a technically adequate manner such that reliable medical conclusions regarding the presence and severity of valvular regurgitation could be drawn. Dr. Saric found that the "Nyquist limit in this study was set at 45 cm/sec in both PLAX and apical long-axis views while color gains were high throughout the study." Dr. Kaul found that "[t]he Nyquist limit is 45 cm/sec on this echocardiogram, which is unreasonably low. The low Nyquist limit makes this echocardiogram technically inadequate because low velocity flow will

appear turbulent and jet size will be overestimated." Dr. Saric did not attempt any analysis based on his conclusions that the echocardiogram lacked reliability. Dr. Kaul did observe that "[e]ven with the low Nyquist limit, the aortic regurgitation does not appear FDA positive."

Dr. Lassetter reached a different conclusion. He found the echocardiogram "to be of diagnostic quality with appropriate settings for interpretation." Dr. Lassetter found Boer had MMAR with an JH/LVOT = 29% -- almost twice that found by Dr. Amirani. In the Court's view, Dr. Lassetter's conclusions lack credibility.

The Court finds that Wyeth has established that Boer's echocardiogram is so technically deficient that no reasonable medical conclusions can be drawn from its analysis.

L. MARGARET BORDIERI

Bordieri relies on an October 17, 2002 echocardiogram and report by Dr. Stanley S. Schrem. Dr. Schrem found Bordieri had MAR using CAS criteria -- JH/LVOT = 18%. Dr. Schrem failed to find MMR. Dr. Schrem observed that the study quality was "fair."[11]

The October 17, 2002 echocardiogram was reviewed by three (3) experts: Dr. Chen, Dr. Saric and Dr. Lassetter. Both Drs. Saric and Chen found the echocardiogram was technically inadequate for the purposes of assessing the level of aortic regurgitation. Dr. Saric observed that while the Nyquist limit was appropriately set, the "color gains were high throughout the study." As such, Dr. Saric declined to attempt measuring any purported jet because "[n]o reliable measurements of JH can be obtained with high color gain settings. When the color gain is set to [sic] high, the apparent size of JH increases making AI appear worse than it truly is." Dr. Chen concurred and declined to attempt a measurement of JH "[b]ecause the color Doppler gain was set to [sic] high." Thus, "it is not possible to make reliable accurate measurements on this study."

Dr. Lassetter found Bordieri's study "to be of diagnostic quality with appropriate settings for interpretation." He concluded that Bordieri had MMAR and, in his affidavit, purported to reach that conclusion as follows:

[11] While it was initially claimed that Bordieri had MMR, that claim was withdrawn during the Eligibility Hearings.

> The Weyman textbook requires that the cardiologist take the maximum observed jet size when quantifying regurgitation: "the maximum jet area occurring at any point during systole is taken as the representative value." "The largest recorded area should be used regardless of the plane in which it was recorded." (Weyman at 436) I re-reviewed the echocardiogram and the tracings made by the sonographer for purposes of this affidavit. Taking into consideration the principles stated above in Weyman and Feigenbaum, it is my opinion that the tracing of the aortic jet demonstrates moderate aortic regurgitation.

This is a complete misunderstanding of the teachings in the Weyman Text. These teachings clearly apply to the measurements of mitral regurgitant jets. They are area measurements. Of course, the JH/LVOT ratio relevant to aortic jets is based on linear measurements. On that basis alone, the Court could conclude that Dr. Lassetter has no credible information to offer on this case. But the Court will not do so.

Instead, the Court finds that Wyeth has established this echocardiogram was performed in such a technically deficient manner that no reasonable medical conclusions can be drawn as to the presence or amount of aortic regurgitation.

M. MARY BRAUN

Braun relies on a November 21, 2002 echocardiogram and report by Dr. Stanley S. Schrem. Dr. Schrem found Braun had MAR and severe mitral regurgitation ("SMR") using the CAS criteria -- JH/LVOT = 17%; RJA/LAA = 48%. Dr. Schrem observed that the study quality was "fair."

The November 21, 2002 echocardiogram was reviewed by three (3) experts: Dr. Chen, Dr. Sherrid and Dr. Lassetter. Dr. Chen believed the echocardiogram was not conducted in a technically adequate manner such that reliable medical conclusions could be drawn. Dr. Sherrid apparently agreed that the "aliasing velocity," i.e., Nyquist limit, was set "too low" for any reliable conclusion to be made as to the claim of MAR but concluded, in spite of the low aliasing velocity in the apical views, that "[a]ll considered though, [there was] mild to moderate mitral regurgitation." He performed a RJA/LAA ratio and found MMR of 37.4%.

Dr. Lassetter, on the other hand, supported both the MAR and MMR as to Braun observing the echocardiogram "to be of diagnostic quality with adequate settings for interpretation." As to the MMR claim, Dr. Lassetter found a representative RJA to be 8.8 cm^2 and LAA to be 22 cm^2 yielding 39% -- clearly an MMR. He also concluded that Braun had MAR with a JH/LVOT of 18%.

The Court has already observed that the technical quality of an echocardiogram is essential to obtaining reliable and reproducible results. *Kemp ex rel Wright v. State*, 174 N.J. 412, 427 (2002); *Oddi v. Ford Motor Co.*, 145 F.3d 136, 145-146 (3rd Cir. 2000); *In re Paoli Railroad Yard PCB Litigation*, 35 F.3d 717 (3rd Cir. 1994). The Braun echocardiogram, in the Court's view, fails this gatekeeping test. Dr. Sherrid may conclude that in his clinical judgment "mild to moderate" mitral regurgitation exists here but this is his clinical judgment in the face of a technically inadequate echocardiogram.[12] Dr. Lassetter's views on

[12] Dr. Sherrid recognized the serious limitations of the echocardiogram as is apparent in his testimony during the Eligibility Hearing.

> [JUDGE WALSH:] And can you tell us whether there was a mitral or aortic regurgitation claim made [as to Mary Braun] --
> THE WITNESS: There was a claim of both.
> JUDGE WALSH: And if so what were your findings with respect --
> THE WITNESS: My findings the aliasing velocity was low in this particular case and that tempers any remarks that I might make about this echocardiogram, but all things considered and looking at this particular patient, I thought she had mild to moderate mitral regurgitation. I thought she a [sic] thickened anterior mitral valve leaflet.
> JUDGE WALSH: Well, as you know, Doctor, there's [a] difference between our perspective between mild and moderate. Moderate qualifies. Mild doesn't.
> THE WITNESS: So, this is over mild. This is more than mild.
> JUDGE WALSH: Well, are you saying that a reasonable person -- a reasonable physician in your situation could conclude that -- that this Ms. Braun had mitral regurgitation meeting FDA criteria?
> THE WITNESS: Yes, this meets FDA criteria.
> JUDGE WALSH: All right.
> How about the aortic regurgitation?
> THE WITNESS: No, it doesn't.
> JUDGE WALSH: Why doesn't it?
> THE WITNESS: It was trivial.
> JUDGE WALSH: All right. You find the aortic regurgitation was trivial?
> What methodology did you follow to make that conclusion?
> THE WITNESS: By inspection.
> JUDGE WALSH: All right. You inspected the media that were produced.
> THE WITNESS: Correct.
> JUDGE WALSH: Let's go on to -- any other comments you want to make on Ms. Braun?
> THE WITNESS: No other comments.
> * * * *
> [BY MR. BERN]: Q. I want to thank you for making measurements on many of my cases. The first one I want to talk about is Ms. Braun.

Nyquist limits and high gain are clear and, as already noted in this Letter Opinion, have been rejected by this Court.

In sum, the Court concludes that Wyeth has established that Braun's echocardiogram was of such poor technical quality that no medically reasonable conclusions can be drawn from its use.

N. SUSAN BUREK

Burek relies on a May 10, 2002 echocardiogram performed by Associates in Cardiology, Ltd. and a report of Dr. Neal Ruggie. Dr. Ruggie found Burek had MMAR using CAS criteria -- JH/LVOT = 29%.

The May 10, 2002 echocardiogram was reviewed by three (3) experts: Dr. Chen, Dr. Sherrid and Dr. Lazar. All three (3) physicians found Burek's echocardiogram to have been performed in a technically adequate manner. Dr. Sherrid found minimal aortic pathology based on his review of the echocardiogram. He found "barely trivial aortic regurgitation in the PLAX view" and "trivial aortic regurgitation in the apical long axis view." Dr. Chen concurred with Dr. Sherrid's findings, observing that:

Dr. Sherrid, with respect to Ms. Mary Braun, I believe you agreed that it would be medically reasonable to make a diagnosis of moderate mitral regurgitation. Do you see that?
A. Yes.
Q. But you disagreed that it would be medically reasonable to make a diagnosis of at least mild aortic regurgitation. Do you see that in your report?
A. That's what I said, yes.
Q. You're not saying that Ms. Braun does not have aortic regurgitation; right?
A. I'm saying really the overall qualifications about my judgment and my thoughts about this particular echocardiogram has to do with the fact that the aliasing velocity was performed too low.
Q. And so that was the basis for your opinion that -- the low aliasing velocity was the basis for your opinion that non-FDA positive aortic regurgitation was demonstrated; is that fair?
A. No, I think really that -- look, what I said here about the aortic regurgitation was that I really couldn't be sure one way or another.
Q. Well, I'm looking at the section of your report regarding aortic regurgitation.
A. Aliasing velocity is too low.
Q. And your comment was the aliasing velocity was too low. And actually that's the only comment with respect to why no FDA positive aortic regurgitation was demonstrated in your report; correct?
A. Right.

> Although the parasternal long axis view was available, the sonographer measured the purported AI in the apical view. Additionally, the JH was not measure[d] just below the valve and beyond the jet edges. The JH was not measured from a proper angle. The LVOT was not measured from a proper angle. There is a tiny jet (less than 10%) of aortic regurgitation visualized but it is intermittent throughout diastole.

Dr. Chen found the aortic jet "too tiny to measure."

Dr. Lazar concluded that an apical long axis view disclosed a MAR of 15%. He acknowledged that the PLAX view was available but that the color was not turned on. The PLAX view is the preferred view for present purposes for a good reason -- the apical view tends to make the aortic jet appear larger than it actually is. As noted by Dr. Goldman at another point in this Eligibility Hearing:

> [JUDGE WALSH:] I mean, do I understand this correctly, Doctor? In the apical view, the [aortic] jet is more pronounced.
> THE WITNESS: We're talking about the aortic regurgitation insufficiency?
> JUDGE WALSH: Yes.
> THE WITNESS: Right.
> JUDGE WALSH: And that's why generally it's not the preferred view.
> THE WITNESS: Exactly.
> JUDGE WALSH: Okay. I got it.
> THE WITNESS: Hundred percent.

No explanation is given by plaintiffs as to why the PLAX view was unavailable on Dr. Lazar's copy of the echocardiogram.[13] The independent

[13] Dr. Lazar claims that the color Doppler was not used on the media provided to him.

> Q. And, as I understand it, on the digital format that you reviewed, the color Doppler was not used in the parasternal long axis?
> A. Yes.
> Q. And so, you were able to determine the AI being present where?
> A. In the apical 3 chamber view.
> Q. And that would be at 1:37:22, pursuant to your October 5, 2004 certification?
> A. Yes, sir.

expert's and Dr. Chen's copies of the echocardiogram had color in the PLAX views. For purposes of this hearing, the Court finds that under these facts, the PLAX view cannot be regarded as "unavailable." After all, both Drs. Chen and Sherrid only observed a tiny color jet in that PLAX view.

The Court concludes that Wyeth has established that this echocardiogram discloses a P LAX view was available and should have been used. In any case, the Court concludes that even if Dr. Lazar's opinion is considered, his measurement of the jet in the apical is not medically reasonable because there was no clearly delineated jet noted in the frame claimed to disclose the MAR.[14]

---

[14] As Dr. Chen reports, the phenomenon plainly is not an aortic jet.

> Q. Let's go right to Defense Exhibit 3184 which is SEU-3, which is the frame from which the measurement was taken and this is an aortic – a purported aortic regurgitation case.
>
> Dr. Chen, what view are we looking at here?
>
> A. This is apical, probably three chamber view.
>
> Q. It's the apical three chamber view?
>
> A. Yes, you can see the left ventricle, this is zoomed -- it was a zoomed sector and therefore, you only see a total heart and you can see the part of left ventricle here and probably the left atrium, mitral valve, left ventricle outflow tract and the aorta valve, ascending aorta.
>
> JUDGE WALSH: Your first observation was although the parasternal long axis view is available, it wasn't used?
>
> MR. AGNESHWAR: That's correct.
>
> JUDGE WALSH: And you find fault with that?
>
> MR. AGNESHWAR: That's correct.
>
> JUDGE WALSH: Which I think in at least one instance, I disqualified the person even though the apical view arguably supported, according to Dr. Weiss, a finding.
>
> MR. AGNESHWAR: That's correct. Even putting that aside Dr. Chen, just to make my record, is this an aortic regurgitant jet?
>
> A. I don't think so.
>
> Q. I'm sorry?
>
> A. No, no.
>
> Q. Why not?
>
> A. It's probably part of jet that we see here, but not really aortic jet you will see. First, you see this red color? This doesn't have anything that look like laminar flow, low velocity, and you have like here yellow dots, but you don't see any blue. You don't see any aliasing. So this is apical three chamber view, remember.
>
> JUDGE WALSH: The blood is apparently flowing toward the transducer?
>
> THE WITNESS: Uh-huh, it's red, but the velocity not very high, therefore, it's red. And as the velocity go higher, you get some blue -- some yellow, but never any --
>
> JUDGE WALSH: There is no wrapping around?
>
> THE WITNESS: No, velocity never go beyond the Nyquist limit.
>
> So aortic regurgitation jet, in apical view, the jet direction are parallel to the ultrasound beam therefore --
>
> MR. AGNESHWAR: Perpendicular to?

O. TERRI BURGESS-BRYANT

Burgess-Bryant relies on a June 17, 2002 echocardiogram from South Denver Scanning Services and report by Dr. Michael E. Staab. Dr. Staab found that Burgess-Bryant had MAR using CAS criteria -- JH/LVOT = 18%. Dr. Staab noted that "the test quality is fair."

The June 17, 2002 echocardiogram was reviewed by three (3) experts: Dr. Chen, Dr. Sherrid and Dr. Lazar. All three (3) physicians concluded that the echocardiogram was technically adequate although Dr. Sherrid noted "reproduction awful." Dr. Sherrid found there to be "trivial aortic regurgitation" which "is tiny as it emerges from a pinhole orifice." Dr. Chen concurred and made the following observations:

> No clearly delineated AR jet is visible in the parasternal long axis view in real-time images. In one cardiac cycle there may be a tiny AI jet, but it does not re-appear and cannot be selected from real-time for measurement. Furthermore, the measurements originally made on the study were improper: the measurements were all beyond the "jet" edges, some of the measurements were made in improper locations, such as before the valve, and from improper angles.

Dr. Lazar found that Burgess-Bryant had MAR, observing a JH of .3 and a LVOT of 2 cm or 15%. But Dr. Chen noted that at least one of the measurements made by Dr. Lazar was of a frame of the pulmonic valve. Dr. Chen also looked at pulsed wave and continuous wave Doppler in an effort to confirm any measurable aortic regurgitation and could not do so. The cross-examination of Dr. Lazar, which is set out in the footnote in its entirety,[15] convinces the Court that no

---

A. No, parallel to the ultrasound beam, and therefore, the jet velocity should be recorded accurately or at least a little bit off angle, but it would not be too much.

So normally, aortic regurgitant jet velocity should be more than 4 meters per second.

JUDGE WALSH: And you're saying that this blood plainly is flowing within the Nyquist limit?

THE WITNESS: Yeah.

[15] The cross-examination of Dr. Lazar follows:

Q. Doctor, let's turn our attention, if we might, to the next patient, Ms. Burgess-Bryant.

I believe you told us yesterday that your opinion is that Ms. Burgess-Bryant suffers from mild aortic insufficiency based upon your review of the June 2002 echocardiogram; correct?
A. I said there was AI present on the echo.
Q. Is there a distinction in her suffering from that as opposed to being present on the echo?
A. I don't -- I haven't seen her.
Q. Fair enough.
You've stamped or time stamped on your report --
MR. WHEELER: Your Honor, Exhibit D-3005, Sub Exhibit G.
Q. -- that the time measures that you utilized to reach your conclusion were at 36:30 and then 37:15; correct?
A. Those were two representative views.
Q. And I believe, Doctor, if my notes are accurate, that we -- yesterday during the course of your direct examination, went frame by frame through images at or about that time marker and found those that you actually relied upon; correct?
A. Correct.
MR. WHEELER: Let's look then if we might in a real-time image, TJ, at 37:14:10.
Q. Which I believe, Doctor, one of the time stamps you actually measured for us yesterday.

* * * *

Q. Is this the image we looked at together yesterday, Doctor?
A. I don't recall.
Q. All right. Let's go back a few frames and see if you can identify the jet that we discussed yesterday. That's good, right there.
That's systole, isn't it?
A. Oh, we're in systole.
Q. Go forward a frame, please, another, another.
Are we in diastole yet, Doctor?
A. I don't believe so.
Q. Go forward, go forward.
A. We're in diastole.
Q. Do you see a jet present?
MR. WHEELER: And, for the record, this is 37:14:13?
MR. LOEBBAKA: Yes.
A. I do see a jet.
Q. You do see a jet here?
Doctor, you're going to have to help me. I'm a little fatigued as well. Where is that jet?
A. It's the white, not the purple.
JUDGE WALSH: That little white dot that's surrounded by the purple. Okay.
Q. Do you believe that to be a true regurgitant jet, Dr. Lazar?
A. Well, let's play it some more.
Q. Okay. Go forward.
It's gone; isn't it, Doctor?
A. Yes.
Q. Was that true regurgitation on the previous frame?
A. No.
Q. Go forward. Next, next, next, next.
Doctor, do you see any jets in this diastolic loop that you identified for us yesterday?
A. I don't.
Q. Go forward. Next, next, next. Let me know when we're finished with diastole, next, next, next.

Doctor, we're now passed 37:15 which was a time marker you had in your report. Did you see a jet as we went through approximately 10 to 11 frames diastole there?

A. I didn't see it.

Q. Let's then turn our attention to the other reference that you gave us 36:30, and I believe the exact time marker, your Honor, for the record you told us about yesterday was 36:30:03.

Doctor, is this a jet you identified for us yesterday?

A. It's part of it.

Q. Did you see that on other frames and diastole in this particular cycle?

A. Yes.

MR. WHEELER: Back it up one from TJ, back.

Q. Tell me when we get to the first part of diastole. That's systole; isn't it Doctor? It's not over the T wave?

A. Where are we looking?

Q. I'm looking at this EKG script. This particular cursor is right over the QRS complex and is not yet completed the T. Am I looking correctly?

A. Are you --

JUDGE WALSH: Let's make sure we all know which cursor we're talking about.

MR. WHEELER: Put back on the image that he talks about 36:30 --

THE WITNESS: Are we talking about this marker?

Q. Are we back on 03?

A. Yes.

Q. What phase of the heart are we in now, Doctor? That would be in diastole; correct?

A. Correct.

Q. Go forward one. Do you still believe a jet is present?

A. Yes.

Q. Forward. You believe that's a regurgitant jet?

A. Yes.

JUDGE WALSH: That being that little light right before the blue surrounded by a red in the middle of left end of the --

THE WITNESS: Yes, not the purple.

JUDGE WALSH: -- the red and the yellow and white?

THE WITNESS: The orange yellowish, the mosaic.

Q. Go forward. Do you still believe it's present, Doctor?

A. Yes.

Q. Forward.

A. Yes.

Q. Forward.

A. Yes.

Q. Forward. That's frozen, I believe Doctor; isn't it? Going back and forth between the same image, I didn't see the EKG strip move at all, but you're the witness not I.

A. Actually, it moved. It was frozen for part of it, but it did move.

Q. Do you believe, Doctor, based upon review of this particular study that that image is a turbulent jet based upon the color map that's present there?

A. Yes.

Q. We looked at an image a moment ago -- let's see if we can go back quickly, your Honor, to TB.23. This is 37:15, we looked at a moment ago?

Is that a PLAX view, Doctor?

A. Yes, it's a very difficult view. I wouldn't put much stock in this view.

Q. Isn't that really a view of the try can you pulled valve a tricuspid view?

A. I was about to say it's an oblique view. I'm not sure what it is.

reasonable cardiologist could conclude from a review of the echocardiogram that Burgess-Bryant has MAR using CAS criteria.

For these reasons then, the Court finds that Wyeth has sustained its burden and has demonstrated that no reasonable cardiologist could conclude that Burgess-Bryant's echocardiogram demonstrates MAR using CAS criteria based on this echocardiogram.

P. TROY BURKS

Burks relies on a May 25, 2002 echocardiogram performed by Cardiac Consultants of Chicago, Ltd. and a report by Dr. Richard Levinsky. Dr. Levinsky found Burks had MAR using CAS criteria -- JH/LVOT = 25%.

The May 25, 2002 echocardiogram was reviewed by three (3) experts: Dr. Chen, Dr. Sherrid and Dr. H. Cohen. All three (3) physicians found the echocardiogram to be of diagnostic quality. Both Drs. Sherrid and Chen found essentially no aortic regurgitation. Dr. Sherrid observed "[n]o aortic regurgitation of any significance." Dr. Chen was more emphatic:

> In real time, no aortic regurgitation is visualized on this echocardiogram. Additionally, the original qualifying echo report by Dr. Richard Levinsky relies on two frames to show aortic regurgitation at 0:57:07:29 and 0:59:49:04. The first frame (0:57:07:29) is measured in early *systole*, and the second frame (0:59:49:04) depicts only color artifact, and not true regurgitation. (Emphasis added.)

Dr. H. Cohen concluded that Burks had MAR with the JH/LVOT = 25%. Virtually no other information was provided in his Affidavit or direct testimony as to the basis of his own measurements. In fact, it appears that Dr. H. Cohen could not tell whether he measured the alleged aortic regurgitant jets in October 2004 or whether he simply relied on the report by Dr. Levinsky. What is clear is the

---

Q. And that's the images we went through a moment ago; correct?
A. Those are the first images on this patient you asked me to look at it.
Q. Yes, sir, and those are the ones we discussed yesterday in your direct testimony?
A. Much of the testimony was on the second set of images, which we just did prior to this, not on this.
MR. WHEELER: For the record, we looked at 37:14:10 through 37:14:13.

original technician's worksheet was destroyed. Dr. H. Cohen did disagree with Dr. Chen that one of Dr. Levinsky's measurements was made in systole.

The Court reviewed the entire cross-examination of Dr. H. Cohen which is set forth in the footnote[16] and finds his testimony is a "net opinion" and thus entitled to little or no weight. *See Buckelew v. Grossbard*, 87 N.J. 512 (1981).

---

[16] The cross-examination of Dr. H. Cohen follows:

Q. On Troy Burks' Question 9 where it says, Did you conduct measurements on the echocardiogram, and you checked yes, that should have been a no, is that right?

A. Well, that -- I assumed that it meant the original measurements, and I think I put that on all of them because I assumed that it was talking about our original measurements, and I wrote on as many of them as I remembered that I didn't have the work sheets, which would indicate that I didn't do it again.

Q. Okay. Doctor, were these forms filled out that you filled out on 10/10/2004, did you fill them out while rereviewing the echocardiogram?

A. Yes.

Q. And were the answers based on your rereview of the echocardiogram?

A. They were based -- the numbers were based on the original numbers because I had no way to measure.

Q. Okay. So --

A. And -- you know, and I was looking at the echo at the same time.

Q. So for example, on Troy Burks' Question 7 when the question was, Was a parasternal long axis view available on this echocardiogram, and you checked yes, you checked yes, based on your 2004 review of the echocardiogram, right?

A. I don't remember right now. I'm sorry. I don't remember. Because that was the one case that I thought we were not doing today, and I didn't review it last night, and so I have no recollection of what I saw when I filled this out.

Q. I'm not asking if that question was right, I'm asking you on 10/10/2004, when you filled out this sheet --

A. Yes.

Q. -- and you answered that question --

A. When I answered -- when I answered that question --

Q. -- was it based on your rereview of the echocardiogram?

A. It was based on either the rereview or the original.

Q. So you might have just not looked at the echocardiogram, you just --

A. No. I looked at -- no. I looked at the whole echocardiogram.

Q. Okay. And you did that in order to fill out this form, right?

A. Yes.

Q. Okay. And when it says, Did you conduct measurements on this echocardiogram --

A. Yes. Right.

Q. -- that was not talking about your review?

A. If I said -- if I said yes, it meant that I originally -- we -- the technician originally didn't. I had no way of making the measurements.

Q. So you --

A. And I assumed that's what the question meant.

Q. Okay.

A. Okay.

Q. All right. So in that one, you're talking about measurements made by the technician in 2002, right?

A. That's correct.

Having little information on how Dr. H. Cohen reached his medical conclusions, it is virtually impossible to judge how reasonable they are. Dr. Chen explained that the only frame which Dr. H. Cohen could possibly rely upon for his judgment that Burks has MAR was an aortic valve closing artifact. The phenomenon was transient and did not continue in the subsequent echocardiographic frames. The other frame relied upon by Dr. H. Cohen, according to Dr. Chen, was taken in the Apical 5 chamber view,[17] which is not a permitted view in the CAS and will be disregarded by the Court.

---

[17] Dr. Chen's testimony on these points was as follows:

JUDGE WALSH: Doctor, if I were to accept your testimony that this color cluster is not a regurgitant jet, just what is it?
THE WITNESS: It's, when I look in real-time, actually it's one frame that's associated with aortic valve closure, when aortic valve close, it's artifact. Like, if you recall in the spectral Doppler, when aortic valve closed you had this very long artifact, closing artifact. So sometimes if echo resolution not that good or color can appear on this artifact. So that's why it's clinically important if you see an AI, it should last for several frames, not just one frame.
JUDGE WALSH: Okay.
THE WITNESS: Also the shape is totally bazaar, too. Therefore, when you first look at this, you say probably not and then if you want to confirm it, then you need to go to the real-time frame.
Q. Let's go to the next slide. We're going to go to real-time in a second, but let's go to the next slide that we have.
THE WITNESS: So first you maybe have some doubt, and it doesn't look like AI jet, but if you go real-time, you can confirm that suspicion.
Q. Dr. Chen, this is the next frame that Dr. Cohen relied upon. What criticisms, if any, do you have of the selection of this frame?
A. This frame is apical -- a poor study first, very poor study quality, very poor and this is a frame that in apical five chamber view and you can see the left ventricle here, right ventricle here, right atrium here, left atrium here, and then you have left ventral outflow tract and therefore, it's called a five chamber view.
Q. So this is not the parasternal long axis view?
A. No.
Q. And it's not the apical long axis view?
A. No.
Q. But even, putting all that aside, do you have any criticisms of the identification of this thing as a jet?
A. There's no jet there.
Q. What is that?
A. This is a mitral inflow, diastolic mitral flow in, and you have color here, go towards the transducer as you can see in red.
JUDGE WALSH: Inflow?
THE WITNESS: Inflow.
JUDGE WALSH: Can you confirm that by looking at the electrical pattern?
THE WITNESS: You can, yeah, diastole, you can see here. But this left ventricle outflow tract here, there's nothing here. So there's no AI here.
Q. It's not AI there?
A. No.
Q. Let's go to real-time and this is FTI 6023 and it's Defense Exhibit 3317, which is what Dr. Chen selected --

In sum, the Court is satisfied that Wyeth has established that Dr. H. Cohen's conclusion that Burks has MAR is not medically reasonable.

Q. ULYSSES BURNS

Burns relies on a May 21, 2002 echocardiogram performed by Associates in Cardiology, Ltd. and a report by Dr. Roger A. Billhardt. Dr. Billhardt found Burns had MAR and MMR using CAS criteria -- JH/LVOT = 23%; RJA/LAA = 26%.

A. And Judge, if I can, you can see probably here in the depth somewhere, you see it's 20 millimeter depth, you see here in the transducer is 20 – each is five here; 5, 10, 15, 20, so we have Nyquist of 59, even with that big depth.
Q. Let's go to the real-time PLAX loop, which is FTI 6023 and it's Defense Exhibit 3317.
A. This is no aortic regurgitant jet. You can see one like these color dots or whatever artifact, it go direct with aortic valve closure and that's not only in one frame. Lasts normally in one frame, this color artifact.
Q. Why don't we go frame by frame and just see that?
A. Uh-huh. So you see aortic valve now it's closed? Okay. Go. Most cycles you don't see it, but you can see it in one cycle, one cardiac cycle.
Q. So in this cycle, do you see it at all?
A. No, I don't. Aortic valve close, nothing here. Mitral valve opens. Now, it start -- the mitral valve close, starts isovolumic contraction, but the ventricle starts to contract, but the aortic valve still not open. We call it isovolumic contraction.
Q. Now, tell us when we get to diastole.
A. Okay. Now, this is systole. Okay. Go. You can see the flow come out, aortic valve opens.
Q. Have we seen any AI yet?
A. Not yet, aortic valve still open, still open the aortic valve, aortic valve opens. Opens here. Probably, it's open a little more in systole. Aortic valve close. Nothing in here.
Q. Now, the aortic valve is closed and nothing there?
A. No.
Q. Anything there in the next frame?
A. No.
Q. Next frame, anything there?
A. No.
Q. Next frame?
A. It only appears in one short cardiac cycle and it's artifact, but most cycle you don't see it. Just keep playing.
Q. So we've gone through how many cardiac cycles right now?
A. In real-time, I've played cardiac cycle 10, 20 --
Q. And how many did you see the blob in?
A. One.
Q. One?
A. One or two. Now, it's another cycle go through, nothing there. Aortic valve closed. Now, aortic valve opens. Aortic valve opens, opens, opens, stop, still open, still open, still open. Now, close. This has one closing artifact here.
Q. Is that it? Let's go back. That's it?
A. That's it.

The May 21, 2002 echocardiogram was reviewed by three (3) experts: Dr. Chen, Dr. Sherrid and Dr. Billhardt. All three (3) physicians agreed that the echocardiogram was of diagnostic quality. Both Drs. Sherrid and Chen concluded that Burns' echocardiogram showed neither MAR nor MMR. According to Dr. Sherrid, some tracings suggesting MMR were made in the PLAX view, which is not an approved view for such measurements. Dr. Sherrid found that the apical views showed mitral regurgitation so trivial that it was not worth measuring. Dr. Chen essentially agreed with Dr. Sherrid, finding that one (1) of the three (3) measurements of purported mitral jets was made in the PLAX view while the other two (2) were made in the apical view. Dr. Chen did measure the mitral jets and found an RJA of 1.522 cm^2 and a LAA of 19.908 cm^2, yielding 7.65%. Drs. Sherrid and Chen also concurred that there was no MAR in the PLAX views. Both indicated that the purported MAR was measured in the apical view when the PLAX view was available.

Dr. Billhardt conceded that the JH/LAA was not measured in the PLAX view but suggested that such a measurement was not required.

> [DR. BILLHARDT:] Question 7 asked about parasternal long axis view being available on the echocardiogram, and it was. And the question was if yes, does the parasternal long axis view show FDA positive aortic regurgitation of greater than 10 percent by color flow Doppler. And I marked no because we didn't use that view to make the assessment of the aortic insufficiency.
>
> But going to Question 8 further explained it. Since the measurements were not made in this area, I couldn't say that that was correct for the amount of aortic insufficiency, but it was my understanding that there was no specific -- certainly in the Singh document, there is no specific place to measure aortic insufficiency. And the parasternal long axis view is not the only place to measure it. It could be measured elsewhere, so we measured it elsewhere because we could see it well there.
>
> Q. And you were still able to find that the aortic insufficiency was of an FDA positive level?
>
> A. Correct. However, it was not done in the parasternal long axis view as questioned on this review and assessment.

Dr. Billhardt simply is wrong and the Court will not consider his testimony on Burns' MAR. The CAS specifically requires the aorta regurgitation be measured in the PLAX view, if available. The PLAX views were available. As to Dr. Billhardt's conclusion that Burns has MMR, the Court finds that his opinion is undermined by his admission that the RJA here is overtraced, the LAA here is undertraced, and the black spaces are erroneously included in the boundaries of the purported jet. In this area, the Court acknowledges that there can be real differences in results between reasonable physicians. This is called interreader variability. Nevertheless, the Court finds, on its review of the echocardiogram and the testimony of the physicians involved, that no reasonable physician could conclude that Burns has MMR. The Court specifically relies on D3322 and the three (3) frames and measurements reported there. It also relies on Dr. Chen's testimony on this subject which is set out in the footnotes.[18]

---

[18] Dr. Chen's testimony follows:

Q. Dr. Chen, what criticisms, if any, do you have of this tracing of the -- what purports to be a mitral regurgitant jet?
A. I don't think that's a mitral regurgitant jet. It didn't tract mitral regurgitant jet.
Q. He didn't trace regurgitant jet?
A. No.
Q. What is it then?
A. Some random color in the left atrium --
MR. BERN: Some what?
THE WITNESS: Random.
JUDGE WALSH: Random what?
THE WITNESS: Random color in the atrium. I bet probably could be a ghosting jet or something.
Q. Let's go to the next frame.
A. And you can see, can I just --
Q. Go back.
A. You can see, it's clear that the cursor it's way following the T-wave, so probably either very early diastole or end systole or early diastole so therefore, the jet actually is not jet.
Q. Its in diastole? It might be?
A. Yeah because you can see the cursor. The EKG is here, so. You will see because one frame just before that was real jet, and this is really not jet.

* * * *

JUDGE WALSH: Just so I understand, is any of this -- let's forget about how it was traced. Is any of this aliased blood?
THE WITNESS: No, it's not a jet, not a mitral regurgitant jet.
JUDGE WALSH: I'm talking about the blue and light blue and I guess with dark stripes or --
THE WITNESS: As an echocardiographer I would say it's totally incompetent tracing.
JUDGE WALSH: Totally incompetent?
THE WITNESS: Totally incompetent.

* * * *

Q. Okay. Let's go to the next frame that we have here on the PowerPoint and can you explain, Dr. Chen, what we're looking at here?

In sum, the Court finds that Wyeth has satisfied it that Dr. Billhardt's conclusion that Burns had MAR and/or MMR is not medically reasonable for several reasons. First, he relies on the wrong view in assessing MAR. Second, the measurements obtained for the RJA and LAA were so flawed as to be medically unreasonable.

R. CATHY BUTCHER

Butcher relies on an August 1, 2002 echocardiogram and report by Dr. Charles F. Dahl. Dr. Dahl found Butcher had MMR using CAS criteria -- RJA/LAA = 20% though no RJA measurements were provided in the report. The technician's worksheet indicates RJAs of 2.4 cm^2, 2.5 cm^2 and 2.4 cm^2.

The August 1, 2002 echocardiogram was reviewed by three (3) experts: Dr. Chen, Dr. Sherrid and Dr. Lassetter. All three (3) physicians concluded that the echocardiogram was technically adequate though Dr. Chen mentions, and a review of the echocardiogram discloses, a high gain setting. Both Drs. Sherrid and Chen conclude that Butcher's echocardiogram does not substantiate a claim of MMR. Dr. Sherrid believes the mitral jet was transient and hardly worthy of measurement. Dr. Chen finds that the RJA was overtraced and the LAA undertraced. One of the problems with the LAA measurement, according to Dr. Chen, is the left atrium was visualized at an oblique angle which serves to significantly reduce its apparent area. Moreover, Dr. Chen observes that "[t]he color Doppler gain setting is too high, which exaggerates the size of any regurgitant jet present." Dr. Chen

---

A. Yeah, this is, actually, I just wanted to look side by side at what the original technicians selected, and this, actually, is the frame before of this frame. The tech said this is a mitral regurgitant jet and it is not. It's like I said before was either artifact or ghosting. That's the jet actually coming out.
Q. When you say "ghosting," what do you mean by that?
A. It's not a jet. It's -- just because, like I say last time, when you turn the TV screen off, you have this ring-down, you have jet -- things appear there for a while but not as dark or real jet there, so therefore, I say it's not a jet. The jet really in the frame before. This is a jet.
Q. Okay. And let's go to the next frame. I should ask this: Did you trace that frame?
A. Yes, this is a replayed frame, so it's not in time, you can see real-time, you can see the jet just before that. So I trace in this frame, this mitral regurgitant jet here.
Q. Let's see what you got in the next frame. What did you get?
A. 1.56.
Q. And with the left atrial measurement, is that 20 percent?
A. It's way below 20 percent, probably 10 or close to -- less than 10 percent.
Q. Would it be medically reasonable to diagnose this individual with moderate mitral regurgitation?
A. No.

planimetered the RJA and LAA at points on the echocardiogram media and made measurements of 1.63 cm^2 and 16.24 cm^2, respectively -- 10%.

Dr. Lassetter concluded that Butcher's correct RJA/LAA measurements were 2.48 cm^2 and 10.4 cm^2 respectively. From this he found that Butcher had MMR. Butcher's LAA measurement, according to Dr. Lassetter, is 10.4 cm^2 which is relatively small. Weyman Text at 1292 (in sample, n = 68, the LAA is 14.2 cm^2 with SD of $\pm$ 3 cm^2). The angle of the transducer and the undertracing of the LAA serve to understate the denominators here. Dr. Chen addressed this concern specifically.

> The high ratio of RJA/LAA measured by the technician and adopted by Dr. Lassetter was obviously a result of mismeasurement of the left atrial area. The left atrial area is on average 14-15 cm^2 in a normal adult with average body surface area or body height. Assuming an LAA of 15 cm^2 in a normal adult, and using the RJA measured by the technician, the RJA/LAA would be much less than 20%. The technician measured LAA to be 10.41 cm^2 which is obviously much smaller than one should except a normal left atrial size to be with an average body surface area or body height. In fact, the left atrial anterior-posterior dimension as recorded on M-mode in this study and measured by the technician is 3.74 cm, which is at the upper normal limit, indicating a larger than average atrial size. 10.41 cm^2 is certainly not an accurate measurement.

The Court finds that the measurement of Butcher's LAA at 10.4 cm^2 is not medically reasonable. The Court accepts Dr. Chen's LAA measurement of 16.24 cm^2 as medically reasonable although in D3288 the LAA was measured at 17.22 cm^2. Even if one were to allow for interreader variability and reasonable medical differences of opinion and find an LAA of 14.2, the mean reported by the Weyman Text, and were to use Dr. Lassetter's RJA of 2.48 cm^2, the RJA/LAA ratio would still be well under 20%.

Accordingly, the Court finds that Wyeth has satisfied its burden to show that Butcher's diagnosis of MMR was medically unreasonable.

S. DENTON CANTWELL

Cantwell (Carlwell in the report) relies on a November 7, 2002 echocardiogram and report of Dr. Raymonda Rostegar. Dr. Rostegar found that Cantwell had MAR using CAS criteria -- JH = .5 cm and LVOT = 2.2. The Court calculated the JH/LAA as 22.7%. The technician's worksheet reported JH of .51 cm, .46 cm and .47 cm and a LVOT of 2.23 cm. The technician noted that it was difficult to assess regurgitation "due to pt. body habitus."

The November 7, 2002 echocardiogram was reviewed by three (3) experts: Dr. Chen, Dr. Sherrid and Dr. Lassetter. Dr. Sherrid felt the gain was set too high making the echocardiogram technically deficient. Drs. Chen and Lassetter found the diagnostic quality to be adequate. Both Drs. Sherrid and Chen concluded that the aortic regurgitation was trivial. Dr. Chen observed that the JH and LVOT were not properly measured.

> The JH was not measured just below the valve. The JH was not measured from a proper angle. The LVOT was not measured from a proper angle. The AI "jet" appears tiny and intermittently during diastole. Additionally, the selected "jet" is not a clearly delineated jet on still frame. Even so, the percentage of regurgitation does not reach 10%.

Nevertheless, both physicians measured the JH/LVOT with Dr. Chen determining it to be 8.3% and Dr. Sherrid determining it to be 9.5%.

Dr. Lassetter found the echocardiogram "demonstrated mild aortic regurgitation according to ..." CAS criteria. Dr. Lassetter found a JH of .51 cm and a LVOT of 2.23 cm -- the exact same measurements of the technician. The JH/LVOT computes to 23% according to Dr. Lassetter.

The Court has examined the echocardiogram and the submissions of the parties and the testimony of the experts and finds that Wyeth has not established that a diagnosis of MAR for Cantwell is medically unreasonable.

T. RAVEN CHADWELL

Chadwell relies on a November 23, 2002 echocardiogram and study by Dr. Scott L. Roth. Dr. Roth found that Chadwell had MMR using CAS criteria -- RJA/LAA = 21%.

The November 23, 2002 echocardiogram was reviewed by three (3) experts: Dr. Chen, Dr. Sherrid and Dr. Lassetter. All three (3) physicians concluded that the echocardiogram was of adequate diagnostic quality though Dr. Chen noted that the gain settings were set too high. Both Drs. Sherrid and Chen concluded that mitral regurgitation was present but it did not rise to MMR because the RJA was overtraced and the LAA undertraced. Drs. Roth, Chen and Sherrid found the LAA to be 17 cm^2, 17.48 cm^2 and 17.6 cm^2, respectively -- certainly within the range of interreader variability. Dr. Chen assessed the RJA between 2.33 cm^2 and 2.65 cm^2 but conditioned this finding because of the high color Doppler gain settings. Dr. Sherrid believed the RJA was 2.9 cm^2, while Dr. Roth found the RJA to be 3.5 cm^2.

Dr. Lassetter found Chadwell's echocardiogram demonstrated MMR. Like the other physicians, he calculated the LAA to be 17.2 cm but found the RJA to be 3.6 cm^2. Thus, the question here is can the varying RJAs be explained as a result of interreader variability or is the conclusion that Chadwell's RJA is 3.6 cm^2 medically unreasonable.

The Court has carefully reviewed the echocardiogram and considered the testimony of the experts and Exhibit D-3304. In the Court's view, the RJA was overtraced by the technician and Dr. Lassetter. The Court finds that the RJA tracing of 2.65 cm^2 reflected in the second page of Exhibit D-3304 is the most reasonable. Even allowing for reader variability, Dr. Lassetter's 3.6 cm^2 RJA is not medically reasonable. Consequently, the Court finds that Wyeth has established that Chadwell's MMR diagnosis based on the November 23, 2002 echocardiogram is not medically reasonable.

U. DOLORES COLLINSWORTH

Collinsworth relies on a July 20, 2002 echocardiogram and report by Dr. Edward S. Katz. Dr. Katz found that Collinsworth had MMAR using CAS criteria -- JH/LVOT = 33%. The technician found MMAR with JHs measured as .65 cm, .65 cm and .68 cm and a LVOT of 2.02 cm.

The July 20, 2002 echocardiogram was reviewed by three (3) experts: Dr. Chen, Dr. Sherrid and Dr. Lassetter. Both Drs. Sherrid and Chen concluded that this echocardiogram was not conducted in a technically adequate manner such that reliable medical conclusions regarding the presence and severity of valvular regurgitation could be assessed. Dr. Sherrid noted that "[t]he gain of this study is set very high, too high to assess the significance" of Collinsworth's aortic regurgitation. Dr. Chen concurred, finding "[t]he color Doppler gain is set extremely high, making it impossible to make a reliable assessment of regurgitation." Dr. Chen also noted the low, though acceptable, Nyquist limit of 51 cm/sec. Neither physician attempted to diagnose aortic regurgitation or its severity. In this regard, Dr. Chen observed:

> The color Doppler gain was set very high, making it impossible to clearly delineate the purported AI jet throughout diastole. An assessment of the severity of aortic regurgitation is unreliable because of the high color Doppler gain.

Dr. Lassetter found Collinsworth's echocardiogram

> to be of diagnostic quality with appropriate settings for interpretation. It is my opinion that the echocardiogram performed on 7-20-02 demonstrated moderate aortic regurgitation according to methods of quantifying regurgitation and ranges for various levels of regurgitation as stated in the Singh article.
>
> The aortic regurgitation was visualized in the parasternal long axis view as well as the apical 5 and apical long axis views. The AR jet was present in diastole close to the origin of the valve, tracking backward into the left ventricle and was blue/yellow in color. The jet color, location, and timing of this jet is consistent with the criteria for aortic regurgitation as stated in the Singh article.
>
> The jet height measured at .68 cm and the LVOT diameter at 2.02 cm [the same measurements as made by the technician]. Utilizing the JH/LVOT formula required for quantifying these echos, I determined the percentage

> to be 34%, which would place Ms. Collinsworth's aortic regurgitation in the moderate range.

Review of the echocardiogram and the testimony of the experts convinces the Court that this echocardiogram was performed in a grossly inadequate manner. The Court finds that Wyeth has established that no reliable medical conclusions can be drawn from it.

V. L.V. COLSTON

Colston relies on a November 22, 2002 echocardiogram and report by Dr. Gerald I. Cohen. Dr. G. Cohen found Colston had MAR using CAS criteria -- JH/LVOT = 15%. The study quality was deemed "adequate."

The November 22, 2002 echocardiogram was reviewed by three (3) experts: Dr. Chen, Dr. Sherrid and Dr. G. Cohen. All three (3) physicians agree that the echocardiogram was technically adequate. Both Drs. Sherrid and Chen find no more than trace aortic regurgitation. Dr. Sherrid notes that the jet is narrow at its origin "just below the valve. The jet then widens, mainly due to poor lateral resolution of the color in the machine." Dr. Chen concurs and adds that "the JH was not measured just below the value and was measured beyond the jet edges." According to Dr. Chen, both the JH and LVOT were not measured on the correct angle. Both physicians measured the JH/LVOT with Dr. Sherrid finding 6.25% and Dr. Chen 5.29%.

Dr. G. Cohen found that Colston had MAR based on a JH of .36 cm and an LVOT of 2.36 cm. This computes to 15.3%. Dr. Chen made the following observations after reviewing Dr. G. Cohen's submission.

> I have re-reviewed the echocardiogram of L.V. Colston. I have also reviewed the affidavit of Dr. Cohen, in which he asserts that the original measurement by the technician recorded on the CD was correct and adopts the valve of the measurements. As I noted ..., the JH measurement was improper. Note that on frame 10:33:32 the digital cursors were placed beyond jet edges, leading to overmeasurement.
>
> As mentioned in Dr. Weyman's and Feigenbaum's textbooks and according to standard clinical convention,

> JH for quantification of AR should be measured just below the aortic valve where the narrowest part of the jet resides. It appears that on this study, the measurement of JH was likely not just below the valve because the technician measured the broadest part of the jet height, which usually occurs far into LVOT. The narrowest part of the jet just below the aortic annulus should be measured. That is where I measured previously, as shown in the attached picture in my original affidavit. The JH/LVOT = 0.145/2.735 or 5.29%.... When re-reviewing the study, I also selected other frames in which the aortic valve was clearly visualized for JH measurement. When JH is measured just below the aortic valve in those frames, I found it to be even smaller than the one I originally measured. Therefore, aortic regurgitation is trace.

When faced with Dr. Chen's criticisms during his testimony, Dr. G. Cohen stood his ground. His cross-examination on this point is reproduced in the footnote.[19]

---

[19] Dr. G. Cohen's cross-examination follows:

> Q. Do you agree, Dr. Cohen, that it would have been appropriate and more accurate if the sonographer had measured this jet height more proximal to the valve than was done on this image?
>
> A. I don't agree that -- it should be at above the level of the annulus.
>
> Now, what I see here is that the cursors are at two different levels relative to the aortic valve. They should be at the same levels, which is above the level of the annulus in my mind. But to be fair, the guidelines don't say that it has to be exactly at that level.
>
> Q. Would you concede this point, Doctor, that if someone elected to planimeter this jet more proximal to the valve orifice, that in fact, the jet height would be less than what is planimetered here at .36 centimeters? That is, the jet is more narrow as it moves toward the valve proximally. You would agree with that?
>
> A. I would.
>
> Q. All right, sir. You would not be in a position to tell us, would you, Doctor, what the jet height measurement of the jet would be more proximal to the valve, would you?
>
> A. Well, I would be in the position to do it if I had the tracing in front of me and I needed to do it or I put calipers on your television monitor, I might be able to, except for the -- I can't see the -- out of the side of the screen, the caliper markers, and that would be a crude measurement.
>
> Q. Dr. Cohen, are you able to identify the aortic valve structures in the image that we have before you as traced by your sonographer?
>
> A. If I turn the light off, I vaguely can see it. If you move your cursor away, I would probably could see it better still.
>
> Q. My apologies.
>
> A. I can see the very tip of the aortic valve leaflet.

The Court believes that Drs. Sherrid and Chen are correct and were the Court to be acting as a factfinder it would find that Colston did not satisfy the CAS criteria for MAR. However, considering Dr. G. Cohen's excellent credentials, and the difficulty in measuring this jet, the Court finds that Wyeth has not quite established that Dr. G. Cohen's opinion that Colston has MAR is medically unreasonable.

W. DIANE CORVEY

Corvey relies on an echocardiogram and report which was dictated on November 8, 2002 by Dr. James Colasacco. Dr. Colasacco found Corvey had

---

Q. I don't believe our technology is going to allow you to demonstrate that for us, but would you agree that it's somewhat proximal to the jet. That is, it is to the right of the jet as imaged is where the valve orifice would be and the valve plain would be?
A. Still your cursor is a little bit too far to the right and I would put it more like that.
Q. How about that?
A. Right there, that would be approximately right.
Q. All right, sir.
Doctor, let me show you one more image and then I'll be finished with my examination. If we can look at LC-8.
THE TECHNICIAN: We're on 8.
MR. WHEELER: I'm sorry.
THE TECHNICIAN: We're on 8.
MR. WHEELER: Okay.
Q. LC-11, my apologies, and for the record, your Honor, this is Exhibit D-3188 and I believe it's already been marked and received into evidence.
Dr. Cohen, your report indicates on the last page of that document that you were provided a copy, I believe of this image as prepared by Dr. Chen; is that correct?
A. That's correct.
Q. Do you know Dr. Chen?
A. No, I don't.
Q. Do you agree, looking at this image that this is a reasonable and appropriate measurement of this jet as evidenced on this echocardiogram by Dr. Chen?
A. No, I don't.
Q. You disagree?
A. Yes, I do.
Q. What would be your disagreement Dr. Cohen?
A. When I read -- when I interpret -- do these type of measurements, on a day-to-day basis, I take my measurements based on the best quality image I can get. I don't feel that this is an image that shows the aortic regurgitation jet clearly or optimally and I have another problem, too -- I feel that the plain -- the diameter of the LVOT is slightly off axis and it should be more perpendicular to the axis of the left ventricular outflow tract. I don't feel that the aortic regurgitation is shown well.

MMAR using CAS criteria -- JH/LVOT = 26% -- although no measurements are provided with this skeletal report. Dr. Colasacco describes the echocardiogram as having "good quality."

The echocardiogram was reviewed by three (3) experts: Dr. Chen, Dr. Sherrid and Dr. Colasacco. All three (3) physicians agree that the echocardiogram was of adequate quality, though Dr. Chen observes that "[t]he color Doppler gain is set too high." Both Drs. Sherrid and Chen agree that there is no aortic regurgitation, let alone MMAR. Dr. Sherrid tersely dismisses the aortic regurgitation by observing that there is "[n]o aortic regurgitation." Dr. Chen concurs, finding

> [t]here was no true aortic regurgitation measured, but rather color artifact from high color Doppler gain settings. Additionally, one of the purported AI "jets" is measured in systole. No aortic regurgitation is visualized in the parasternal long axis view.

Dr. Colasacco disagrees. In his view, Corvey has MMAR and it is demonstrated in the echocardiogram. Dr. Chen simply devastates Dr. Colasacco's conclusions:

> Dr. Colasacco states that "frame #10 (14:23:54) demonstrates real-time aortic regurgitation" and "frame #11 demonstrates freeze-time frame of aortic regurgitation." I disagree with Dr. Colasacco's judgment. There is no aortic regurgitant jet visualized on either frame. I reviewed the real-time images frame by frame and found that there is a tiny yellow color dot at the aortic valve on a frame at the end-systole-early-diastole transition. No jet or turbulent flow from the aortic valve is visualized in the LVOT. The color dot is most likely a random color speckle from high color Doppler gain settings, as similar color speckles can be visualized in other locations.
>
> Dr. Colasacco also stated that "the presence of moderate aortic regurgitation is confirmed by continuous wave and pulse wave Doppler." I do not see any aortic regurgitant or high velocity signal in the LVOT during diastole on spectral Doppler [pulsed wave/continuous wave]

> recording. (The only CW recording available for interpretation is on frame #33 (14:31:10).) Furthermore, CW/PW Doppler is usually used to confirm the presence of aortic regurgitation but not the degree of aortic regurgitation although a complete velocity profile of aortic regurgitation on CW Doppler can be used to determine pressure half-time of the aortic-ventricular gradient decay and pressure half-time can be used as an additional parameter for assessment of severe or hemodynamically significant aortic regurgitation....

Having reviewed Dr. Colasacco's testimony[20] as well as the echocardiogram, the Court is satisfied that Wyeth has shown that this minimally

---

[20] Dr. Colasacco's direct and cross-examination on Corvey is reproduced in this footnote.

> [BY MR. BERN:] Dr. Colassaco, why don't we talk about the four echos which are currently at issue in this hearing and the first one that we'll talk about and we're going to go in alphabetical order is Diane Corvey.
>
> What was the date of the original echocardiogram that was performed in your office and that you read, Doctor?
>
> A. My reading was from November 8, 2002.
>
> Q. And what were your findings with respect to the aortic and/or mitral valve?
>
> A. At that time, and again, with review, I called it a mild aortic insufficiency.
>
> Q. And I'm sorry, with respect to the mitral? I didn't hear you.
>
> A. With respect to the aortic alone, I called it moderate. With the mitral valve, I said that it was a normal appearing valve without aortic -- without mitral insufficiency.
>
> Q. And the moderate aortic, that would be an FDA-positive valve?
>
> A. Based on the criteria of the JH to LVOT ratio 26 percent.
>
> JUDGE WALSH: What was the ratio, 26 percent? So it was over 25, so it qualifies under the Singh criteria as moderate.
>
> THE WITNESS: Correct.
>
> Q. I don't want to have to ask you these questions again. This will apply to all of the echos we're going to talk about today, but all four echos that are in issue today, Doctor, were they performed according to the settlement criteria?
>
> A. Yes, they were.
>
> Q. And the findings of all four of those echocardiograms that are at issue today, were they -- was there a reasonable medical basis for your finding?
>
> A. Yes, there were.
>
> Q. And with respect to this particular echocardiogram on Diane Corvey, the finding of moderate aortic insufficiency, did you have a reasonable medical basis for that?
>
> A. Yes, I did.
>
> Q. And then following that echocardiogram, Doctor, did you subsequently do a reassessment of that particular echo with respect to Diane Corvey?
>
> A. I did review it a second time.
>
> Q. And what were your findings with respect to the aortic valve at that time?
>
> A. Again, I confirmed my initial findings of moderate aortic insufficiency.

JUDGE WALSH: How did you do that, Doctor; by eyeballing the data or in some other fashion?
THE WITNESS: I reviewed the studies both in real-time and picked out certain frames that confirmed both real-time or measurement, you know, exact slide measurement to reconfirm.
JUDGE WALSH: That's, basically, at Paragraphs 11 and 12 of your certification, you say that Frame 10 and Frame 11, which I guess are presentation frames, but the time stamp is 14:23:54 for the real-time aortic and 14:23:54 again in the freeze frame, I guess of that particular loop.
THE WITNESS: Those frames and others.
JUDGE WALSH: Okay. Those are the ones you mentioned in your certification.

* * * *

JUDGE WALSH: It does say Frame 10. Is that a typo or --
THE WITNESS: Yeah, that may be my mistake, but that's -- no, I'm using Frame 9, that's from my notes.
[BY MS. PETERSEN:] And you believe this loop shows aortic regurgitation of a moderate degree?
A. Correct, from the Singh criteria, just the appearance of a mosaic speckled jet during the time frame that would fit aortic insufficiency.
Q. And do you see speckling on this echo anywhere besides near the aortic valve?
A. Yes. Am I allowed to get up?
JUDGE WALSH: Sure.
THE WITNESS: Thanks.
JUDGE WALSH: We'll even give you a pointer.
THE WITNESS: I'm referring to this speckle.
JUDGE WALSH: And also down in the tissue.
THE WITNESS: Well, here, right, but I think the question was that it begins here and there was a speckled view here.
JUDGE WALSH: What begins where?
THE WITNESS: We're saying the aortic insufficiency, the initial -- I didn't rely purely on just the speckling or the mosaic here, right at the valve, but further back here as well.
JUDGE WALSH: Well, I think what Ms. Petersen is saying is that there's a lot of speckling in the tissue which means the gain setting is very, very high here. Do you agree? Take a look down in the lower right.
THE WITNESS: Oh, I'm not agreeing with her about the gain being high. Again, this is the best view that we have based on the patient's body habitus, height and weight.
Q. And Dr. Colassaco, is that holodiastolic aortic regurgitation you're seeing or is it just a frame or two?
A. No, I'm saying that there's an initial early diastolic and there's a later diastolic view.
JUDGE WALSH: Doesn't it worry you when you have large color displays in the tissue itself?

I mean how can you tell when something is a regurgitant jet and artifact with a gain setting that's so out of control here?

I mean, right along the right axis, I mean, you see the color all through the tissue.
MR. BERN: Your Honor, just for the record, I want to make an objection to your commenting that the gain control is -- or is out of control. That's not what the doctor said. That's your interpretation.
JUDGE WALSH: No, no. Listen, I have two eyes and I can ask questions. And this hearing, I get to ask as many questions as anybody else and he, who is

the expert, can disagree. On the other hand, I don't plan to leave my eyes outside the courtroom, so you can object all you want and your objection is overruled.
MR. BERN: Fair enough, judge.
THE WITNESS: Couple of comments, again, knowing that the patient's body habitus is 5'3 207 pounds, which is morbidly obese, the fact that the settings you have there for .61 sonometers per second are adequate, and going with some of the criteria that Miele writes in his articles, I'm saying based on that, my opinion was that the patient has aortic insufficiency.
JUDGE WALSH: That's not what was being asked. Would you agree that the gain setting has caused color to be displayed throughout the tissue on the right axis of the probe?
THE WITNESS: Well, I agree with you. What I'm saying is I agree with what you're saying about the gain setting.
I'm saying that that is the best gain setting for this particular individual.
JUDGE WALSH: Just so we're clear, I mean --
THE WITNESS: That area to the right of the valve.
JUDGE WALSH: In this area up at the top, this is all through tissue, and then down here you have color infiltrating into tissue. Now, we know that that's artifact.
THE WITNESS: Correct, but I'm not referring to that in my call. What I'm saying --
JUDGE WALSH: I know. You're referring to the area in here.
THE WITNESS: And further back.
JUDGE WALSH: Well --
THE WITNESS: In other words, I'm trying to establish that I feel that throughout that period of diastole, there's a speckled period --
JUDGE WALSH: Let's look on the left axis now. You see the color is infiltrating again in the tissue on the left axis of the probe, fair?
THE WITNESS: Correct. Again, I agree with you about the gain setting. What I'm saying is for this particular patient, who is 5"3, 207 pounds, these are your best settings.
JUDGE WALSH: So, in other words, despite -- I mean you would agree that the artifact is pronounced in this particular loop, would you not?
THE WITNESS: I agree that there's artifact, yes.
JUDGE WALSH: I said you would agree that the artifact is pronounced?
THE WITNESS: Yes, I would. All right.
MS. PETERSEN: I just have a couple more questions about this page.
Q. So you agree that this artifact here, I believe you just stated?
A. Correct.
Q. And this up here is artifact?
A. That could be artifact.
Q. But these colors in here look similar to these colors here?
JUDGE WALSH: In the middle.
THE WITNESS: In the middle and further to the left -- not there.
Q. Further to the left, those colors look the same as these colors on the top and bottom, don't they, Dr. Colassaco?
A. Correct, you can say that the red and blue look the same as the red and blue above.
Q. But you know that this is aortic regurgitation, and this is artifact?
A. I'm going by timing --
JUDGE WALSH: "This" does not help anybody, including you. So never say "this" and "that." Always say the top right is artifact, the middle portion is not, if that's what the doctor is saying or if that's what you're saying.

adequate echocardiogram does not support a medically reasonable conclusion that Corvey has MAR let alone MMAR. The Court further finds that no reasonable physician could claim that pulsed wave and continuous wave Doppler support Dr. Colasacco's conclusion in this case. Finally, the Court believes Dr. Colasacco makes little or no effort to show how the JH/LVOT supporting his conclusions were measured by him and how they could be replicated. This is an essential in evaluating scientific conclusions.

X. MARINA DeROSA

A. What I'm saying is that the areas that the judge pointed out to the right side, along the angle of the Doppler color flow, that there is a possibility, yes, strong, that that is due to the increased gain.

I'm also saying, one, that these are -- based on the whole echo, these are the best views we had, given the fact that Diane is 5 feet 3 and over 200 pounds. And we're still able to get fair settings and that the timing of the EKG and the mosaic speckled jets that you're saying at the aortic valve and further back are, to me, consistent with aortic insufficiency.

JUDGE WALSH: What's the depth of the probe here, Doctor?

THE WITNESS: There's 13.5 sonometers left, and then you have your Nyquist limit. You have your .61 Nyquist limit.

JUDGE WALSH: Well, I mean 13.5 is not a deep probe at all.

THE WITNESS: I'm not saying -- you're not asking me about the technique. I'm saying of this person's echos that I read, the best views that I have, this is the best I have.

JUDGE WALSH: I know. But this isn't dense tissue if she's morbidly obese. This is adipose?

A. Correct.

JUDGE WALSH: I mean sound waves travel better through that type of tissue than dense muscular tissue?

THE WITNESS: That's not necessarily true. This is s morbidly obese patient. You're saying that this patient has to go through four or five inches of adipose?

JUDGE WALSH: So what? The total probe is 13.5 centimeters.

THE WITNESS: It's not just the probe -- it's not just the sonometers. We're talking about Nyquist limits, jet width.

JUDGE WALSH: Are you telling me that the sound would travel better in some highly muscular individual than someone who's morbidly obese.

THE WITNESS: No, I didn't say that, but what I did say was that the fact that the patient was morbidly obese does come into play in making your measurements.

JUDGE WALSH: It may if the probe length is increased as a result of the morbidly obese body habitus. That's the thing you take into account, and here it's 13.5 centimeters, which is ho hum. Fair?

THE WITNESS: Fair.

Q. So even with this morbidly obese patient, you were able to get a Nyquist limit of .61, correct?

A. Correct.

DeRosa relies on a November 16, 2002 echocardiogram and report by Dr. Robin S. Friedberg. Dr. Friedberg found DeRosa had MAR and MMR using CAS criteria -- JH/LVOT = 21%; RJA/LAA = 24%.

The November 16, 2002 echocardiogram was reviewed by three (3) experts: Dr. Chen, Dr. Sherrid and Dr. Skop. Both Drs. Sherrid and Chen agree that the echocardiogram was not conducted in a technically adequate manner such that reliable medical conclusions regarding the presence and severity of valvular regurgitation could be drawn from it. Dr. Sherrid found that the "[g]ain is much too high throughout the study. It is so high that it precludes any accurate interpretation." Dr. Chen concurred using virtually the same words. Both Drs. Sherrid and Chen, while emphasizing the technical infirmities of the study, also found regurgitation. This is significant because of the strong likelihood that any observed phenomenon would be grossly exaggerated because of the quality of the echocardiogram. Nevertheless, little or no evidence of either mitral or aortic regurgitation was demonstrated.

Dr. Skop in two (2) Affidavits found that "[a]lthough the color Doppler gain was overset, ... reliable medical conclusions regarding the severity of regurgitant valvular lesions can be made based on the data provided."[21] Dr. Skop went on to assess the MMR claim and supported it while acknowledging "[t]he MR jet is overtraced" and "the LAA was undertraced and measured at an oblique angle." Nevertheless, he concluded that this echocardiogram confirms MMR. As to the MAR claim, he identified a frame consistent with MAR and found JH/LVOT equal to 21%.

The Court cannot accept Dr. Skop's explanation given the grossly inadequate echocardiogram. The high gain distorts the very errors he points out in area measurements necessary to determine whether MMR exists. The gain setting creates color speckling which fills the color box when PLAX views assessing aortic regurgitation are attempted. The Court finds that Wyeth has established that this echocardiogram is so technically deficient that no reasonable medical judgments can be drawn from its review.

[21] By agreement of counsel, Dr. Skop's testimony was by Affidavit only.

Y. VINCENT DINGILLO

Dingillo relies on a May 24, 2002 echocardiogram performed by Cardiac Consultants of Chicago, Ltd. and a report by Dr. Richard Levinsky. Dr. Levinsky found Dingillo had MAR using CAS criteria -- JH/LVOT = 21%.

The May 24, 2002 echocardiogram was reviewed by three (3) experts: Dr. Chen, Dr. Gopal and Dr. H. Cohen. All three (3) physicians agree that the echocardiogram was technically adequate through Dr. Chen notes "[t]his was a poor quality study." Both Drs. Gopal and Chen note that no aortic regurgitation is demonstrated on the echocardiogram. Dr. Gopal observes "[t]here is no evidence of aortic regurgitation on the parasternal long axis view or in the apical view. Flash color artifacts are noted. No consistent diastolic color flow jet is visible." Dr. Chen concurs, finding that "[n]o aortic regurgitation is visualized on the echocardiogram."

Dr. H. Cohen claims that Dingillo has MAR with JH/LVOT equal to 21%. He tells us that he "no longer [has] original worksheet" but provides frame markers within the echocardiogram which he believes support the claim. The cross-examination of Dr. H. Cohen demonstrates he has little to support his opinion.[22] In

[22] The cross-examination of Dr. H. Cohen with respect to Dingillo is set out in this footnote and shows that he has virtually no evidence supporting the claim that Dingillo has MAR.

Q. Okay. And let's move on to Vincent Dingillo.
Now, Doctor, you list several frames again in your 2004 report. And concerning aortic regurgitation, you listed four frames.
MR. MICHAEL: And let's put up the first of those frames, which is 8:51:28, Defendant's Exhibit 3259, VD.3. Mr. Dingillo's echocardiogram has been marked and submitted as 3166, defendant's exhibit.
Q. Okay. Now, Doctor, that's Frame 8:51:28, right?
A. Yes, it is.
MR. MICHAEL: Okay. Let's put up VD.2 which is Defendant's Exhibit 3260, which is 8:41:29. That's the same frame, right? And if we can toggle back and forth between the two, all right? Are you toggling? Sorry. VD.3 and VD.2, Defendant's Exhibit 3259 and 60.
Q. Those are the same frame, right?
A. Essentially, yes.
Q. Okay.
A. One of them is a little later than the other one, but --
Q. But essentially, they are --
A. They are showing the same thing.
MR. MICHAEL: And let's look --put up Frame 8:25:14, VD.6, Defendant's Exhibit 3265.
Q. And again, that's the same frame, just slightly degraded, right?
A. Right.
Q. Okay. Now, I would like to -- now, that frame that we're looking at, the last one, 3265, was actually pulled from the real time as opposed to still frames.

fact, Dr. H. Cohen concedes that the phenomenon seen, even if it is an aortic jet, is not holodiastolic but lasts only an insignificant period during diastole.

Dr. Chen's reply Affidavit and his criticisms of Dr. H. Cohen are devastating and demonstrates that no reasonable physician could conclude on the basis of the evidence presented by Dr. H. Cohen that Dingillo has MAR.

> Dr. Cohen ... states that "frames 0:08:51:28 and 0:08:41:29 and 0:10:52:05 show aortic regurgitation," and "frame 0:12:01:14 shows aortic regurgitation by Doppler." Frame 0:08:51:28 and frame 0:08:41:29 are the identical frame of an echo image selected from a cine-loop slow playback and playforward and were recorded twice on the CD (originally video tape). The

---

A. Right.
MR. MICHAEL: So let's play the loop that surrounds that frame which is Defendant's Exhibit 3264. T.J., for you, 6017. And this is a loop of 8:25:05 to 8:25-15 of the echocardiogram which is Defendant's Exhibit 3116. Play it.
Q. Now, Doctor, that's not holodiastolic aortic regurgitation, is it, h-o-l-o?
A. I can't tell with it -- I can't tell because it's starting in systole and going into diastole. This loop is half systole and half diastole.
Q. And that flash appears at the beginning, the very beginning of diastole, right?
MR. MICHAEL: Can we slow it down?
Q. And it lasts for about two frames, is that right?
A. I didn't count them, so if you want me to count them, we can do that.
MR. MICHAEL: Okay. Let's go -- keep going frame by frame, slow motion.
A. That's three frames.
Q. Three frames, and it disappears, right?
A. It does.
Q. And the three frames are right at the beginning of diastole, right?
A. That's correct.
MR. MICHAEL: Okay. Let's go back to the regular video camera.
Q. Okay. Now, the third frame or the second frame that you put down for aortic regurgitation -- or I'm sorry, the third frame is 10:52:05 which has been marked as Defendant's Exhibit 3261 and is VD.4.
Doctor, that's 10:52:05 on the screen.
MR. MICHAEL: Let's switch to it.
A. Okay.
Q. And that's an apical view, right?
A. Yes, it is.
MR. MICHAEL: Okay. And let's switch back.
Q. Now, the fourth frame you put up on your -- or you put down on your 2004 report is Frame 12:01:14, right?
A. Right. But that was by Doppler, not color Doppler.
Q. And when you say "Doppler," you mean CW Doppler?
A. CW.
Q. Okay. So that's not a parasternal long axis color flow Doppler, right?
A. That's correct.

> frame is from a corresponding real-time image from a cardiac cycle with time stamp of 0:08:25:05 - 0:08:25:25. By replaying the real-time images frame by frame, I found that the frame 08:25:15 is identical to the above two frames mentioned by Dr. Cohen, and the color in the LVOT is at endsystole and appears only in that frame. There is not any similar color indicating aortic regurgitation in the LVOT in 6 diastole frames during the cardiac cycle. Frame 0:10:52:05 depicts apical 4-chamber view with mosaic color in the left atrium which is consistent with mitral regurgitation (if not an artifact) and is certainly not an aortic regurgitant jet as claimed by Dr. Cohen. Therefore, there is no aortic regurgitation present. On frame 0:12:01:14, there is a pulse wave Doppler tracing of the aortic valve and LVOT in the apical 5-chamber view. There is no aortic regurgitant signal on the Doppler tracing. Note that the tracing is ... poor quality and was performed and recorded in a substandard manner. The baseline of pulse-wave Doppler tracing was set improperly in the middle of the tracing and should have be [sic] shifted up to avoid aliasing.

Accordingly, the Court finds that Wyeth has satisfied its burden and has shown that no reasonable physician could conclude that Dingillo has MAR on the basis of this echocardiogram.

Z. ALEXIS ESTREMERA-BRETT

Estremera-Brett relies on an echocardiogram and report which was dictated on October 21, 2002 by Dr. James Colasacco. Dr. Colasacco found that Estremera-Brett had MMAR and MMR using CAS criteria -- JH/LVOT = 28%; RJA/LAA = 24%. Dr. Colasacco noted that this was a "good quality echocardiogram."

The October 21, 2002 echocardiogram was examined by three (3) experts: Dr. Chen, Dr. Gopal and Dr. Colasacco. All three (3) physicians agree that the echocardiogram was technically adequate though both Dr. Gopal and Dr. Chen note that the gain was set too high. Both Drs. Gopal and Chen found that there was no reasonable medical basis for a diagnosis of MAR let alone MMAR. Moreover,

according to both physicians Dr. Colasacco measured aortic regurgitation in systole--the wrong cardiac cycle. Dr. Gopal, in these regards, noted:

> No consistent diastolic color flow jet is visible and no appreciable aortic regurgitation is seen on pulsed wave Doppler examination. The frozen frames on the study from which ratio determinations were presumably made actually represent late systolic frames.

Dr. Chen's comments are almost identical. As to the MMR claim, both Drs. Gopal and Chen were emphatic that the claim was medically unreasonable. Dr. Gopal put it this way:

> Real time color Doppler examination reveals only mild mitral regurgitation. The color gain settings seem slightly high as evidenced by some speckling in some areas. Four ratios of jet area/left atrial areas were used and only two purportedly met criteria. However, the two that met criteria used broken jets and included some low velocity signals, thus resulting in overestimation of the ratio. The ratio of 2.34/14.56 is probably most accurate and results in a ratio of 16% which does not satisfy the criteria.

Dr. Chen had the same view:

> The RJA was overtraced, including low velocity flow. the LAA was measured at an oblique angle, thereby underestimating its size. The purported mitral regurgitation was backflow. Even so, the percentage of regurgitation does not reach 20%.

Dr. Colasacco sees it a different way. According to him aortic regurgitation is present at 17:34:36 in real time and 17:34:38 represents a freeze-frame of aortic regurgitation. As to the claim of MMR, Dr. Colasacco concludes it was present and believes that 17:39:04 demonstrates its presence in real time and 17:39:05 represents it as a freeze frame. The Court is satisfied that the frame Dr. Colasacco relied upon for his diagnosis of MMAR was taken in systole. He practically

admitted it on cross-examination.[23] As to the MMR claim, Dr. Colassaco says that the echocardiogram supports it. As already noted Dr. Gopal points out that only two (2) of the frames planimetered actually support a RJA/LAA above and those frames achieved the minimum MMR by overtracing the RJA and undertracing the LAA.

Review of the frames identified by Dr. Colasacco as well as the testimony of the experts convinces the Court that Dr. Colasacco was acting in a medically unreasonable manner when he claimed that this echocardiogram establishes MMAR. The Court finds that he measured the phenomenon he calls a jet in systole rather than diastole. As to the MMR claim the Court again finds that Dr. Colasacco's opinion that MMR is present is medically unreasonable. For the reasons articulated by Drs. Gopal and Chen there is mitral regurgitation but it does not rise to the level of MMR. It is clear the RJA was overtraced and the LAA undermeasured because the transducer angle foreshortened it. The Court finds that

---

[23] The full cross-examination of Dr. Colassaco is set out below:

> Q. Let's talk about aortic regurgitation on this echocardiogram for Mrs. Estremera-Brett. If we look at Page 4 of 44 on the DICOM study, Defense Exhibit 3118, this is the frame you cite to support your opinion that Ms. Estremera-Brett has moderate aortic regurgitation; is that correct?
> A. Correct.
> Q. And Dr. Colassaco, is the cursor past the QR--in the middle and past the QRS cycle on this frame on the EKG?
> A. That's what I'm looking at.
> JUDGE WALSH: You can get it. If you can pick it up on your screen, that's fine.
> A. That's what I'm looking at. It's just passed it.
> Q. So this frame is during systole, isn't it, Dr. Colassaco?
> A. It's at the end of diastole or the beginning of systole.
> Q. So this frame could very well be at the very beginning of systole and this is what you're relying on for your opinion that Ms. Estremera-Brett has moderate aortic regurgitation?
> A. Correct.
> JUDGE WALSH: There were about five questions in there. So you don't have to get to the finish line that quickly. Are you telling me that this was measured in diastole? That's the first question.
> A. Right, end diastole. I think the term they used in isovolumetric of the measured area or time period rather.
> Q. And that's the period between diastole and systole, isn't it?
> A. I'm saying end diastole. The term that they use--I agree with you, yes, that is the time. I'm saying end diastole. The term that they used was isovolumetric time.
> Q. So you believe this is during diastole, even though the cursor is on the QRS?
> A. Correct. I'm saying it's end diastole, yes.
> JUDGE WALSH: And we're talking about which individual here?
> MS. PETERSEN: Estremera-Brett.

Wyeth has satisfied its burden and has shown Dr. Colasacco's opinions are medically unreasonable as to both the aortic and mitral value claims.

AA. ROBERT GILDERSLEEVE

Gildersleeve relies on an echocardiogram and report which was dictated on August 26, 2002 by Dr. James Colasacco. Dr. Colasacco found Gildersleeve to have MAR and SMR using CAS criteria -- JH/LVOT = 20%; RJA/LAA = 45%. Dr. Colasacco described the echocardiogram as having "good quality". No worksheets were part of Dr. Colasacco's report nor are any underlying numbers contained in the report.

The echocardiogram was reviewed by four (4) experts: Dr. Vasey, Dr. Gopal, Dr. Colasacco and Dr. Lazar. While all the experts believe the echocardiogram can be interpreted, both Drs. Gopal and Vasey note that the gain is excessive. Dr. Vasey, for example, noted that : "[t]he color Doppler gain was extremely excessive..." These observations are inconsistent with Dr. Colasacco's view that the echocardiogram's quality was "good." Review of the echocardiogram leaves little doubt that its quality is poor.

Drs. Gopal, Vasey and Lazar[24] concluded that it was not medically reasonable to conclude that Gildersleeve had MMR, let alone SMR. Dr. Vasey felt that a legitimate question existed as to whether mitral regurgitation existed at all. He found:

> The sonographer planimetered outside the area of any true mitral regurgitant jet on five separate measurements, improperly including non-aliased, or low velocity, flow in the tracings. Additionally, only physiologic backflow is present, and not true mitral regurgitation.

Dr. Gopal was more generous:

> The jet area to compute the ratio included low velocity flow instead of only high velocity signals. All these factors will overestimate the RJA/LAA ratio. The true

[24] Dr. Lazar was withdrawn as an expert on Gildersleeve. However, his Affidavit was intended as his direct testimony. Counsel for Gildersleeve did not examine Dr. Lazar on his conclusion that it was not medically reasonable to find that Gildersleeve had MMR let alone SMR using CAS criteria. Dr. Lazar's conclusions in this regard are admissions. *See Sibinski v. Smith*, 206 N.J. Super. 349, 353-354 (App. Div. 1985).

> severity of mitral regurgitation is only mild in my estimation. The most accurate ratio of the ones shown in this study is 2.02/17.04 which does not fulfill the criteria for moderate mitral regurgitation.

Dr. Gopal accepted the tracing of RJA = 2.02 cm^2 and LAA = 17.4 cm^2 which computes to 11.6%. As to the aortic regurgitation claim both Dr. Gopal and Dr. Vasey find it to be unsupported. Dr. Gopal states that

> No consistent diastolic color jet was noted on either view or on pulsed wave Doppler examination. Excessive color gain settings in the parasternal view and choice of systolic frames rather than diastolic frames may have mistakenly led to a diagnosis of mild aortic regurgitation.

This devastating criticism is repeated by Dr. Vasey who finds no aortic regurgitation "visualized."

Dr. Colasacco, of course, disagrees and stands by his report. The Court need not discuss Dr. Colasacco's position in any detail because a fair review of the record demolishes his position. Dr. Colasacco's determination of SMR was roundedly rejected by three (3) experts. His conclusions about Gildersleeve's MAR have no scientific basis. Accordingly the Court finds that Wyeth has easily established that no reasonable physician could find Gildersleeve has either MMAR or MAR and Dr. Colasacco was acting in a medically unreasonable manner when he made these findings.

BB. ROBERT GORDON

Gordon relies on a June 29, 2002 echocardiogram performed by Cardiac Consultants of Chicago, Ltd. and a report of Dr. Richard Levinsky. Dr. Levinsky found Gordon had MAR using CAS criteria -- JH/LVOT = 13%.

The June 29, 2002 echocardiogram was reviewed by three (3) experts: Dr. Kaul, Dr. Gopal and Dr. H. Cohen. All three (3) physicians concluded that the echocardiogram was of diagnostic quality. Both Drs. Gopal and Kaul found there was no aortic regurgitation observable in the PLAX view, and Gordon's MAR finding resulted from measurements taken during systole -- the wrong cardiac cycle. Dr. Gopal stated that:

> No aortic regurgitation was noted on any view or by pulsed wave Doppler examination. The jet height/LVOT height ratio was measured during a systolic frame rather than a diastolic frame and was thus in an incorrect portion of the cardiac cycle.

Dr. Kaul concurred that the measurements alleged to support MAR were made in systole and added "[i]t is not medically reasonable to diagnose Mr. Gordon with FDA positive aortic regurgitation because no aortic regurgitation is seen in the PLAX view on this echocardiogram."

Dr. H. Cohen found otherwise. He re-examined the echocardiogram originally performed by his office and concluded that Gordon had a JH/LVOT = 18%. He noted that the frame supporting that finding (from 37:05:27) was taken in early diastole. Dr. H. Cohen advised the Court that his firm no longer had the original worksheets for this or his other patients seeking to opt-out here. No JH or LVOT measurements were provided and from the information before the Court it appears that Dr. H. Cohen erroneously reported the mitral regurgitation findings as aortic regurgitation.[25]

The Court has examined the echocardiogram and Dr. Kaul in his testimony specifically addressed the frame Dr. H. Cohen claims was taken in diastole. There is no doubt that the frame was taken in systole and it is medically impossible to diagnose aortic regurgitation in systole.[26] Accordingly, the Court finds that Wyeth

---

[25] The original report signed by D. Levinsky reported mitral regurgitation at 18% and aortic regurgitation at 13%. Dr. H. Cohen testified he copied the 18% from the original report.

> Q. --that there is a high LVOT of 18% [for Gordon]. That was copying the numbers from the original report, right?
> A. That's correct.

[26] The entire direct examination of Dr. Kaul on this patient is reproduced in this footnote. The testimony and the Court's review of the echocardiogram convince it that Dr. H. Cohen was both careless and wrong when he opined that Gordon had MAR.

> MS. PETERSEN: Gordon.
> Q. This is an aortic regurgitation case. Dr. Kaul, what is your opinion about the degree, if any, of aortic regurgitation seen in the parasternal long axis view on this echo?
> A. I didn't see any aortic regurgitation.
> Q. Let's look at the frame relied on by Dr. Cohen for his opinion that there's aortic regurgitation present. RG-1, which is Defense Exhibit 3283 with a time marker 37:05:27.
> * * * *
> Q. Dr. Kaul, could you describe any criticisms, if any, that you have of this measurement?

A. Yes, I'll go back to something I probably didn't stress the first time around. Again, was the same problem as last time, your Honor, which is high gain for both black and white and color. And I don't see any aortic regurgitation. In any case, this is a systolic frame.
Q. And, Dr. Kaul, is it ever medically reasonable to attempt to visualize aortic regurgitation during systole?
A. No, it is not.
JUDGE WALSH: How do you know this was in systole? Let's just make sure we're on the same ground here.
THE WITNESS: First of all, I did look at the rest of the tape when it was running. But even if we look at the EKG, it's on the top of the T wave.
JUDGE WALSH: Yes. And so, I mean, the electrical information usually proceeds to make mechanical movement. I guess that's why it's an approximation; right?
THE WITNESS: No, they occur simultaneously. The only difference is the EKG has a very good resolution while this resolution depends on the frames per second. So the EKG could be a thousand frames per second, let's say if it was in terms of frames, while this is going to be much less. So, you may be somewhere in the EKG, where you may be another plane on--
JUDGE WALSH: But there's always lags, color always lags on the EKG?
THE WITNESS: Yes, it does, it does.
JUDGE WALSH: I mean, you're telling me it's medically impossible for this to be in diastole?
THE WITNESS: Yes. If you see the running tape, it is not diastole.
JUDGE WALSH: Okay. I'm just --
THE WITNESS: Obviously, not basing it on one frame because you're right, on one frame you can't see anything. You have to look at the whole thing.
JUDGE WALSH: Okay.
Q. And we'll do that in just one moment. One other question about the cardiac cycle. Dr. Cohen states in his report that the anterior mitral valve leaflet has just opened on this frame, and that this is, therefore, diastole. Do you agree with him in that regard?
A. I don't know how he can say if it just opened or just closed. If you see a door opened, you know, you can't tell whether it just opened or closed. So I'll have to look at the videotape.
Q. Let's do that. FTI 6045, which is Defense Exhibit 3395.
A. So, again, this is the anterior wall and the posterior wall, and the aortic leaflets are here, and you can see that there is no aortic regurgitation. You can play this back and forth. Now they are coming back to choosing their place. Now, you know, they have captured — and they are going through each cardiac cycle and they don't find any regurgitation, one cycle, two cycles, three cycles, four cycles, and then you find some color and close it there and say this is regurgitation. You can see, going through each and every cycle, they're not finding any. If there was aortic regurgitation, it should be in every cycle unless there's something wrong with your beam. And then finally what they're doing, they're going to choose a frame that they like and call it aortic regurgitation.
Q. And I believe the frame we were looking at before was at 37:05:27.
MS. PETERSEN: So, when we get there, TJ, if you could just pause.
THE TECHNICIAN: un-huh.
A. So, we've gone through many EKG iterations here now, and there's never any regurgitation. And then they stop here and call that regurgitation.
Q. And viewing that in motion, could you confirm whether that was in systole or diastole?
A. Yeah, that is systole.

has established that no reasonable physician could find MAR based on review of this echocardiogram.

CC. CHERYL GREENE

Greene relies on a November 15, 2002 echocardiogram and a report by Dr. Jason Lazar. Dr. Lazar found Greene had MMAR using CAS criteria -- JH/LVOT = 25%.

The November 15, 2002 echocardiogram was reviewed by three (3) experts: Dr. Vasey, Dr. Gopal and Dr. Lazar. All three (3) physicians concluded that the echocardiogram was technically adequate. Both Dr. Gopal and Dr. Lazar concluded that Greene had MAR but not MMAR as originally assessed. Dr. Gopal put it this way:

> The aortic regurgitation jet noted on the parasternal long axis view, is brief. However, the aortic regurgitation jet in the apical view is a consistent diastolic jet and is definitely the same jet. The criteria as defined by the Court for jet height/LVOT height are just satisfied and qualify for mild aortic regurgitation but not for moderate aortic regurgitation as the report states (the frozen frame on the study shows measurement of the jet width too far away from the valve orifice after it begins to spread). Evidence for aortic regurgitation is also noted above the baseline on the spectral Doppler profile.

Dr. Lazar based his new conclusion that Greene had MAR on two (2) measurements which when averaged provided a ratio of .45/1.9 or 23.7% when expressed as a percentage. Dr. Lazar acknowledged that his measurement of Greene's jet height was debatable but adhered to his position that his measurements were medically reasonable.

Dr. Vasey disagreed, finding only trace regurgitation and also finding that any jet observed was not holodiastolic. In Dr. Vasey's words:

> Viewing multiple frames and loops in the parasternal long axis view, there is seen only subjectively trace aortic

---

Q. So, Dr. Kaul, would it be medically reasonable for a cardiologist to find FDA positive aortic regurgitation on this echo?
A. No.

> regurgitation. There is no holodiastolic jet of aortic regurgitation visualized in the parasternal long axis view. In fact, the frame rate is 18 frames per second and the aortic regurgitation is seen for only 3 frames in the parasternal long axis view - a total duration of 3/18 of a second, or .166 seconds, demonstrating that the aortic regurgitation is clearly not holodiastolic in the parasternal long axis view, which is consistent with trace aortic regurgitation. (see images, frames 23-28) Additionally, the EKG confirms in frame 28 that aortic regurgitation is no longer present in diastole.

While a credible argument that this jet is hot holodiastolic is supported by the evidence, the Court finds that Wyeth has failed to establish that no medically reasonable diagnosis of MAR could be based on this echocardiogram. Based on all the evidence, the Court concludes that Greene's claimed FDA Positive aortic regurgitation is medically debatable.

DD. YVONNE HARDNETT

Hardnett relies on a May 18, 2002 echocardiogram performed by Capital Heart Associates, P.C. and a report of Dr. Ramin Oskoui. Dr. Oskoui found that Hardnett had MMAR and SMR using CAS criteria -- JH/LVOT = 30%; RJA/LAA = 49%. Dr. Oskoui described the study as "technically good."

The May 18, 2002 echocardiogram was reviewed by three (3) experts: Dr. Kaul, Dr. Gopal and Dr. Lazar. All three (3) physicians found the echocardiogram to be technically adequate. Drs. Gopal, Kaul and Lazar found no indication of aortic regurgitation, let alone MMAR. Dr. Gopal reported that "[n]o consistent diastolic color flow jet was visible on color Doppler examination or on pulsed wave Doppler examination." She concluded that "[t]here is no evidence of aortic regurgitation." Dr. Kaul was just as emphatic. He observed that "[i]t is not medically reasonable to diagnose Ms. Hardnett with FDA positive aortic regurgitation because no aortic regurgitation is seen in the PLAX view on this echocardiogram." Dr. Kaul further observed that the aortic regurgitation findings may have been the result of measurements taken during systole. Dr. Lazar simply checked the box that it was not medically reasonable to conclude that Hardnett had any aortic regurgitation. As to the claim that the echocardiogram supported a SMR finding, Dr. Gopal was equally dismissive. She found:

> Only trace mitral regurgitation is present that corresponds to the closing volume and is not truly holosystolic. The jet area in the study is of the nonholosystolic portion and includes low velocity components and is therefore overestimated.

Dr. Kaul concurred.

Dr. Lazar claims that Hardnett has MMR but not SMR. He bases his conclusions on three (3) frames which he identified in his Echocardiogram Review and Assessment. But he concedes that the RJAs supporting the finding of SMR were significantly overtraced.

The Court has considered the testimony of all three (3) experts on this subject and has reviewed the echocardiogram. It is evident that the LAA used as the denominator here was foreshortened thereby incorrectly reducing its size and inflating the mitral regurgitation fraction. Moreover, the several RJAs identified here were significantly overtraced and do not appear to be holosystolic. The frames used in the tracings are in very early systole which is consistent with the judgments of Drs. Gopal and Kaul that the observed phenomenon is simply backflow.

The Court finds that Wyeth has satisfied its burden to show that it is not medically reasonable to find either MAR or MMR based on this echocardiogram. The RJA plainly was overtraced and the LAA foreshortened and the phenomenon was seen only in early systole at relatively low velocity, a telltale clue that this is a backflow, not a mitral regurgitant jet.[27]

---

[27] Drs. Gopal and Kaul sum up these points in their respective testimony. Dr. Gopal testified as follows:

> JUDGE WALSH: Let's pass on to Yvonne Hardnett. Could you comment on the methodology used, and here we have both mitral and aortic claims being made.
> THE WITNESS: Right. That's right. I felt that this was a technically adequate echocardiogram. There was a claim for a moderate mitral regurgitation. I didn't feel that the MR was moderate. Here we have a phenomenon of the closing volume, which is only a brief systolic jet. It's not a holosystolic jet the way the mitral regurgitation should be, and so that the jet area was really the nonholosystolic portion and included some low velocity components, and so I felt that the jet area that was shown on the echocardiogram was overestimated. So I didn't feel that there was the criteria for moderate MR.

Dr. Kaul testified to the same effect:

> Q. And, Dr. Kaul, if you could just explain to the Court any criticisms you may have of this tracing.

EE. DOROTHY JEKEL

Jekel relies on a December 28, 2002 echocardiogram and a report by Dr. Thomas I. Knox. Dr. Knox found that Jekel had "mildly severe AI (45-55%)" and MMR. No JH/LVOT or RJA/LAA information was provided in the report.

The December 28, 2002 echocardiogram was reviewed by three (3) experts: Dr. Chen, Dr. Gopal and Dr. Knox. Both Drs. Gopal and Chen found the echocardiogram was not conducted in a technically adequate manner such that reliable medical conclusions regarding the presence and severity of valvular regurgitation could be drawn from it. Dr. Gopal found that the

> [c]olor gain settings are excessively high in all views and speckling is very prominent outside the region of interest. In addition, the Nyquist settings are too low. The above

---

* * * *

A. Two things. First of all, the left atrium is badly for shortened. That means that if you look at the rest of the tape as we run it, you can see the left atrium is really larger than it really has been shown here, but this is all laminar flow where they are traced. The only --

JUDGE WALSH: Referring to the blue?

THE WITNESS: The blue is all laminar flow.

A. And they have, in fact, gone back and traced it right into the left ventricle, as you can see. The mitral valve ends here. So, the only part that's aliasing is this little part here.

JUDGE WALSH: That's the green?

THE WITNESS: Yes.

JUDGE WALSH: And it looks like orange?

THE WITNESS: Yes. Exactly, this part.

A. And this part is just the closing volume, and it's only seen in the frame.

JUDGE WALSH: Early systole?

THE WITNESS: Early systole.

Q. So, in your opinion, there's only closing volume on this echo?

A. That's correct.

Q. And on mitral valve regurgitation --

JUDGE WALSH: Let me ask one more question, if I could.

Doctor, in your experience, this so-called backflow or push-back from the valves, what velocity does it reach? Does it get up to 2 meters per second?

THE WITNESS: It can get up to 2 meters a second. And it also depends on the pressure in the left ventricle. So, if you have hypertension, for example, this closing volume can look like --

JUDGE WALSH: If there's a large pressure gradient --

THE WITNESS: That's correct.

JUDGE WALSH: --you can get a brush-back --

THE WITNESS: That's correct.

JUDGE WALSH: -- or a so-called puff that will briefly -- until the valve adjusts?

THE WITNESS: Exactly.

> factors can result in overestimation of regurgitation severity.

Dr. Chen was equally blunt, finding that

> [d]ue to a very Nyquist limit (41 cm/s) and extremely high color Doppler gain, it is not possible to make reliable conclusions about the presence or severity of regurgitation."

Even Dr. Knox conceded that this was a poor quality echocardiogram and that he would conduct another rather than use it to diagnose a patient.

> JUDGE WALSH: All right. Doctor, would you be good enough before we start cross-examination to read your material into the record and that is the narrative statement with respect to your analysis, reflected in PJ-3?
> THE WITNESS: I did not perform this study myself. I only interpreted it. I do agree that the overall technique is somewhat lacking in terms of specific views and gaining techniques. Nevertheless, by a parasternal long axis color and apical five chamber continuous wave Doppler, there is aortic insufficiency of at least a mild, if not mild-to-moderate degree. The mitral regurgitation, I now agree is not moderate, but mild in nature. There is no continuous wave of this, only pulse and Doppler -- I'm sorry, only pulse and color. These are, I agree, gained by a low Nyquist and high color gain. Given the echo's limitations, it is not as straightforward as other studies, but is not a normal study. It would be helpful if this person had another study to review. Signed by me, 10/5/04.
> JUDGE WALSH: What do you mean gaining?
> THE WITNESS: The gaining, you can sometimes change the way the picture looks by the amount of gain that's used on the ultrasound. It doesn't necessarily affect the overall signal-to-noise ratio but it can make things look brighter, so to speak, so that in terms of making specific measurements of the structures, the LV outflow track or where certain things are, it can be

> difficult depending upon which gain or compensation is used.
>
> * * * *
>
> CROSS-EXAMINATION BY MS. PETERSEN:
> Q. Dr. Knox, can I ask you to read the first question on you review and assessment form, the question under Part A, No. 1, just the question?
> A. "Was this echocardiogram conducted in a technically adequate matter [sic] such that reliable medical conclusions regarding the presence and severity of valvular regurgitation can be drawn from it?"
> Q. And you responded "no" to that question, isn't that right?
> A. Correct.
> Q. And that was on October 5, 2004?
> A. Yes.

The Court finds that Wyeth has satisfied its burden of demonstrating that this echocardiogram was not conducted in a technically adequate manner so that reliable medical conclusions could be drawn from it. Two (2) further comments are in order. Dr. Knox, after providing a report that Jekel did not have MMR, attempted to change his opinion in court. This Court finds that this effort should be ignored under the "sham affidavit rule" and for the reasons articulated in *Shelcusky v. Garjulio*, 172 N.J. 185 (2002). In any case, no reasonable medical conclusion could be made on this record that Jekel had MMR. Second, Dr. Gopal, after rejecting the technical quality of the echocardiogram, made a clinical judgment that Jekel has at least MAR. She found:

> Aortic regurgitation appears to be present but cannot be quantified reliably due to the technical limitations of the study with respect to color gain and Nyquist limits. However, simple visual inspection of the color jet indicates that the relatively lenient criteria of 10% (mild aortic regurgitation) or greater would probably be satisfied, not withstanding the concerns regarding study quality.

While Dr. Gopal, like Dr. Sherrid in Brown, is free to make a clinical judgment about Jekel's condition, the *Eligibility Standards Opinion* requires that these conclusions be reliable and reproducible. *Kemp ex rel Wright v. State*, 174

N.J. 412 (2002); *In re Paoli Railroad Yard PCB Litigation*, 35 F.3d 717 (3rd Cir. 1994); *see also Oddi v. Ford Motor Co.*, 234 F.3d 136, 145-146 (3rd Cir. 2000). By her own admission, Dr. Gopal's conclusion cannot be verified and quantified. As this Court has already determined, Wyeth bargained for this requirement when it entered into the CAS.

FF. SARAH LARSON

Larson relies on an August 21, 2002 echocardiogram performed by the University of Wisconsin Hospital & Clinics, Adult Echocardiography Laboratory and a report of Dr. Peter S. Rahko. Dr. Rahko found MMAR and MMR using CAS criteria -- JH/LVOT = 31%; RJA/LAA = 24%.

The August 21, 2002 echocardiogram was reviewed by four (4) experts. Dr. Chen, Dr. Gopal, Dr. Rahko and Dr. Lazar.[28] The three (3) testifying physicians found the echocardiogram to be technically adequate. Drs. Rahko and Gopal found Larson to have FDA Positive aortic regurgitation. Dr. Rahko adhered to his conclusion that MMAR was present. Upon remeasurement,[29] he found JH/LVOT of 31% and 26% on two (2) measurements. Dr. Gopal concurred in the conclusion that Larson was FDA Positive but believed that Larson had MAR. As to the mitral

[28] The plaintiff's counsel withdrew Dr. Lazar as an expert during the hearing. Accordingly, the Court's decision will be based on the testimony of the other three (3) experts.

[29] Dr. Rahko's testimony on that point is included in this footnote.

> Q. Doctor, in looking at your Chem 13, you have 5.36, I believe.
> A. Yeah, I'm just checking here right now. Yeah, the largest one we measured that I reported the .68. If you go to 5 minutes and 56 seconds into this study, that's where the .686 centimeter measurement comes from.
> Q. We're finding it right now, Doctor.
> A. Okay. And then the other thing I said if you wanted to take a little bit more conservative measurement of that one, since it may be, as we were talking about before, that was a little slightly off axis than the other one where I had the .55, I believe, is just before that at 5 minutes and 52 seconds.
> MR. RAMSAY: It's SLA-10, which is D-3198 at 5:54 is the measurement.
> THE WITNESS: Where the diameter is .555?
> MR. RAMSAY: Yes.
> MR. BERN: Yes.
> A. And then the clock -- the clock time I've got on my particular frame here is 5:52 that shows the color, and then the diameter measurement is at 5:54. That immediately follows it.
> Q. And both of the -- Dr. Rahko, both of the -- at 5?54 and at 5?56, both of those jets would be moderate aortic jets when measured?
> A. That's correct. The ratio I get was either 31 percent or 26 percent from those two different measurements.
> Q. And, again, these are done in accordance with the criteria that you've discussed on those points?
> A. Yes.

regurgitation claim only Dr. Rahko found Larson had MMR with an RJA/LAA ratio of 3.4 cm^2/14.5 cm^2 or 24%.

Only Dr. Chen found that Larson did not have at least MAR. He concluded that aortic regurgitation was present but the JH/LVOT only reached 6.53%. He criticized the study measurements, claiming they were not measured below the valve and the PLAX views were obtained at a lower window than was standard. Both Drs. Gopal and Chen disagreed that Larson had MMR. Dr. Gopal noted that the "[l]eft atrial area is underestimated and traced from a foreshortened apical view from a frame that is not end-systolic and therefore, the ratio is artificially increased." Dr. Chen concurred and observed that "[t]he RJA was overtraced beyond the jet edges. The LAA was undertraced and measured at an oblique angle. The mitral regurgitation is mild, at most."

Both Drs. Gopal and Chen concluded that the RJA/LAA showing mild mitral regurgitation measuring about 10%. Dr. Rahko agreed that there was some overtracing but believed that even taking that into account Larson should receive the MMR classification.

The Court finds that Wyeth has failed to demonstrate that this echocardiogram did not establish at least MAR. Dr. Rahko found MMAR and Dr. Gopal felt that MAR with a conservative JH/LVOT ratio of 16.7% was an appropriate finding. The Court, however, believes that Wyeth has established that Dr. Rahko's finding of MMR was not medically reasonable. Allowing for interreader variability and having reviewed this echocardiogram, the Court accepts Drs. Gopal and Chen's conclusions that the LAA was, in fact, foreshortened and therefore a finding of MMR based on this echocardiogram is medically unreasonable. (Dr. Rahko's 14.5 cm^2 v. Dr. Chen's 18.2 cm^2 cannot be explained by interreader variability.) This foreshortening (normally caused by the angle of the transducer to the left atrium) is what alters the calculus in favor of Wyeth's claim.

GG. BEVERLY PADRATZIK

Padratzik relies on an August 24, 2002 echocardiogram performed by Associates in Cardiology, Ltd. and an August 27, 2002 report by Dr. Roger A. Billhardt. Dr. Billhardt found that Padratzik had MMAR by CAS criteria -- JH/LVOT = 33%.

The August 24, 2002 echocardiogram was reviewed by three (3) experts. Dr. Chen, Dr. Ong and Dr. Billhardt. All three (3) physicians concluded that the echocardiogram was technically adequate though all three (3) found that no color was turned on in the PLAX views. The PLAX views in all other respects were available. Looking at the aortic regurgitation through the Apical long-axis (Apical 3 chamber), both Drs. Ong and Chen concluded that no significant aortic regurgitation was seen. Dr. Ong further noted that "the measurement was performed on a non-regurgitant jet. It is more consistent with physiologic flow within the LVOT." Dr. Chen concurred but was more direct. He found "[t]he purported AI 'jet' measured in systolic LVOT flow, and not true regurgitation."

Dr. Billhardt concluded otherwise but the Court puts little credibility in his conclusions because they lack a scientific basis. First, it is evident that Dr. Billhardt does not understand that the PLAX view, where available, is the required view.[30] Second, he erroneously states that the PLAX view is medically appropriate

---

[30] Dr. Billhardt's testimony on this subject is reproduced at length.

> [BY MR. MICHAEL]: Q. Okay. Now, Doctor, on your 2004 echocardio review, it says, Question: Was the parasternal long axis view available on this echocardiogram, and you've checked yes. Is that right.
> A. Yes.
> Q. Okay. Question: If yes, does the parasternal long axis view show FDA positive aortic regurgitation, jet height over LBOT [sic] greater than or equal to 10 percent by color flow Doppler, and you've checked no, is that correct?
> A. That's correct.
> Q. And in fact, color Doppler echocardiography wasn't turned on on this echocardiogram, right?
> A. That's what I was -- would assume as I put down no Doppler exam done on this view.
> Q. Okay. And on direct, you've speculated, was it, that because Ms. Padratzik was 200 pounds, that could be the reason?
> A. I didn't speculate at all as to why.
> Again, the understanding that I had was that we were following the criteria by Singh as for -- as to regurgitant lesions. And again, Singh does not indicate that the only place to measure it is in the parasternal long axis. If you read the criteria in Singh's paper, he says nothing about which axis to measure it by.
> Q. And that's what you were operating under, both when you did your original read and when you did this 2004 review, right?
> A. Correct.
> Q. Okay. So it's -- okay. So then sitting here today, you don't know why color flow Doppler was not attempted to be obtained in the parasternal long axis view, right?
> A. Correct. We could look at the tape and see if there is a reason it wasn't done.
> Q. Now, it is standard practice in general echocardiography to attempt to obtain color flow Doppler in the parasternal long axis view, right?

for detecting mitral regurgitation but is problematic when attempting to detect aortic regurgitation. Virtually all medical testimony and the learned treatises, of course, are contrary to his views.

The Court has reviewed the echocardiogram and accepts Dr. Chen's testimony verbatim as its findings on this matter:

> I have reviewed Dr. Billhardt's interpretation of Ms. Padratzik's echocardiogram and his finding concerning aortic regurgitation. As Dr. Billhardt admits, the technician's measurement of aortic regurgitation was made in an apical view. I have re-reviewed the echocardiogram and confirmed that although grayscale images--black and white images of the heart structures without color Doppler--appear during the parasternal long-axis view, color Doppler imaging was not utilized in that view. Standard echocardiography requires a technician to attempt to visualize aortic regurgitation by color Doppler in the parasternal long-axis view. Utilization of the apical long axis view for the quantification of aortic regurgitation (which Dr. Billhardt has mistakenly referred to as the apical four-chamber view) is inappropriate.
>
> Moreover, I have reconfirmed that the flow measured by the technician and adopted by Dr. Billhardt as an aortic regurgitant jet in the apical long axis view is low velocity flow (as evidenced by red color) and not an aortic

---

A: Particularly if you're looking for mitral regurgitation, that's a good view for it, but aortic insufficiency may be very difficult to see in that view.

Dr. Billhardt reiterates his fundamental misunderstanding of the CAS criteria later in his testimony.

And again, although we're talking about the parasternal long axis view, talking about the jet height, the apical four-chamber view showed a larger jet, and that was the one that I used to indicate how much aortic insufficiency there was.

Again, my understanding was that there is no specific area by the Singh criteria where aortic insufficiency is to be measured, whether it's parasternal long axis, whether it's apical two-chamber or apical four-chamber, and the apical four-chamber was the measurement given.

> regurgitant jet (which is typically high-velocity flow and should appear in mosaic color in the apical views since the transducer or ultrasound beam is parallel to the jet direction). The true jet in the apical view is tiny, too small to measure, and therefore trace.

Accordingly, the Court finds that Wyeth has easily satisfied its burden to show that no reasonable medical conclusion that the echocardiogram here shows MMAR. What is clear is that no reasonable conclusion that Padratzik has MAR can be drawn from review of this echocardiogram.

HH. CYNTHIA READ

Read relies on a December 10, 2002 echocardiogram and report by Dr. Jason Lazar. Dr. Lazar found Read had MAR by CAS criteria -- JH/LVOT = 23%.

The December 10, 2002 echocardiogram was reviewed by three (3) experts: Dr. Chen, Dr. Ong and Dr. Lazar. Dr. Ong found that the echocardiogram was not performed in a technically adequate manner because the "high gain settings include color artifact." Dr. Chen concurred that "the color Doppler gain was set slightly high" but found the echocardiogram could be interpreted. Dr. Lazar simply indicated that the echocardiogram was technically adequate. The Court has reviewed the echocardiogram and finds it to be of marginal quality.

As to the claim that that this echocardiogram establishes Read's MAR status, Dr. Ong emphatically disagreed, finding that "[t]he color jet itself is too small to be consistent with mild aortic regurgitation. It is not possible to provide an accurate measurement as is. Increasing the gain setting artificially increased the size of the jet, causing an over-estimation of the aortic regurgitation severity." Dr. Chen concurred and found serious technical deficiencies as to the timing of the purported MAR measurements.

> There is no aortic regurgitation visualized by color Doppler, pulse wave or continuous Doppler. Two of the AR "jets" selected are measured in systole, and therefore, are not true regurgitation. The other selected AR "jet" is random low velocity color, or artifact, and not true aortic regurgitation.

Dr. Lazar concludes otherwise and reported MAR as a result of his October 2, 2004 review. However, he did so based on frames taken in the apical view. The JH/LVOT he computed during his October 2, 2004 review, however, dropped from 23% to 15% (JH of .3 cm; LVOT of 2 cm). On cross-examination, he conceded that the high gain on the echocardiogram makes interpretation of this frame difficult.[31]

The Court has reviewed the echocardiogram and has considered the detailed testimony of Dr. Chen on Dr. Lazar's conclusions. The Court believes that no reasonable medical conclusions that Read has MAR can be drawn from the information pointed to by Dr. Lazar. It adopts Dr. Chen's observations in his Reply Affidavit as its own.

> I have reviewed the affidavit of Dr. Lazar in this case. Dr. Lazar claimed that on frame 12, the EKG tracing shows diastole. He stated that the color is yellow which is not on the color bar and therefore cannot be "low velocity." He also claimed that frame #41 shows AI by continuous wave Doppler.
>
> I re-reviewed the echocardiogram. I noted that the machinery settings are not what I would like to see for

[31] The cross-examination on Dr. Lazar is set out in this footnote.

MR. WHEELER: Your Honor, I believe we were with Cynthia Read.

* * * *

Q. Dr. Lazar, am I correct that this is a study that you have interpreted twice on two separate occasions?
A. I believe so.
Q. And I believe you testified earlier that you believe the study demonstrates mild aortic regurgitation?
A. Yes.
Q. You didn't give us a time stamp, but I believe we looked at a Dicom image, Page 12 of 59; correct? Is that a yes? I'm sorry, the reporter can't hear you.
A. Yes, I believe so. I don't recall the exact time stamp.
Q. I apologize.
If we could, let's look at Dicom Page 12 of 59 quickly. Is it a still?
Do you agree with me, Doctor, that that image clearly shows an excessive gain that would obscure my accurate review of a regurgitant jet?
A. I believe the gain is excessive.
Q. Do you believe because of that excessive gain, it would prohibit a physician from reaching a reasonable medical conclusion as to the degree of aortic insufficiency?
A. Taken in context with other views, it may or may not. I would not rely solely upon this view in all honesty.

my routine clinical practice but the study is interpretable with limitations. The color Doppler gain is set high, as evidenced by random color speckles with a "firework" appearance in the parasternal long-axis views. In addition, the Nyquist limit of 51 cm/s is at the lower range of acceptable Nyquist velocity settings, which exacerbates the problems caused by the high gain setting. Despite the technical limitations, I did not find any evidence of aortic regurgitation by color Doppler or continuous wave Doppler.

I carefully examined Dr. Lazar's claims and the original measurements by the technician. The claimed "aortic regurgitant jets" were measured in 3 frames.

a) "AR" jet measured on frame #9 on the CD in DICOM format, with time stamp of 1:32:42, is not a real AR jet and is instead low velocity random flow or color as evidenced by red color. Normally this low velocity flow or random color will not appear in LVOT but it is visible in this case because of a combination of high color Doppler gain and relatively lower range of Nyquist limit.

b) "AR" jet measured on frame #11, with time stamp of 19:33:36, is just before end-systole as evidenced by the fact that the timing bar on the EKG tracing is located at the down-slope of the T-wave, just before the end of the T-wave, and therefore is not a true AR jet. The end of the T-wave is usually considered end-systole.

c) "AR" jet measured on frame #12 with time stamp of 19:33:54 is at the end the T-wave, which is either at the end-systole or at the transitional period of end-systole and early diastole, during aortic valve closure or just a few mini-seconds after the aortic closure (isovolumic relaxation period).

There were no corresponding cine-loop real-time images to examine whether the color on the frame that was measured lasts throughout all of or throughout most of

> diastole to determine whether the color is truly an AR jet. Aortic regurgitation is usually holodiastolic and a true AR jet should be seen through at least most parts of diastole, if not throughout the entire diastole - that is from isovolumic relaxation to early rapid filling phase, mid phase of diastasis and late phase diastole.
>
> To determine the timing of the random color purported to be "AR," I reviewed all recorded cine-loop real-time images frame by frame and found a frame that has a similar appearance of color in the LVOT in the same vicinity of the aortic valve as the one on frame #12 (time stamp: 19:35:54) measured by the technician and adopted by Dr. Lazar for AR. The frame is frame #6 with the time stamp of 19:32:33. The color in the LVOT only appears in that single frame and is not present in the subsequent diastolic frames (a total of about 10 frames), which is indicative of random flow or color artifact during the transitional period of end-systole and early diastole, secondary to high color Doppler gain.
>
> Finally, there is no aortic regurgitant velocity signal on frame #41 on which Dr. Lazar claimed to have shown aortic regurgitation by continuous wave Doppler.

Accordingly, the Court finds that Wyeth has established that no reasonable medical conclusion that Read has MAR can be drawn from this echocardiogram.

II. ANGELA REYNOLDS

Reynolds relies on a June 29, 2002 echocardiogram performed by the Sutherland Clinic and a report by Dr. Bela B. Hackman. Dr. Hackman found Reynolds had "trivial aortic regurgitation" but then observed that Reynolds had MAR using CAS criteria -- JH/LVOT = 15%. No JH or LVOT measurements are provided in the study report nor is there any comment on the quality of the echocardiogram.

The June 29, 2002 echocardiogram was reviewed by three (3) experts: Dr. Chen, Dr. Ong and Dr. Lazar. Both Drs. Ong and Chen found that the echocardiogram was not conducted in a technically adequate manner such that

reliable medical conclusions regarding the presence and severity of valvular regurgitation could be drawn. Dr. Ong observed that "[t]he color Doppler gain settings changed throughout the study. The measurements were made during inappropriately high gain settings, which includes color artifact within those borders, thus inflating the height of the aortic regurgitant jet." Dr. Chen concurred and complained that in addition to the inappropriate gain settings, the Nyquist limit was set too low in the apical views.

> The color Doppler gain varied throughout the study. When the gain level was appropriate, only a small (less than 10%) aortic regurgitant jet is visualized. However, when the gain was set too high, it was impossible to make a reliable assessment of regurgitation. Additionally, the Nyquist limit was set too low (48 cm/s) in the apical views.

Even given these technical limitations which tend to inflate any regurgitation findings, both Drs. Ong and Chen concluded that any regurgitation observed was well below the 10% cutoff.

Dr. Lazar concludes otherwise. His October 4, 2002 report makes no mention of the technical limits of this study finding that "Nyquist and gain are fine." He computes a JH/LVOT ratio of 14.3% (JH - .3 cm; LVOT = 2.1 cm). Dr. Lazar conceded that the phenomenon he described as aortic regurgitation was not holodiastolic at least in the PLAX views though he contended it was present through many frames.[32]

---

[32] Dr. Lazar's full cross-examination on Reynolds is set out in this footnote.

> [BY MR. WHEELER]: I represent to you, Doctor, that other cardiologists who have reviewed this study have made comment upon the gain being too high.
> Do you agree or disagree with that proposition?
> A. It's a bit high, I agree.
> Q. Do you again, agree that the elevation of the gain in this study would obscure one's ability to accurately measure whether or not someone has an aortic regurgitant jet in the PLAX view that meets FDA criteria?
> A. I believe that gain has to be taken into the context of the total interpretation.
> Q. Wouldn't you agree though, Dr. Lazar, if we're trying to be scientifically accurate, you would want to study that's technically adequate in order to make an accurate evaluation?
> A. Can you repeat the question?
> Q. If you want to be scientifically accurate in an interpretation of a study, it needs to be technically adequate and sufficient on the frame, correct, that is, the study?
> A. If one felt that one could be scientifically accurate, then the answer is yes.

The Court has reviewed the echocardiogram and has considered the testimony of the experts. It concludes that Wyeth has established that this echocardiogram was not performed in a technically adequate way so that reliable conclusions could be obtained. It completely rejects Dr. Lazar's testimony that the Nyquist limit and gain settings "are fine" and observes that he contradicted this statement during cross-examination. In making these findings, the Court adopts Dr. Chen's comments on Dr. Lazar's findings as its own.

Q. And you agree the gain in this study is high?
A. The gain is high.
Q. You identified for us yesterday, Dr. Lazar, a couple of images that you believe demonstrated an aortic regurgitant jet.
MR. WHEELER: The record will reflect I believe, your Honor, there were multiple cycles that is we went through. I don't intend to do that again for the sake of brevity.
Q. But without prejudicing my client's interest, let me ask you this question, Dr. Lazar.
As we went through those images yesterday, did you find any sustained aortic regurgitant jet through a diastolic cycle?
A. In the images we went through yesterday, for measurement purposes, I don't believe so. In other images, the answer is yes. Image 755, which is actually a 5 chamber view, Image 849, which is continuous wave, so --
Q. My question is this, in a PLAX view which is available in color in this study, notwithstanding the high gain, did you find any regurgitant jet in the images we went through yesterday that you found to be sustained to the point of being holosystolic?
A. I believe they took up most diastole but were not holosystolic.
Q. Holodiastolic?
A. Holodiastolic, pardon me.
Q. Let's look at one quickly, Doctor, if we might in real-time, 6:31:29, I believe is the image you identified for us yesterday in the parasternal view.
Doctor, are we looking at the correct image here, 6 -- is that 31:29?
MR. LOEBBAKA: 6:31 --
MR. WHEELER: All right. Thank you.
Q. That's the image we looked at yesterday. Do you see a regurgitant jet on this image?
A. No, I'm not sure.
Q. Move forward one frame. Do you see a jet now?
A. Yes.
Q. Move forward another frame. Do you still see a jet?
A. Yes.
Q. Another frame. What about now?
A. Yes.
Q. Where, Doctor?
A. That greenish emanating from the valve, very slight, would you like me to point?
Q. For the record, that would be pencil thin?
A. Yes.
Q. Next frame. Do you still see a jet?
A. I can't comment on this frame. I see a lot of noise.

> I have reviewed Dr. Lazar's affidavit in this case, asserting measurements of JH/LVOT - 0.3/2.1 (14%) at time stamps 633 and 660, and stating that the "nyquist and gain are fine." I disagree with Dr. Lazar first of all concerning the statement about the machine settings. As I stated in my original affidavit, the color Doppler gain varied through the study, but was often far too high to make a reliable assessment of the severity of regurgitation. Again, as I stated earlier, when the gain is at an acceptable level in the PLAX view, the JH/LVOT is less than 10%.
>
> At both of the time stamps cited by Dr. Lazar for his measurements, the gain is set too high, so measurements of the severity of AR there are not medically reasonable. In addition, according to Weyman's textbook, an aortic regurgitant jet must be measured at its narrowest point, just below the valve. Therefore it is imperative to have an adequate visualization of the valve structure. However, at frame 660:29, the aortic valve structure cannot be adequately visualized, so that it is uncertain where the jet should be measured. Finally, at frame 633, I do not see any clearly visible aortic regurgitation which could have been measured.

JJ. LYNETTE RICKMAN

Rickman relies on an April 25, 2002 echocardiogram and a report of Dr. Curtis Burnett. Dr. Burnett found that Rickman had MAR using CAS criteria -- JH/LVOT = 21%. Apparently, there were other ratios calculated by the technician which Dr. Burnett rejected finding "[t]he higher ratios are artifactual."

The April 25, 2002 echocardiogram was reviewed by three (3) experts: Dr. Chen, Dr. Ong and Dr. Lazar. Both Drs. Ong and Chen found no evidence of aortic regurgitation and both found that the phenomenon observed was either "residual systolic flow" or was measured at end systole which, in the words of Dr. Chen, "may not be true regurgitation."

Dr. Lazar disagreed, finding that Rickman had MAR with a JH/LVOT of .3/1.8 = 16.7%. Dr. Lazar conceded that he did not know whether the alleged jet

was holodiastolic in the PLAX view. He claimed that the jet was holodiastolic in the Apical 5 chamber view (an unapproved view):

> Q. Let's move forward then to the next study then, Doctor, Lynette Rickman.
>
> You testified, I believe, today as opposed to yesterday, that your review of the April 2002 study reflects mild aortic insufficiency for this plaintiff; correct?
>
> A. Yes.
>
> Q. You relied upon time stamp 1:14:41:09 which I believe we captured as LR-2, Exhibit D-3204?
>
> A. Yes.
>
> Q. Is that is?
>
> A. Yes.
>
> Q. Doctor, is it your testimony that that particular image is a turbulent regurgitant jet based upon that color map?
>
> A. Yes.
>
> Q. Do you know whether or not this image, if we look at it in real-time, is holodiastolic?
>
> A. No.
>
> Q. You don't know?
>
> A. No.
>
> Q. Let's move forward then to the next plaintiff.
>
> A. But there's a holodiastolic image on an apical 5 chamber view at 1:19:58.
>
> Q. I'm interested and I believe the Court is interested in the PLAX view, Doctor. is there one in the PLAX view that you can identify for us, and, if so, I want you to identify it for us.
>
> A. I'm not sure.

Dr. Chen's testimony on Rickman best reflects the Court's conclusion that any jet to qualify as MAR must be holodiastolic. Dr. Chen observes that the phenomenon observed at frame 1:14:41:9 is not.

> I have reviewed the affidavit of Dr. Lazar in this case, in which he asserts JH/LVOT measurements of 0.3/1.8 (which he calculates at 15%, but is 16.7%) at frame 1:14:41:9. I have re-reviewed this study, and that frame

> in particular. I find that in that frame, there is something that could be a jet, but it lasts only one of six to eight frames in diastole (at 18 frames per second), and is very small. Due to the fact that it lasts only one frame, this should not be measured.
>
> In most real-time images, I saw no consistent regurgitant flow in the LVOT. In some real-time images, there are occasionally some blue dots in the LVOT, which may be suspicious for a tiny AR jet, but which last only a single frame in diastole, which is not long enough to be real aortic regurgitation. For confirmation, I looked at spectral Doppler and saw that there was no AR signal on spectral Doppler. Thus, it is still my opinion that there is no consistent evidence of FDA Positive AR on this study.

The Court finds that Wyeth has established that no reasonable medical conclusion that Rickman has MAR could be drawn from review of this echocardiogram.

KK. JOYCE RINGO

Ringo relies on a June 29, 2002 echocardiogram performed by Cardiac Consultants of Chicago, Ltd. and a report of Dr. Richard Levinsky. Dr. Levinsky found Ringo had MAR using CAS criteria -- JH/LVOT = 11%.

The June 29, 2002 echocardiogram was examined by three (3) experts: Dr. Chen, Dr. Ong and Dr. H. Cohen. Both Drs. Ong and Chen found the echocardiogram study to be "technically limited" because of the high gain. Dr. Ong believed that the echocardiogram was not conducted in a technically adequate manner such that reliable medical conclusions regarding the presence and severity of valvular regurgitation could be drawn from it. Dr. Chen, though, pointing out the study's limitations believed one could interpret it. Both Drs. Ong and Chen examined the echocardiogram and neither found evidence of aortic regurgitation. Dr. Ong observed:

> The poor quality of the echocardiogram did not allow accurate identification of the borders of the LVOT. No aortic regurgitation was seen that allowed a true measurement of the JH. The jets that were present are

> due to the high color gain setting. In reviewing the supplemental eligibility challenge dated 10/10/04 (Dr. H. Cohen's report), there was no identifiable aortic regurgitation jet in frame 1:08:50:03.

Dr. Chen concurred finding that "no aortic regurgitation is visualized on the echocardiogram" in real-time.

Dr. H. Cohen found MAR of 11% but noted that the "original worksheet [is] not available." He reported that aortic regurgitation is present at frame 1:08:50:63. But it turned out that he did not remeasure the JH/LVOT ratio and says he found only one (1) frame in the PLAX view which indicated any aortic regurgitation which he reported. While Dr. H. Cohen attempted to introduce apical views which he claimed supported his view that aortic regurgitation was present, the Court will disregard the material for two (2) reasons.[33] First, the PLAX view was available.

---

[33] Dr. H. Cohen's testimony on this subject is set out in this footnote.

> Q. Okay. Turning to Joyce Ringo, you talked about the June 29, 2002 echocardiogram of Ms. Ringo on direct, right?
> A. Yes.
> Q. And you believe that Ms. Ringo had FDA positive aortic regurgitation, right?
> A. Well, that's what we saw originally.
> Q. Okay. Looking at your review, under the box, did you conduct measurements on this echocardiogram?
> A. You mean on the review?
> Q. On your 2004 review.
> A. No. There was no way to do measurements.
> Q. Okay. And explain what you mean by that.
> A. I didn't have a program that would allow me to do that.
> Q. Okay. So you didn't actually during your 2004 review of the echocardiogram, perform measurements, did you?
> A. That's correct.
> Q. Now, on these disks, the digital disks, no measurements by the technicians appear on the disks, do they?
> A. That's correct.
> Q. And not that -- we're not just talking about Joyce Ringo now, we're talking about for all the plaintiffs, you couldn't actually do a measurement, right?
> A. That's correct.
> MR. MICHAEL: Okay. So for Joyce Ringo -- and this is Defendant's Exhibit 3005, we're still talking about. If we could put up FTI 1244.38 and switch, go to the bottom.
> BY MR. MICHAEL: Q. Doctor, at the bottom there, where it says, Original work sheet not available --
> A. Right.
> Q. -- what does that mean?
> A. That means that the measurements that we had -- we had work sheets when we originally did the tapes, and the numbers were on those work sheets. But I

didn't have the numbers, so I looked at it and said that it looks like it's about right.
Q. Okay.
A. And I did not -- I could not do new measurements. I did find with reference to aortic regurgitation, although it wasn't parasternal, this is a -- I don't know if this is in color or not, but
Q. Actually --
A. -- she had severe aortic regurgitation, but it was on the four-chamber view -- I'm sorry, the three-chamber view.
Q. And let's switch back because the video was not on the doctor at that point. He was referring to a still frame he has in his hand that is not marked.
A. Yes. This is something I found last night.
Q. Okay.
MR. MICHAEL: I'm going to --
BY THE WITNESS: A. On the three-chamber view.
MR. MICHAEL: I'm going to move to strike the portion concerning that is not responsive to the question.
BY MR. MICHAEL: Q. And Doctor, it appears that you pulled some frames last night?
A. I tried to pull some frames.
Q. Okay.
A. I pulled some.
Q. I'm going to be asking you questions mostly about what was actually in your 2004 report, so I'm not going to worry about those frames.
A. So you wouldn't be interested in what's actually on these I guess. Okay.
Q. Now, Doctor, on your report, now, we jut saw it said 11 percent jet height LVOTH, right?
A. Yes, but I took that number because that was what was on the original.
Q. Okay. So you didn't in 2004 go back and verify that that 11 percent was 11 percent and not 8 percent or 14 percent, right?
A. Yes. I h ad no way to do it, but as I said, I think it probably was much higher than that because on the three-chamber view, there was such severe aortic regurgitation.
Q. Okay. But you understand that the parasternal long axis view is available -- if available, is the view to be used for aortic regurgitation, right?
A. If you can see it on that -- you know, each patient is different, and each patient, there are some views that you can see. The parasternal sometimes is impossible or difficult, and the apical view is the only one that you can find on that patient. I mean those are the realities of doing echos on actual patients.
Q. Okay. Now, Doctor, on your 2004 review, you wrote down Frame 1:08:53:03 as showing aortic regurgitation, is that correct?
A. Let's see. That's what I wrote.
Q. And that's the only frame that you wrote down, right?
A. Yes. That was the only one that I could find when I reviewed it.
Q. And sitting here --
A. You know, because I originally didn't indicate the patient had mitral regurge of significance. I said no on that, but she actually did have it, and that is I have a frame here that shows it.
Q. Doctor, I'm going to ask you to really try and just answer the questions --
A. Oh, I'm sorry.
Q. -- that I'm asking.
And on the aortic regurgitation frame that you cited,, that frame is from an apical view, is that right?
A. Yes.

Second, Dr. H. Cohen did not follow the procedures previously identified for reporting his findings in advance of cross-examination. None of this information was disclosed to Wyeth as required by the protocols in effect here.

The Court finds that Wyeth has established that no medically reasonable conclusion could be drawn from this echocardiogram that Ringo had MAR.

LL. WILLIAM ROACH

Roach relies on an echocardiogram (later identified as taken on July 24, 2002) and an undated report by Dr. James Colasacco. Dr. Colasacco found Roach had MAR using CAS criteria -- JH/LVOT = 19%. The echocardiogram was described as "good quality."

The July 24, 2002 echocardiogram was examined by three (3) experts: Dr. Chen, Dr. Ong and Dr. Colasacco. Dr. Ong found the echocardiogram was not conducted in a technically adequate manner such that reliable medical conclusions regarding the presence and severity of valvular regurgitation could be drawn from it. Dr. Chen found that the echocardiogram could be interpreted but showed no aortic regurgitation. Moreover, according to Dr. Chen, "the AR jets measured were not aortic regurgitation, but rather systolic flow...."

Dr. Colasacco found Roach had MAR but initially provided virtually no other information from which a factfinder could assess the solidity of that opinion. In his supplemental Affidavit, he indicated that frame #13 (15:11:07) and frame #14 (15:11:55) demonstrated a freeze-frame and real-time view of Roach's aortic regurgitation. Dr. Colasacco testified that aortic regurgitation was confirmed by pulse and continuous wave Doppler. Dr. Colasacco conceded that the gain setting was high but he believed he could still find that Roach had MAR on the basis of the echocardiogram.[34]

Q. And you checked on your report that the parasternal long axis view was available for Ms. Ringo, right?
A. Well, I marked it because that's what we originally saw. Actually, I couldn't find it.

[34] Dr. Colasacco's cross-examination shows that color artifact was present on frame #14 due to the high gain.

[BY MS. PETERSON] Q. If we could look at the DICOM, which is Defense Exhibit 3074, and I believe it's Page 14.
JUDGE WALSH: Okay. This is the real-time.
Q. Dr. Colasacco, this is the loop you're relying on for your opinion that there's mild aortic regurgitation on this echo?
A. That is one of them, yes.
JUDGE WALSH: This is another -- I mean, look at the gain on this, Doctor.

Dr. Chen criticized Dr. Colasacco's position finding no support for his opinion. He noted that:

> I re-reviewed the echocardiogram recorded on a CD in DICOM format and found no definite evidence of the presence of aortic regurgitation by color Doppler or CW Doppler. The "aortic regurgitation jet" measured by the technician was not an aortic regurgitant jet. I replayed all available real-time cine-loop images in the parasternal views frame by frame and found a frame of a similar color appearance in the LVOT in the vicinity of the aortic valve (time stamp 15:12:23). The color appearance in the LVOT mimics a tiny aortic regurgitant jet, but is only visualized in a single frame at the end-systole or in the transitional period of end-systole and early diastole (isovolumic relaxation period) and is not seen during [the] early, mid or late diastole phase. An aortic regurgitant jet should be holodiastolic and visualized at

---

It's all through the tissue, both on the left and right axis, true?
THE WITNESS: That was not anything that I argued. I agreed -- based on the gain, based on the Nyquist limits, based on the patient's body and size --
JUDGE WALSH: This is another 13.5 centimeter probe, so it's not a terribly deep probe.
THE WITNESS: I could also ask would it be okay to ask to show Frames 10 and 11.
JUDGE WALSH: Show him Frames 10 and 11.
Q. Before we move on to 10 and 11, if I could just ask you a couple of questions about Page 14.
On the bottom of the colored area, there's some what appears to be aliasing speckling. Is it your opinion that that's artifact due to high gain?
A. It could be, yes.
Q. On the top colored portion of the echocardiogram, again, there's speckling present?
A. Right. That's also -- that's possibly --
JUDGE WALSH: It's not possibly, that's certainly true. It's right in the middle of the tissue.
Q. And again, that's likely due to artifact from high gain settings?
A. That's true.
Q. And in the middle third of this echocardiogram there is similarly speckling as there is on the top and bottom thirds?
A. Correct.
Q. And you don't believe that could be speckling due to high gain?
A. I don't.
JUDGE WALSH: How can you tell?
THE WITNESS: The question I'm asked is were they the best settings you had, the best views, if I think that there's mild aortic insufficiency, and the answer is yes.

> least in most of diastole if not the entire diastole on color Doppler.[35]
> There are no aortic regurgitant signals on the CW Doppler recording either, which further indicates the absence of aortic regurgitation. Therefore, the claimed AR jet is not a real AR jet. No aortic regurgitation is visualized in the parasternal view.

The Court has considered the echocardiogram and the testimony of the experts. It finds that Wyeth has established that no medically reasonable conclusion that Roach has MAR can be drawn from review of this echocardiogram.

---

[35] Dr. Chen also commented on the poor technical quality of this study during his testimony:

> [BY MR. AGNESHWAR] Q: On Roach, yes. What view are we seeing here?
> A. Parasternal long axis view.
> Q. Is there anything resembling an AI jet here?
> A. No, no.
> Q. Do you want to just go frame by frame and show?
> A. Yeah, I can. Just tell the judge what you're seeing.
> JUDGE WALSH: Dr. -- let -- before we do that, I mean am I wrong or is the gain basically putting random color in the tissue?
> A. A little bit too high gain you're right.
> JUDGE WALSH: A little too high?
> THE WITNESS: Uh-huh, and also the problem with it, see, in clinical setting we don't see it Nyquist limit to 51, and if you set Nyquist limit lower, the gain automatically becomes high, and also exaggerated problem with high gain because it becomes aliased too, in normal flow. So therefore, we now use in the 60s, 70s because it will cause artifact. That's why people who read it don't have experience thinking it's aortic regurge. That's because the normal flow aliased, because the Nyquist limit is so low. And if you have any increased gain, you just -- things will get worse.
> JUDGE WALSH: Let me ask you this: This is in the parasternal long axis view, right?
> THE WITNESS: Long axis, uh-huh.
> JUDGE WALSH: Do you have the same exaggeration with the size of the jet that you have when you're looking in the apical view?
> THE WITNESS: The same thing, yeah, I actually -- because I -- you know, I've been in this area for research since '90s -- early 90s, late '80s so actually I have a lot of example of it, so you can see you have the same acceleration, yes.
> Q. Go ahead. Go frame by frame just very quickly and tell me, Dr. Chen, do we see anything that looks anything like an AI jet?
> A. There's no AI jet.
> Q. Would any competent echocardiographer say that this is AI?
> A. No.
> Q. That's all I have on Roach.
> A. It's just artifact one frame and, like I say, because the combination of low Nyquist limit and a little bit too high gain, you can see there's no AI.
> Q. But even with the high gain settings, you didn't see any AI?
> A. Yeah.

MM. LUPE ROBLES

Robles relies on a May 22, 2002 echocardiogram performed by Cardiovascular Consulting, Inc. and a report of Dr. Michel Sellers. Dr. Sellers found that Robles has MMAR and MMR using CAS criteria -- JH/LVOT = 48%; RJA/LAA = 27%.

The May 22, 2002 echocardiogram was reviewed by three (3) experts: Dr. Vasey, Dr. Ong and Dr. Lazar. Both Drs. Ong and Vasey noted the poor quality of the echocardiogram due to the high gain settings. Dr. Ong believed that the gain settings caused this echocardiogram not to be conducted in a technically adequate manner such that reliable medical conclusions could be drawn. Dr. Vasey believed that despite the poor quality, the echocardiogram could be interpreted. All three (3) physicians concluded that Robles did not have MMR. Rather, the phenomenon observed was backflow.

Drs. Ong and Vasey concluded that no MAR finding could be made because the gain setting creates artifact. Dr. Vasey further concluded that no aortic regurgitation was present in any case:

> The purported aortic regurgitation is trace in severity in the parasternal long axis view. There is no high velocity, holodiastolic jet on the echocardiogram. The trace AI visualized is laminar blue, while the measured purported aortic regurgitation is red and appears to be measured in systole. The second measurement of purported aortic regurgitation assesses an almost circular area of blue flow that is not representative of true aortic regurgitation and also appears to be measured in systole. The sub-optimal quality of the scrolling EKG and the inability to visualize the position of the mitral valve with certainty, making it difficult to reliably assess the timing of the measures of the purported aortic regurgitation with certainty.

Dr. Lazar found otherwise. He observed a JH of .3 cm and an LVOT of 1.8 cm resulting in a percentage of 16.7% (Dr. Lazar erroneously reported 15%). Dr. Lazar found the gain setting to be appropriate for the medical conclusion he drew.

The Court rejects Dr. Lazar's testimony that the gain setting is appropriate. Plainly, the speckling is characteristic of a high gain setting. Moreover, the Court accepts Dr. Vasey's conclusion that Dr. Lazar's measurements supporting aortic regurgitation were made in systole -- a medical impossibility. Dr. Vasey's testimony on this point is pertinent.

> [BY MR. WINTERS]: Q. Doctor, this is Exhibit 3356 for the record, which the plaintiffs have offered as showing aortic regurgitation, FDA-positive. Can you comment on the findings in this study?
> A. The Nyquist limit is appropriate at 76, which we see over there. I think this is the parasternal long axis view and again, looking at that left ventricular outflow tract here, I really don't see an organized jet of aortic insufficiency.
> Q. What part of the cardiac cycle are we in?
> A. It's very hard to tell from this strong EKG. If you assume that it's starting over here, you're in systole.
> Q. And if we can pull up LOR-3, which is Exhibit 3358 and again this has been offered by the plaintiff as an example of aortic regurgitation. Can you comment on this part of the study?
> A. Well, I think, again, we don't see any organized jet of mosaic or high velocity flow going in this direction. In terms of any organized jet, we look at the timing in the cardiac cycle and we now see that it's right at the end of the T-wave which is really in systole and again, I just don't think that there's any AI there or aortic insufficiency.
> Q. Should AI be measured in systole?
> A. No, AI is a purely diastolic phenomenon which should be measured typically later in diastole ideally as the jet becomes obvious.
> Q. Do you say that it's medically unreasonable to measure AI in systole?
> A. Yes, I would.
> Q. And Dr. Vasey --
> JUDGE WALSH: I would say it's more than that, wouldn't you?
> THE WITNESS: Impossible.

> JUDGE WALSH: Not medically competent?
> THE WITNESS: Yes.
> Q. Dr. Vasey, based on your review of this study, is it medically reasonable to have diagnosed this plaintiff with moderate mitral regurgitation -- I'm sorry, with moderate aortic regurgitation?
> A. No, it definitely isn't -- no, it's not.
> Q. All right. Your Honor, at this point -- I'm sorry. Would it be medically reasonable to diagnose this plaintiff with FDA-positive aortic regurgitation?
> A. No, it would not.

The Court finds that Wyeth has established that no medically reasonable conclusion that Robles has MAR can be drawn from a review of this echocardiogram.

NN. WILLIAM ROWE

Rowe relies on an April 6, 2002 echocardiogram performed by Associates in Cardiology and a report of Dr. Roger A. Billhardt. Dr. Billhardt found that Rowe had MAR using CAS criteria -- JH/LVOT = 11%.

The April 6, 2002 echocardiogram was reviewed by three (3) experts: Dr. Chen, Dr. Millman and Dr. Billhardt. Both Drs. Millman and Chen found the study's quality to be marginal. Dr. Millman noted that because of high gain settings there was too much background noise for this echocardiogram to be judged as being conducted in a technically adequate manner so that reliable medical conclusions could be drawn from it. Dr. Millman also noted a relatively low Nyquist limit of 53 cm/sec. Dr. Chen concluded that MAR is not present, noting that:

> [t]he color Doppler gain setting was high, which exaggerates the size of any regurgitant jet. The purported AI "jet" selected is only a tiny, non-continuous jet that is trace at most. The measurements on the study were improperly done, with the JH not measured just below the valve and measured beyond the actual jet edges.

Dr. Billhardt, in his October 10, 2004 report, measured the JH as .31 cm and the LVOT as 2.56 cm or 12% based on PLAX views. Dr. Billhardt conceded that

it was possible that where high gain settings are present, aortic regurgitation in the range of 5% to 7% might appear to be 11% or 12%.

> [BY MR. MICHAEL]: Q. And you found FDA positive aortic regurgitation, right?
> A. There was mild aortic insufficiency, yes.
> Q. And the original report was 11 percent, right?
> A. Correct.
> Q. In your re-review you got 12 percent, right?
> A. Correct.
> Q. Doctor, do you agree that settings on an echocardiogram machine can affect the apparent size of a regurgitant jet?
> A. Yes.
> Q. Okay. And gain will be one of those settings?
> A. Yes.
> Q. Would you agree that the appropriate way to set gain on an echocardiogram machine is to turn -- the color Doppler gain, I'm talking about -- is to turn the gain up until speckling and background noise occurs, and then turn it down until it disappears?
> A. I think that's one way to do it, yes.
> Q. And if color Doppler gain were set too high, it could make an aortic regurgitant jet look larger than it otherwise would, is that right?
> A. That's possible, yes.
> Q. Okay. It could make a jet that would be say, five, six, or seven percent look like it's 11 or 12 percent, right?
> A. That's possible.

The Court has reviewed this echocardiogram and considered the testimony of the experts. It is convinced that Wyeth has demonstrated that this marginal quality echocardiogram cannot support a medically reasonable opinion that Rowe has MAR.

OO. DEBRA RUBIN[36]

Rubin relies on two (2) echocardiograms, one performed by Medical Associates of New York dated December 11, 2001 and reported on by Dr. Richard L. Mueller, and another dated December 26, 2002 and reported on by Dr. Jeffrey Stahl. Dr. Mueller found Rubin had MMAR and MMR though it is unclear from the report that CAS criteria was used. Dr. Stahl found that Rubin had MMR but not MAR using CAS criteria -- JH/LVOT = 8%; RJA/LAA = 30%.

Both echocardiograms were reviewed by three (3) experts: Dr. Chen, Dr. Millman and Dr. Lazar. Both Drs. Millman and Chen conclude that the echocardiogram reported on by Dr. Mueller was not conducted in a technically adequate manner such that reliable medical conclusions regarding the presence and severity of valvular regurgitation could be drawn from it. The Nyquist limit was 41 cm/sec and the gain was set too high, according to Dr. Millman. Dr. Chen concurred, finding that Nyquist limits which varied between 41 and 48 cm/sec and the gain settings made the echocardiogram reported on by Dr. Mueller technically inadequate.

All three (3) physicians conclude that MMR was not demonstrated on the echocardiogram read by Dr. Mueller. Dr. Lazar apparently did not consider the echocardiogram read by Dr. Stahl but Dr. Millman specifically rejectd any MMR claim finding the phenomenon observed was backflow upon closure. As to MAR, Dr. Lazar finds the echocardiogram read by Dr. Mueller supports a claim of MAR -- JH = .2 cm; LVOT = 1.7 cm or 11.6%. However, neither Dr. Millman nor Dr. Chen supports Dr. Lazar's claim with Dr. Millman finding trivial aortic regurgitation at 5% and Dr. Chen declining to make a measurement because of the technical difficulties in the study read by Dr. Mueller. Dr. Stahl concluded, as already noted, that the echocardiogram he read does not support a aortic regurgitation claim.

Whether the plaintiff relies solely on the echocardiogram read by Dr. Mueller or both, the Court finds that Wyeth has established that the echocardiogram read by Dr. Mueller was so technically deficient that no reliable medical conclusions could be drawn from it. The echocardiogram read by Dr. Stahl is unsupported by expert testimony and the limited testimony before the Court convinces it that Wyeth has shown that this echocardiogram does not support a MMR claim.

[36] This case was presented to the Court on a paper record only.

PP. YSOLA RUIZ

Ruiz relies on a June 1, 2002 echocardiogram performed by Capital Heart Associates, P.C. and a report by Dr. Ramin Oskoui. Dr. Oskoui found Ruiz to have MMAR presumably using CAS criteria -- JH/LVOT = 36%. No JH or LVOT measurements are given but the study quality is termed as "good."

The June 1, 2002 echocardiogram was reviewed by three (3) experts: Dr. Chen, Dr. Millman and Dr. Lazar. All three (3) physicians found the study to be technically adequate but it was noted that the color Doppler was not turned on in the PLAX view. Both Drs. Millman and Chen found either trivial or non-existent aortic regurgitation in the Apical 3 chamber view. Dr. Millman measured the JH/LVOT and found it to be JH = .05 cm and the LVOT = 2.00 cm or 3% (actually 2.5%). Dr. Chen observed that numerous errors existed in the measurement of the aortic regurgitation in Ruiz's echocardiogram. He notes that:

> [t]he purported aortic regurgitation was traced improperly in the apical view. The JH was not measured just below the valve and measured beyond the actual jet edges. In another apical view, the purported AI "jet" selected was not representative of true regurgitation.

Dr. Chen declined to measure, finding that the aortic regurgitation visualized in the apical view was not continuous and too tiny to measure.

Dr. Lazar found Ruiz has MAR based on a finding of JH = .9 cm and an LVOT of 6.00 cm or 15%. The Court rejects Dr. Lazar's conclusion out of hand. An LVOT measurement of 6 cm is not possible in a human being. The normal range, according to Dr. Chen, is 1.9 cm - 2.7 cm.

The Court finds that Wyeth has established that no reasonable medical conclusion that Ruiz has MAR can be made from review of this echocardiogram. The PLAX view is available but not colorized. The plaintiff has made no effort to explain this. Second, Dr. Lazar's LVOT measurement of 6 cm is incredible.

QQ. DONALD SCHAEFER

Schaefer relies on a May 29, 2002 echocardiogram performed by Cardiac Consultants of Chicago, Ltd. and a report by Dr. Richard Levinsky. Dr. Levinsky

found that Schaefer had MAR and MMR by CAS criteria -- JH/LVOT = 12%; RJA/LAA = 20%.

The May 29, 2002 echocardiogram was reviewed by three (3) experts: Dr. Kaul, Dr. Millman and Dr. H. Cohen. All three (3) physicians concluded that the echocardiogram was technically adequate. Both Drs. Millman and Kaul found that the echocardiogram did not support a MAR or MMR claim by Schaefer. As to the MAR claim, Dr. Kaul observed that "[n]o aortic regurgitation is seen on this echocardiogram. JH/LVOT is measured (by Dr. H. Cohen) during the wrong part of the cardiac cycle - during systole rather than during diastole." Dr. Millman concurred, saying "[t]here is no AR seen." As to the MMR claim, Dr. Kaul found no mitral regurgitation. According to him, only "closing volume" is seen Again, Dr. Millman concurred, observing that "there was no MR only a 'puff' from valve closure which is normal."

Dr. H. Cohen disagrees and finds both MAR and MMR of 12% and 20%, respectively. Although some measurements purporting to establish these claims are given, the copy provided to the Court was unreadable. The Court obtained this information from Dr. H. Cohen's testimony. In a nutshell, the four (4) frames Dr. H. Cohen claims supports his conclusion that Schaefer has MAR shows otherwise or are equivocal. The Court concludes that the claimed MAR jet viewed by Dr. H. Cohen in these four (4) frames was atypical and not holodiastolic. Further, the claim of aortic regurgitation is not supported with findings from continuous wave Doppler as claimed by Dr. H. Cohen. The MMR claim is unsupported as well. Dr. H. Cohen bases his conclusion that MMR exists on one (1) frame which was taken in early systole. But the "claimed jet" is not holosystolic and is consistent with backflow as claimed by Drs. Millman and Kaul.[37]

---

[37] The cross-examination of Dr. H. Cohen identifies the frames and also demonstrates that his opinion lacks foundation and is produced at length.

> Q. And on your 2004 review, you cited four frames of aortic regurgitation, right?
> A. Whatever is on those reports is what I cited at that time.
> Q. Okay. The first frame you cited was 1:23:32:20, is that right?
> ****
> Q. Now, Dr. Cohen, there are two blue lines in the middle of this frame that you have just presented us with, is that right?
> A. Yes.
> Q. Okay. Which of those do you contend is an aortic regurgitant jet?
> A. Well, I though that from the top of the top one to the bottom of the bottom one was the jet.
> Q. So what's the black in between?
> A. I'm sorry. Say that again?
> Q. What's the black in between the two blue lines?

A. Well, I don't know why they are separated, but that does sometimes happen when you have -- when you have jets, sometimes the jets are not full.
Q. Doctor, this doesn't look like a typical aortic regurgitant jet, does it?

****

Q. But Doctor, can you answer?
A. Yes.
Q. Go ahead.
A. On this machine, frequently, you cannot see the kind of jets that we see on the machines that we have. That machine now would be six years old or seven years old. The kind of jets --

****

A. Yes. The echocardiogram machine that was used then now is about six years old, which we don't use it anymore. And jets did not look the same on that machine that they do on the newer machines.

****

Q. Your second frame is 1:31:35:05, is that right?
A. Yes.
Q. And that's actually a frame from an apical view, is that right?
A. I have to look and see if I have that. 1:31:38.

Well, I couldn't stop on that frame. I have a frame a little later than that, and it's an apical three-chamber view which shows actually fairly severe aortic regurgitation.

****

Q. Doctor, the third frame was 1:35 -- 31:35:21 that you cited on your 2004 handwritten review, is that right?
A. If that's what's written there, then that's what's written there.
Q. And Frame 1:31:35:21 is also from an apical view, is that right?
A. Well, again, I couldn't find that frame, so -- well, actually, I didn't have my review last night.
Q. Okay. Well, we can --
A. So I will assume that it's an apical view, okay?
Q. Well, Doctor, I just want to make sure.

****

Q. Doctor, is this Frame 1:31:35:21?
A. Probably. I can't read the last digit, but it -- I'll assume it is.
Q. Okay. It's at least within one or two frames, right?
A. Well, yes, within nine.
Q. And that's an apical view, right?
A. That is an apical view.

****

Q. Doctor, this is the Frame 1:28:54:25 [the last frame] that you've referenced in your handwritten report, right?
A. Correct.
Q. Okay. And that's a CW Doppler image, right?
A. Yes.
Q. Okay. And what we're looking at is basically a velocity graph, right?
A. We're looking at velocity of flow in the direction toward and away the transducer and with a time axis, the X axis is time, showing the aortic regurgitation during the whole of diastole.
Q. Okay. So aortic regurgitation in this graph would be the peaks above the base line, is that right?
A. That's correct.
MR. MICHAEL: Okay. Have we switched --
A. During diastole, just during diastole, but it's not all of the peaks, it's just sort of window 1 across diastole.

Q. Okay. And the doctor was indicating one of the peaks on the screen.
A. Yes. It's a holodiastolic flow backwards through the aortic valve.
Q. Do you agree that aortic regurgitation is detected by Doppler echocardiography as a high velocity, turbulent diastolic flow?
A. The tighter it is, that is, the smaller the hole, the higher the velocity; the larger the hole, the lower the velocity.
Q. The velocity of aortic regurgitation though is going to be generally up in the four or five, six meters per second range, right?
A. No.
Q. Okay. The velocity of mitral regurg --
A. Well, this is -- I mean obviously, this is -- this is obvious aortic regurgitation. It's not in that range.
Q. What is the range of velocity for this aortic regurgitation --
A. Well, this is --
Q. -- if what you are saying is aortic regurgitation?
A. What I'm saying is -- well, here is aortic forward flow. And that's about one and a half meters per second. And this is maybe up to one meter per second.
Q. Okay. So --
A. One and a half maybe.
Q. Still, Doctor, one to one and a half meters per second, that's not high velocity flow, right?
A. As I said, the more -- the more open the aortic valve is, the less the velocity, so, for instance, this is a huge amount of aortic regurgitation in my hand, but the velocity is low.
Q. Doctor, I'm going to ask you not to refer to images that you pulled that are not marked as exhibits or that I'm not asking you about, okay?
A. I'm just trying to enlighten you, that's all.
MR. MICHAEL: Let's switch back to the video.
Q. Now, Doctor, in your original report that was signed by Dr. Levinsky, you found mild aortic regurgitation, right?
A. Correct.

****

Q. That's not such a huge amount of aortic regurgitation --
A. Oh, okay.
Q. -- that the velocity is going to be atypically low?
A. At that time, when we were looking at the parasternal long axis view, it did not seem to be a large amount of aortic regurgitation, and different from what I reviewed last night on the digital disk.
Q. Okay. Now, Doctor, turning to mitral regurgitation, on your 2004 handwritten review, you cite one frame of mitral regurgitation, right?
A. As I said, whatever is written there is written there.
Q. Okay. And that is Frame 1:27:13:05, right?
A. As I said, if that's written there, then I accept it.
Q. Okay. Did you make a print of that frame as well?
A. Well, I have -- and I think it's the same, 1:27:14:05 which I have a print of.

****

Q. Well, let me step back a second.
Doctor, you understand that Weyman and Feigenbaum, for these purposes, are accepted as medically authoritative, right?

****

A. Do you mean do I think that Feigenbaum is a good echocardiographer?
Q. Do you?
A. I do.
Q. And Dr. Weyman?
A. I think Feigenbaum is better.

****

Q. A page out of Weyman, Page 428.

And Doctor, do you see where Dr. Weyman says -- the cull out, please -- Mitral regurgitation characteristically produces a high velocity, turbulent, systolic flow. The high peak velocity of the jet, i.e., 5 to 6 meters per second.

A. Yes.

Q. Did I read that right?

A. Yes, you did.

Q. Do you agree with that statement by Dr. Weyman?

A. You mean characteristically?

Q. Yes, sir.

A. But not always.

Q. So you agree with that statement as written?

A. I agree that that's what this says.

Q. Do you agree with the principle --

A. No, that's not --

Q. -- that mitral regurgitation characteristically produces a high velocity, turbulent, systolic flow?

A. It's turbulent. I don't know how frequently it's five or six meters per second.

Q. Okay. So you don't know?

A. I don't know how often it's five or six meters per second. It doesn't say.

****

Doctor, do you see on Page 434, where Dr. Weyman states that regurgitant jets are almost always turbulent?

A. He says are almost turbulent, yes.

Q. Did I read that right?

A. Indeed, you did.

Q. Do you agree with that statement?

A. Yes.

MR. MICHAEL: And we can go back.

Q. On echocardiography, you can see turbulent high velocity flow, right?

A. You can tell if it's high velocity by doing the regular Doppler, and you can tell if it's turbulent by looking at the colors.

Q. Okay. And light blue flow is sometimes called laminar blue flow, right?

A. Well, the blue just tells what direction it is. And as it gets lighter toward white, the velocity is higher, so a turbulent flow away from the transducer will be blue to light blue to white.

Q. High velocity turbulent flow will alias, however, right?

A. Not always. Sometimes -- well, when you say "high velocity," the question is not that. The question -- if you're talking about mitral regurgitation, the question is how often does mitral regurgitation show colors other than blue, light blue or white, and the answer is maybe 50 percent of the time, but that's a guess.

Q. So you believe that mitral regurgitation is high velocity and turbulent enough to cause aliasing only 50 percent of the time?

A. Well, if you -- if by "aliasing" -- well, you have to tell me what you mean by "aliasing."

Q. Passing the Nyquist limit?

A. You're talking about showing up on the other side, or you're talking about changing to red-yellow? If you're talking about changing to red-yellow, not very often, not more than 50 percent in my experience.

Q. Doctor, you understand what I mean by "aliasing," is that right?

A. Well, aliasing used to mean showing up on the other side of the M mode. And now, it refers to a change in color.

Q. And Doctor, would you agree --

MR MICHAEL: And let's put up FTI 26.40 which is Defendant's Exhibit 15, Weyman, at Page 429.
Q. Doctor, Dr. Weyman says, Mitral regurgitation typically begins immediately after mitral valve closure and continues throughout most or all of systole. Did I read that right?
A. Well, I'm going to tell you, do you have these texts here, and is this out of context? And I'm not sure that it's appropriate for me to be commenting on a statement in a text that I don't have in front of me and taken out of context.
Q. Doctor --
A. So therefore, I won't.

****

[I]f I asked you, Doctor, do you agree that mitral regurgitation typically begins immediately after valve closure and continues throughout most or all of systole, do you agree or disagree?
A. I agree that it starts immediately after valve closure except in cases of mitral valve prolapse where it occurs late in systole and not early, so the answer is it doesn't always begin at the -- at the beginning of systole. And it does not always go all the way through systole. It does not always go through all the way through systole, but many time, it does. We usually refer to it as a holosystolic murmur, however, when -- in physical examination.
Q. So typically, mitral regurgitation is going to be holosystolic?
A. I would say typical, when it is typical.
Q. And do you agree that there is a phenomenon known as back flow or closing volume?
A. Well, there is -- when the mitral valve is pushed closed, it can push blood in the opposite direction, but it's at the moment that it closes.
Q. In very early systole, right?
A. In very early systole.
Q. And that's not mitral regurgitation, right?
A. It's not necessarily mitral regurgitation, but you have to look at the picture and make a decision.
Q. And that decision is based in part on how long that flash of blue lasts, right?
A. It is based on when it occurs, how long it lasts, what it looks like, what its shape is, and -- well, that would be it.
Q. Okay. Doctor --
A. All of these things.

****

Q. All right. Now, Doctor, we've been looking at this loop which contains the frames wherein you cited for moderate mitral regurgitation for Mr. Schaefer.
MR. MICHAEL: And let's play it real time.
Q. Now, Doctor, on real time, there is just a tiny flash of blue just under the mitral valve, is that right, correct?
A. Is that your diagnosis?
Q. I asked you a question, Doctor. Can you answer it?
A. Well, as I said, if you'll go frame by frame, I'll tell you how much blue there is and give you an estimate of how much space it takes up.
Q. Okay. Doctor, just looking at the loop in real time, you can't do that?
A. You mean take a guess how -- as to how much it -- how much space it takes up? Well, as you went through it fast, it looked like it took up at least 20 percent.

****

Q. And Doctor, in fact, in your report, you put down in RJA/LAA for mitral regurgitation of 20 percent, right?
A. Whatever is there is what I agreed to.

The Court concludes that Wyeth has established that Schaefer's MAR and MMR claims are not supported by this echocardiogram and that no medically reasonable conclusions to that effect can be drawn from this echocardiogram.

RR. STEVEN SIGNORE

Signore relies on an August 9, 2002 echocardiogram performed by Associates in Cardiology, Ltd. and a report of Dr. Roger A. Billhardt. Dr. Billhardt found Signore had MMAR using CAS criteria -- JH/LVOT = 40%. No actual JH or LVOT measurements were provided in the report.

The August 9, 2002 echocardiogram was reviewed by three (3) experts: Dr. Chen, Dr. Millman and Dr. Billhardt.[38] All three (3) physicians concluded that the echocardiogram was technically adequate. Both Drs. Millman and Chen found that the purported aortic jets measured to establish MMAR occurred in systole. As we have already discussed, it is impossible to have aortic regurgitation in systole and it is medically incompetent to make a diagnosis based on such measurements. Both Drs. Millman and Chen measured the aortic jets in the proper cycle. Dr. Millman measured a JH of .12 cm and an LVOT of 2.4 cm, resulting in a 5% figure. Dr. Chen measured a JH of .127 cm and an LVOT of 2.572 cm yielding 4.93%.

Dr. Billhardt found that in the PLAX view Signore's aortic regurgitation was no greater than 12% although he argued that the Apical 3 chamber view disclosed MMAR with a 40% JH/LVOT. Dr. Billhardt provided no time stamps in the PLAX views from which the conclusion could be tested. During Dr. Billhardt's

---

Q. Okay. And Doctor, as we discussed, you didn't go back and remeasure that, did you?
A. I had no way of doing that.
Q. And you had no way of looking at the original measurements to confirm those original measurements, did you?
A. That's correct.
Q. Okay. So you have no way of knowing whether or not that's 19 percent or 21 percent, right?
A. That would be correct.
Q. Okay.
A. Well, no, that's not really correct, because I do have a frame here in systole that is more than 20 percent.
Q. A frame that you did not put down in your original -- in your 2004 report, did you?
A. As I said, I didn't have the 2004 reports last night, so I just went through them, not knowing what I had said before, okay?
Q. And Doctor, I'm going to be examining you about your 2004 submission, okay?
A. You just asked me what -- never mind. Go ahead.

[38] Dr. Lazar was initially offered as an expert on this plaintiff but was withdrawn at the hearing.

cross-examination, he indicated that in the PLAX view the JH was .37 cm and the LVOT was 3.04 cm yielding a percentage of 12.17%. Dr. Billhardt conceded the JH could have been overmeasured by the inclusion of entrained blood but he did not think so. If the alleged entrained blood was eliminated, the JH/LVOT would fall below 10%.

The Court finds that Wyeth has satisfied its burden to establish that no reasonable medical conclusion that Signore has MAR can be drawn from review of this echocardiogram. The jet isolated and measured by Dr. Billhardt was, in fact, overmeasured. The differences reflected in Dr. Billhardt's reading of JH/LVOT and those of Drs. Millman and Chen cannot be accounted for on the basis of interreader variability.

SS. RON SMITH

R. Smith relies on a May 24, 2002 echocardiogram performed by Cardiac Consultants of Chicago, Ltd. and a report of Dr. Richard Levinsky. Dr. Levinsky found R. Smith had MAR and MMR using CAS criteria -- JH/LVOT = 24%; RJA/LAA = 26%.

The May 24, 2002 echocardiogram was reviewed by three (3) experts: Dr. Chen, Dr. Millman and Dr. H. Cohen. All three (3) physicians concluded that the study was technically adequate though Dr. Chen noted that the study was technically limited. Both Drs. Millman and Chen found no aortic regurgitation. Dr. Millman observed "no AR signal, only artifact!" Dr. Chen concurred, finding "[n]o aortic regurgitation ... visualized on the echocardiogram." As to the MMR claim, both Drs. Millman and Chen rejected this claim finding either trace or "at most, mild mitral regurgitation ... visualized."

Dr. Billhardt found MAR of 24% and a MMR of 24% -- just slightly less than the report from his office initially disclosed. He, however, did no new measurements but identifies the frames he used to make his determination. He listed one (1) frame supporting the aortic regurgitation measurements and four (4) frames supporting the mitral regurgitation measurements.

Dr. Chen's criticism of Dr. Billhardt's MAR claim is consistent with the Court's review of the echocardiogram and the Court adopts it as its findings.

> For aortic regurgitation, Dr. Cohen asserts a JH/LVOT ratio of 24% but does not provide specific measurement

> of LVOT or JH, and states that frame 0:26:55:05 shows aortic regurgitation in diastole. I re-reviewed the echocardiogram, particularly the frames that Dr. Cohen mentioned in his additional comment. There is no visible aortic regurgitant jet on color Doppler images in parasternal or apical views in the recorded real-time images. No aortic regurgitation was noted by spectral Doppler either. On frame 0:26:55:05 which is a frozen frame selected from slow playback cine-loop recorded on CD/video tape with real-time image recorded on frame 0:26:38:28, there is an amorphous, bright blue color strip in the vicinity of LVOT and aortic annulus which Dr. Cohen claims as aortic regurgitation. I disagree with Dr. Cohen's claim and consider the amorphous color strip not as an aortic regurgitant jet. It is likely either ghosting artifact associated with aortic valve closure or ring-down artifact from end-systolic flow, but the origin of the amorphous color strip is uncertain because its relation to the aortic valve cannot be assessed since the aortic valve is not well visualized due to poor study quality. The color strip on the frozen frame is visualized at the end of the T wave on the EKG, that is at the transitional period of endsystole and early diastole. By reviewing real-time images, I found that the color strip mimicking AR on frame 0:26:38:28 (the same as frame 0:26:55:05 on which Dr. Cohen claimed AR) appears only in that frame at the endsystole transitional period of end-systole or early diastole and there is no aortic regurgitant jet or similar color strip visualized in the remaining 4 frames of diastole. Therefore, it is not an aortic regurgitant jet and there is no aortic regurgitation present.

Dr. Chen's cogent criticism of Dr. Billhardt's MMR is also adopted by the Court as its own findings.

> For mitral regurgitation, Dr. Cohen asserts an RJA/LAA ratio of 24%, but does not provide specific measurements of RJA or LAA. Dr. Cohen states that "frame 0:28:32:20 shows mitral regurgitation by Doppler and frames 0:28:55:08, 0:28:56:02, 0:31:02:02, and

> 0:29:03:14 show moderate mitral regurgitation." I re-reviewed the echocardiogram, particularly the frames that Dr. Cohen mentioned in his additional comment. I agree that on frame 0:28:32:20, there is mitral regurgitation present on CW Doppler tracing. However, upon reviewing color Doppler images in apical views, I reaffirm that mitral regurgitation is no more than trace on color Doppler. On frame 0:28:55:08, there is a tiny mitral regurgitant jet consistent with trace mitral regurgitation. The frame 0:28:56:02 is the identical to frame 0:28:55:08. On frame 0:29:03:14, there is a mixture of back flow and likely a tiny mitral regurgitant jet at very early systole. On frame 0:31:02:02, the mitral valve is still in opening position and not closed at late diastole and thus, there is no mitral regurgitant jet. In summary, mitral regurgitation is present and is trace.

Moreover, as is seen in the cross-examination of Dr. H. Cohen, he conceded that MMR is not evidenced on any of the four (4) frames he reported.

> Q. You found 24 percent on mitral regurgitation for Mr. Smith?
> A. Let me look it up. I wrote 24 percent.
> Q. And again, those weren't your own measurements at the time of making this, right?
> A. That is correct.
>
> * * * *
>
> Q. Okay. Now, you have written down four frames concerning mitral regurgitation. I'd like to take those one at a time.
> MR. MICHAEL: The first one is Frame 28:55:08 which has been marked as Defendant's Exhibit 3267, FTI RS.3.
> MR. BERN: 3267?
> MR. MICHAEL: Yes.
> Q. And Doctor, this is Frame 28:55:08 or 09, right?
> A. or 89, I'm not sure, but yes, I think it's 09.
> Q. Okay. And Doctor, there is a blue/white area towards the mitral valve, right?
> A. Yes.
> Q. Okay. Is it fair to characterize that as tiny?

A. Well, why don't you run the --
Q. Doctor, I'm talking about the frames that were in your 2004 submission of which this is the first one.
A. Yes. That part of it is small.
MR. MICHAEL: Let's go to Frame 28:56:02, the second frame listed, Defendant's Exhibit 3268, RS. 4.
Q. Doctor, is that Frame 28:56:02?
A. That's exactly the same frame.
Q. And again, very small?
A. Well, it's the same frame.
MR. MICHAEL: Okay. Let's go to Defendant's Exhibit 3270, RS. 5, Frame 29:03:14, the third listed -- or the fourth listed frame, actually.
Q. Now, Doctor, is that Frame 29:03:14?
A. It is.
Q. Okay. And there is low velocity flow pictured there, right?
A. That's -- yes, that's low, but I don't -- I don't even think that's in systole, so I'm not sure about that frame.
Q. Okay.
A. I don't think I would use it.
Q. Let's take the last frame you listed on your 2004 submission, 31:02:02, Defendant's Exhibit 3269, and RS. 6.
Doctor, is that Frame 31:02:02?
A. It is.
Q. Okay. And there is no mitral regurgitation there, is there?
A. Well, you can't say for sure, but it's not a lot.

The Court finds that Wyeth has established that no medically reasonable conclusion can be drawn that R. Smith has MAR or MMR from review of this echocardiogram.

TT. DALVE SMITH

D. Smith relies on a June 1, 2002 echocardiogram performed by Associates in Cardiology, Ltd. and a report by Dr. Roger A. Billhardt. Dr. Billhardt found that D. Smith had SMR using CAS criteria -- RJA/LAA = 43%. No measurements of RJA or LAA were provided in the report.

The June 1, 2002 echocardiogram was reviewed by three (3) experts: Dr. Chen, Dr. Millman and Dr. Billhardt. All three (3) physicians found the study to be technically adequate. Both Drs. Millman and Billhardt believe that D. Smith has MMR based on CAS criteria. Dr. Millman notes that "[a]lthough the technician's measurements are not accurate, the degree of MR is mild to moderate and therefore >20%." Dr. Billhardt believes that the diagnosis of SMR is medically appropriate. While the Court finds that SMR has not been demonstrated, two (2) of the experts believe that D. Smith is FDA Positive with respect to her mitral regurgitation.

Dr. Chen concludes that D. Smith has mild mitral regurgitation. He claims that "[t]he two selected RJA measurements were overtraced beyond the actual jet edges. The LAA was measured at an oblique angle, not at the maximal end-systole frame." Dr. Chen measured an RJA of 3.363 cm^2 and a LAA of 19.767 cm^2 yielding a percentage of 17.01% -- i.e., mild mitral regurgitation.

The Court finds that while the plaintiff's proofs on this echocardiogram were on the skeletal side, nevertheless, the differences appear to be within the range of interreader variability.[39] The Court determines that Wyeth has not satisfied it that no medically reasonable conclusion that D. Smith has MMR could be drawn from this echocardiogram.

UU. PHYLLIS TAYLOR

Taylor relies on a June 29, 2002 echocardiogram performed by Cardiac Consultant's of Chicago, Ltd. and a report by Dr. Richard Levinsky. Dr. Levinsky found that Taylor had MAR using CAS criteria -- JH/LVOT = 13%. No measurements of JH or LVOT appear in the report.

The June 29, 2002 echocardiogram was reviewed by three (3) experts: Dr. Chen, Dr. Millman and Dr. H. Cohen. Both Drs. Millman and Chen found that the echocardiogram quality was marginal. Dr. Millman concluded that the echocardiogram was not conducted in a technically adequate manner such that reliable medical conclusions regarding the presence and severity of valvular

[39] It is evident to the Court that the technician's choice of frame in early systole and transducer angle (oblique) had the effect of significantly lowering the LAA. Compare Dr. Chen's measurement of 19.767 cm^2 with Dr. Billhardt's LAA of 11.32 cm^2. Obviously, this cannot be the result of interreader variability. If it were, modern echocardiography would be virtually useless as a diagnostic tool. Even giving this point to Wyeth, the Court believes a reasonable physician could determine that D. Smith has MMR based on this echocardiogram. According to Dr. Billhardt's testimony, the 43% resulted from 4.25 cm^2/11.32 cm^2.

regurgitation could be drawn from it. Dr. Chen believed that one could analyze the echocardiogram although "[t]he 2-D gain was set high." Both Drs. Millman and Chen concluded that there was no aortic regurgitation present on the echocardiogram.

Dr. H. Cohen reexamined the echocardiogram performed by his office on October 10, 2004. The reexamination produced the same 13% result.[40] Again, the Court found Dr. Chen's comments about Dr. H. Cohen's findings to be correct and, having reviewed the echocardiogram, adopts his conclusions as its own.

> I have reviewed the affidavit of Dr. Cohen in this case. Dr. Cohen asserts a JH/LVOT ratio of 13%, but does not specify measurements of JH or LVOT for that ratio. Dr. Cohen states that "frame 0:01:42:06 shows aortic regurgitation in early diastole" and "frame 0:04:40:06 shows aortic regurgitation." On frame 0:01:42:06, a color strip is noted in the LVOT at the transitional period of endsystole/early diastole, as the time bar is at the end of the T wave on the accompanying EKG tracing. Unfortunately, the imaging quality is so poor that the aortic valve and mitral valve opening and closure cannot be discerned in the image so that the determination of the exact time point of aortic valve closure is not possible. Therefore, it is not certain whether the color appears just before aortic valve closure, at the closure, or after aortic valve closure. I carefully reviewed all recorded real-time images of color Doppler parasternal long-axis views and found that frame 0:01:42:06 is likely selected from real-time images at 0:01:09:17 (similar frame at least). By examining frame by frame of the real-time recording, I found that the color strip appears only in that frame of the image at the transitional period of endsystole and early diastole and does not appear on the other 6 frames of the diastolic phase (if the frame is considered early diastole). Therefore, it is not an aortic regurgitant jet. There is also no aortic regurgitant jet visualized in any recorded color Doppler or spectral Doppler images. Frame 0:04:40:06 is

[40] Although on certain frames attached to his report of October 10, 2004 Dr. H. Cohen claimed to see MMR, no claim for that was made in the body of the report in Dr. H. Cohen's testimony. The Court regards this simply as a MAR case.

> a systolic frame of an apical 5-chamber view image. The frame depicts systolic LVOT flow as blue color away from the transducer and certainly not an aortic regurgitant jet.

The Court finds that Wyeth has established that no medically reasonable conclusion that Taylor has MAR can be drawn from this echocardiogram.

VV. YOLANDA WALKER

Walker relies on a June 15, 2002 echocardiogram performed by Associates in Cardiology, Ltd. and a report by Dr. Roger A. Billhardt. Dr. Billhardt found that Walker had MMAR using CAS criteria -- JH/LVOT = 42%. No measurements of JH or LVOT were contained in the report.

The June 15, 2002 echocardiogram was reviewed by three(3) experts: Dr. Kaul, Dr. Millman and Dr. Billhardt. All three (3) physicians concluded that the study was technically adequate. Both Drs. Millman and Kaul found trace aortic regurgitation. Dr. Millman measured a JH of .1 cm and a LVOT of 2.26 cm which is 4.4% when reflected as a percentage. Dr. Kaul found a JH/LVOT of 4%.

Dr. Billhardt claimed that JH/LVOT was 26% when measured in the PLAX view, which was available. In the one (1) frame he discussed, Dr. Billhardt claimed to measure a JH of .54 cm and an LVOT of 2.06 cm. But he also claimed that in the Apical 4 chamber view (an unapproved view) MMAR of 42% was observed. What is clear from the cross-examination are two (2) facts. First, Dr. Billhardt did not know that aortic regurgitation was to be measured in the PLAX view where available. The Court finds it was available here. Second, the JH and LVOT measurements were not taken in close proximity to the annulus, which is a requirement in both the Feigenbaum Text at 283 and the Weyman Text at 534.

As Dr. Kaul pointed out in his testimony, Dr. Billhardt's measurements inflate the JH and deflate the LVOT. The Court accepts Dr. Kaul's criticism and finds Dr. Billhardt's measurement is not medically reasonable.[41] Accordingly, the

---

[41] Dr. Kaul's testimony on this point is set out in full in this footnote.

> MS. PETERSEN: Last one, your Honor, Yolanda Walker.
> Q. And this is an aortic regurgitation case?
> A. Yes
> Q. And what was your opinion, Dr. Kaul, as to whether and to what degree there's aortic regurgitation seen on this echocardiogram?

* * * *

A. 4 percent, and Dr. Millman's was 5 percent.
Q. And did you also review Dr. Billhardt's report or Affidavit?
A. Yes, he calls it 26 percent.
Q. Right. And under Number 10, he uses a jet height over LVOT of .54/2.06; is that correct?
A. Yes.
Q. Let's look at that frame, which is YW.2, Defense Exhibit 3392. First, Dr. Kaul, could you tell me what, if any, criticisms you have of the measurement of the left ventricular outflow tract on this frame?
A. Yes. First of all, this measurement is not really made at the level of the aortic valve where the jet should arise. In fact, I don't see a jet here anywhere coming out.
JUDGE WALSH: You'd have to measure if they're not there.
THE WITNESS: I don't see, but I see a color here they have tried to measure, this color, which they are measuring really in the left ventricle cavity. This is where the mitral valve is now, and this is the ventricular septum. So, this is the about a centimeter distal to the outflow tract. And even the measurement include some black spots. You can see this is one measurement and the other side is black. So, they are really going way out overboard there, and then they are measuring the left ventricle where, if you can call it outflow tract, is very narrow compared to the actual outflow tract. So, they are going to a part where the outflow tract is narrow, and they are measuring something rather largest that's not even a jet, and so they're coming up with 26 percent.
Q. And, Dr. Kaul --
JUDGE WALSH: Where should the LVOT be measured here, Doctor, if you can --
THE WITNESS: I will show you. Can we see --
A. I'm sorry. We are not going according to your --
Q. That's fine. We can skip ahead.
MS. PETERSEN: Dr. Kaul chose a different frame. Let me find it. I believe it's YW.4.
A. As you can see, here is the aortic valve and here is where the jet is coming out. It's a tiny jet, and it's not really even aliasing. We almost call it closing volume. And the rest of this you can see, it's just blood in the cavity. This is where they measured it. Although it's not the exactly the same frame. This is where they measured it. If they had to measure, they should have measured it here, and this is the aorta. It's so much bigger than making the measurements here where they made it. In fact --
JUDGE WALSH: The outflow tract you say is to the right?
THE WITNESS: This is the outflow tract.
JUDGE WALSH: All right.
THE WITNESS: But they made the measurement here. Can we show them together?
MS. PETERSEN: Sure. Can you put right next to that YW.5, which is Defense Exhibit 3402? And I believe this is a the frame without the measurements on it that they rely on.
A. Yes. So basically if a measurement had to be made, it should have been made here. This is the aorta. This is the outflow tract. They end up making the measurements here. If you recall, this is their thing.
JUDGE WALSH: Right.
A. And so, you can see the outflow tract, this is the anterior mitral leaflet they are measuring from, which is opening. So, they have very narrow outflow tract instead of the real outflow tract. And then they're measuring something that's not even the jet really, not even the distal part. It could be the distal part of the

Court finds that Wyeth has satisfied its burden that no medically reasonable conclusion that Walker has MAR can be drawn from this echocardiogram.

WW. GLENANN YAHNKE

Yahnke relies on a May 23, 2002 echocardiogram performed by the University of Wisconsin Hospital and Clinics, Adult Echocardiography Laboratory and report by Dr. Peter S. Rahko. Dr. Rahko found Yahnke had MAR using CAS criteria -- JH/LVOT = 21.4%.

The May 23, 2002 echocardiogram was reviewed by three (3) experts: Dr. Kaul, Dr. Millman and Dr. Rahko. All three (3) physicians agree that the study was technically adequate. Both Drs. Millman and Kaul found the Yahnke had trace aortic regurgitation. Dr. Millman calculated a 5% figure based on his JH and LVOT findings. Dr. Kaul calculated an 8.57% figure based on his JH and LVOT findings. Both these experts were able to make these measurements in PLAX views.

Dr. Rahko remeasured his aortic regurgitation figures and opined that Yahnke had MAR based on a JH of .39 cm and an LVOT of 2.27% cm. Dr. Rahko filed a Echocardiogram Review and Assessment report dated October 13, 2004 which found that the PLAX view was available and it did not show MAR. Instead, Dr. Rahko used the Apical 3 chamber view (long-axis) and developed a MAR of 17% based on the measurements taken in this apical view. Dr. Rahko explained his reasons for doing so in his testimony.

> Q. All right. Would you then tell us what your re-review, which was submitted to the Court as part of our submission, found, Doctor?
> A. Yes. And that was also on October 13, 2004. Looking at the first page again, the answer to the first one was yes. And then the answer to the next one was no because I, again, did not find any evidence of mitral valve insufficiency. Then if you go to the aortic valve insufficiency, again, I answered yes on number 6 and number 7. The report measurement from the apical long axis view, re-measuring that, I got a ratio of 3.9 divided

jet, but I doubt it because it's not aliasing. So, all said and done, this is an incorrect measurement. And I think that both Dr. Millman and I probably made it here in which comes to be 5 percent.

by 22.7, or 17 percent still consistent with my original report of mild aortic valve insufficiency. The question was raised by the auditor about the use of the apical long axis view. I did not feel that the technical quality of the color flow from the parasternal long axis view was adequate, and that the apical long axis view better showed the information. So, that's why the report is from using the information from the apical long axis view.

Q. And, Doctor, the conclusions that you've made with respect to both, the Larson and the Yahnke echocardiograms, are those to a reasonable degree of medical certainty?

A. Yes, I feel I applied the same criteria as best I could, and that those are my conclusions.

JUDGE WALSH: Doctor, when you say the "parasternal long axis view," you didn't use it. Tell me again why you didn't use the parasternal long axis view.

THE WITNESS: Well, the view is there, but the technical quality is less, and the color flow jet is much better seen in the apical long axis view. And so we didn't really even attempt to measure the parasternal long axis view because it was -- there was nothing there to really measure.

JUDGE WALSH: Well, you know, the settlement criteria requires you to use the parasternal long axis view where it's available. Are you telling me that the view wasn't available from a medical standpoint?

THE WITNESS: Well, my interpretation of what I thought this criteria was, is that I -- if the view wasn't technically satisfactory, I'd go to the apical long axis view.

JUDGE WALSH: Well, tell me again why the view from the parasternal long axis view was not technically satisfactory.

THE WITNESS: Because it doesn't show the jet adequately. And the jet's better shown in the apical long axis view. Remember, an echocardiogram is showing a three-dimensional phenomena two dimensions at a time. And it's common to see a jet or a flow phenomenon

> better in one view than it is in the other view. And so that's how we read echocardiograms. We use multiple views to do it, and we take what's usually -- we feel is the most representative view and usually the largest jet and use that to draw a conclusion about severity of insufficiency.

However, despite this testimony. Dr. Rahko noted that the quality of the echocardiogram was technically adequate to assess not only the presence but the severity of the valvular regurgitation here. It is important to note that this is not just a quibble. Virtually all of the plaintiffs' experts conceded that the apical long axis view causes the aortic regurgitation jets to be larger than in the PLAX views. This was emphasized in this case by Dr. Kaul.[42]

---

[42] Dr. Kaul's testimony in this regard is reproduced in the footnote.

> Q. And he agreed with you that FDA positive aortic regurgitation --
> A. Is not present in this view, that's right.
> Q. Okay. Now, do you have --
> MR. BERN: I'm going to object to that. He did not agree.
> JUDGE WALSH: I don't remember him agreeing. He may have, but let's find out what -- Ms. Petersen usually has got her ducks in a row, so let's find out if that's the case.
> MS. PETERSEN: On Question 7 of Dr. Rahko's report, the question of, "Does the parasternal long axis view show FDA positive aortic regurgitation by color flow Doppler?" Dr. Rahko crossed out the box that says "no." So --
> JUDGE WALSH: Doesn't that kind of --
> MR. BERN: I didn't think that was the question. I thought the question was whether or not he found FDA positive regurgitation.
> As you recall, he said he couldn't get it in the parasternal long, but that he did get it in the apical view.
> JUDGE WALSH: I remember, but I think what he said is -- I think he said it was better visualized, as far as he was concerned.
> THE WITNESS: It's always better visualized because it's larger.
> Q. The parasternal view?
> A. No, the long axis.
> JUDGE WALSH: In the apical long axis view.
> MS. PETERSEN: I think my question was limited to the --
> JUDGE WALSH: The reason for that, the angle of the transducer.
> THE WITNESS: And the lateral resolution.
> JUDGE WALSH: Yes, and the fact that it's more parallel as opposed to perpendicular.
> THE WITNESS: Yes.
> Q. Well, on that issue, Dr. Kaul, could you explain to the Court some of the problems with quantifying aortic regurgitations in the apical view, if any?
> THE WITNESS: Can I use that?
> JUDGE WALSH: Certainly, that's why we have it.
> THE WITNESS: Does it have a pen?

While the Court finds Dr. Rahko to be a credible witness with impressive credentials, based on all of the evidence the Court finds he was not privileged to do his calculations and make his conclusions based on the apical long axis view. The Court finds that Wyeth has established that no medically reasonable conclusion could be drawn that Yahnke has MAR based on the PLAX views available in this echocardiogram.

IV

For the reasons set forth in this Letter Opinion, the following dispositions on Wyeth's eligibility challenges are made.

JUDGE WALSH: Yes, we have all these pens for you, Doctor. You can use any color you want, and you can even have an aliased situation. We have enough pens for that.

A. Let's look at it very simply. Resolution of a technique is basically the ability for it to separate two points, separate it in space. That is the resolution of the technique.

So, let's say there are two points separated in space like this. So, the resolution of the technique has to be subtler than this. For example, if this is just a millimeter away, but we have a ruler that can only measure centimeters and not millimeters, then we cannot resolve it.

Now, the when ultrasound goes down a certain line. It is using -- it's going this way. So, it's using the resolution of its wavelength and because this is millions of times per second, the wavelength is very small. So, you can resolve very -- things that are really close apart, some millimeters.

Now, when you're going down in a sector, though, and instead of these two separated like this, you have them separated like this, this doesn't help you. The x-ray resolution doesn't help you. So, what is going to help you is how far the lines are from each other. Close up here, the lines are pretty dense, but the further they go, they spread and go further and further apart almost up to, in some cases almost half a centimeter down to the bottom.

And so the resolution becomes very poor. I think it has to be half a centimeter apart for it to be able to tell that it's two separate things.

JUDGE WALSH: I remember reading that in Weyman.

THE WITNESS: So, this is the problem. And so anything that you want to measure in this way will always look larger. And so you can make a larger measurement. And so that is the problem by looking at apical views. And that's why we don't want to measure in the apical views.

Q. So, on Ms. Yahnke's echocardiogram, would any medically reasonable cardiologist conclude that greater than or FDA positive aortic regurgitation is seen in the parasternal long axis view?

A. No.

	Plaintiff	Docket No.	Disposition[43]
1	Andrade, Janna	L-1502-04	Denied
2	Ariaz, Patricia	L-2329-04	Granted
3	Aronspeer, Terrell	L-2318-04	Granted
4	Bailey-Swager, Terry	L-1381-04	Granted
5	Barassi, Regina	L-2390-04	Granted
6	Barron, Kathy	L-2306-04	Granted
7	Bell, Sherri	L-1402-04	Granted
8	Benson, Karen	L-2398-04	Granted
9	Blanchard, Alfred	L-2417-04	Granted
10	Block, Leandra	L-2419-04	Granted
11	Boer, Herb	L-2425-04	Granted
12	Bordieri, Margaret	L-2430-04	Granted
13	Braun, Mary	L-2399-04	Granted
14	Burek, Susan	L-1498-04	Granted
15	Burgess-Bryant, Terri	L-1499-04	Granted
16	Burks, Troy	L-1489-04	Granted
17	Burns, Ulysses	L-1393-04	Granted
18	Butcher, Cathy	L-2429-04	Granted
19	Cantwell, Denton	L-2434-04	Denied
20	Chadwell, Raven	L-2415-04	Granted
21	Collinsworth, Dolores	L-2459-04	Granted
22	Colston, L.V.	L-1523-04	Denied
23	Corvey, Diane	L-0964-04	Granted
24	DeRosa, Marina	L-1517-04	Granted
25	Dingillo, Vincent	L-1370-04	Granted
26	Estremera-Brett, Alexis	L-1524-04	Granted
27	Gildersleeve, Robert	L-1376-04	Granted
28	Gordon, Robert	L-1526-04	Granted
29	Greene, Cheryl	L-1395-04	Denied
30	Hardnett, Yvonne	L-0970-04	Granted
31	Jekel, Dorothy	L-1401-04	Granted
32	Larson, Sarah	L-1433-04	Denied
33	Padratzik, Beverly	L-1448-04	Granted
34	Read, Cynthia	L-1458-04	Granted

[43] The plaintiffs for whom the disposition noted is "granted," will have their Complaints dismissed with prejudice and will be returned to the Class.

35	Reynolds, Angela	L-1455-04	Granted
36	Rickman, Lynette	L-1413-04	Granted
37	Ringo, Joyce	L-1412-04	Granted
38	Roach, William	L-1098-04	Granted
39	Robles, Lupe	L-5949-03	Granted
40	Rowe, William	L-1410-04	Granted
41	Rubin, Debra	L-0368-04	Granted
42	Ruiz, Ysola	L-0967-04	Granted
43	Schaefer, Donald	L-1464-04	Granted
44	Signore, Steven	L-1454-04	Granted
45	Smith, Ron	L-1438-04	Granted
46	Smith, Dalve	L-1519-04	Denied
47	Taylor, Phyliss	L-1462-04	Granted
48	Walker, Yolanda	L-1383-04	Granted
49	Yahnke, Glenann	L-1478-04	Granted

An Order reflecting these dispositions is enclosed with this Letter Opinion.

Very truly yours,

Charles J. Walsh, J.S.C.

CJW/len
Encl.